

ORIGINAL**Resin splint as a new conservative treatment for ingrown toenails**

Kazuya Matsumoto¹, Ichiro Hashimoto², Hideki Nakanishi², Yoshiaki Kubo³,
Kazutoshi Murao³, and Seiji Arase³

¹Section of Plastic and Reconstructive Surgery, Kitajima Taoka Hospital ; ²Department of Plastic and Reconstructive Surgery, and ³Department of Dermatology, Institute of Health Biosciences, the University of Tokushima Graduate School, Tokushima, Japan

Abstract : Several conservative as well as surgical methods are used for the treatment of ingrown toenails until date. The conservative methods are either based on nail splinting or on onychoxia, but no methods employing both principles have been reported thus far. Moreover, surgical methods usually involve postoperative pain, prolonged wound healing and restricted activities of daily living. Therefore, considering the need of a simplified, non-invasive method, in this study, we applied a novel splint to treat patients with ingrown toenails and estimated the clinical efficacy as well as rate of recurrence following treatment. The splint is a plate made of resin that is attached to the lateral edge of the nail using a bandage. We studied 61 patients (19 men and 42 women ; mean age 36 years), with an average application duration of 9.3 months and an average follow-up period of 10 months in all patients. All patients experienced pain relief within a week of splint application and a decrease in the degree of nail deformity. Moreover, follow-up revealed a recurrence rate of 8.2%. Therefore, we believe that this new device is an excellent conservative treatment method for patients with ingrown toenails. *J. Med. Invest.* 57 : 321-325, August, 2010

Keywords : *Brace, ingrown nail, nail deformity, onychoxia, splint*

INTRODUCTION

An ingrown toenail is one of the most common conditions encountered in the outpatient clinic and it frequently affects adolescents and young adults (1, 2). This condition, which is often considered trivial and inconsequential, may lead to considerable discomfort, pain and inconvenience, and restricts

activity (1). Conservative and surgical methods are available for treating this condition. Surgical treatments, however, risk postoperative pain and necessitate postoperative rest and wound dressing, thereby hindering activities of daily living, often against the patient's preoperative wishes. Consequently, a simplified conservative method was developed (1). A fine polyethylene tube with a slit was used as a gutter to protect the lateral nail groove from the trauma caused by the irregular or ingrowing lateral nail edge. Subsequently, several conservative nail-splinting techniques came to be developed based on the gutter treatment principle (2-4). Another conservative method (brace treatment) in which the

Received for publication June 10, 2010 ; accepted July 29, 2010.

Address correspondence and reprint requests to Kazuya Matsumoto, Section of Plastic and Reconstructive Surgery, Kitajima Taoka Hospital, 30-1 Aza-Kawakubo, Taihama, Kitajima-cho, Itano-gun, Tokushima 771-0204, Japan and Fax : +81-88-698-9988.

shape of the over-curved nail is corrected using dynamic orthonyxia techniques was also developed (5-7). However, thus far, no method has employed the principles of both nail splinting and orthonyxia.

Therefore, we have developed a novel treatment method in which a unique resin plate acts as a brace as well as a splint to patients' ingrown toenails.

MATERIALS AND METHODS

We performed a retrospective study of 61 patients with ingrown toenails [19 men and 42 women ; mean age 36 years (range 9-69 years)]. All patients complained of pain in the affected toe. Patients in whom the soft tissue had grown around the nail were excluded from the study.

We used a novel splint, which was made of resin (Pediglass Corp. ; Osaka, Japan) and was folded back to 2 mm width at one end (Fig. 1). After cleaning the nail and the adjacent tissue with an anti-septic, the distal section of the lateral edge of the nail was hooked using the tip of the folded part of the splint and a bandage was attached only to the lateral edge of the nail. The splint was then tilted by applying adequate force so as to correct the curvature of the affected nail and fixed in this position using a quick-drying adhesive.

The superfluous part of the splint, including the





Figure 1. The new resin splint for the treatment of ingrown nails.

thick handle section, was removed using nippers and a grinder (Fig. 2), and the entire surface of the

a



b



c

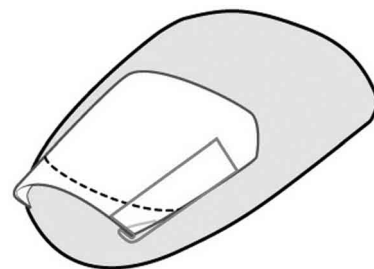


Figure 2. Resin plate attached to the nail edge. The superfluous part of the splint, including the thick handle section, was removed using nippers (a) and a grinder (b). After grinding, a part of the plate remains adhered to the nail (c).

nail, including the splint, was covered with a sheet of glass fibre and adhesive gel (Fig. 3). During treatment, daily activities of living were unrestricted and the patients were instructed to use a nail file instead of a nail clipper for nail care. The splint was replaced every 6 weeks. The average duration of splint placement was 9.3 months (range 3-33 months) and the average follow-up was 10.0 months (range 3-65 months).

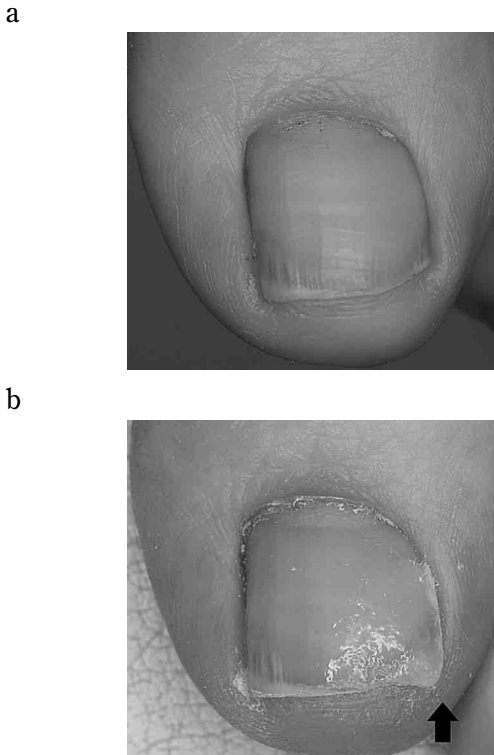


Figure 3. The left hallux of a 36-year-old female patient shown before (a) and after (b) application of the splint, a sheet of glass fibre, and adhesive gel. The splint was fixed to the lateral side of the left half of the nail (arrow).

The degree of nail deformity was estimated by referring to our classification table (Table 1). A nail with no curvature was classified as 0° whereas a cylindrical nail was classified as 100°. Nails with a curvature between these extreme values were classified in the range of 10° -90°.

All patients were evaluated for the degree of nail curvature and pain intensity at 1 week after splint fixation and at > 3 months after the completion of treatment.

Table 1. The classification table used to estimate the degree of nail deformity.

Degree of deformity	Reference shapes
0	—
10	—
20)
30)
40))
50)))
60))))
70)))))
80))))))
90)))))))
100))))))))

RESULTS

All patients reported pain relief at the 1-week follow-up. In cases where incorrect trimming of the toenail had caused pain, application of our splint relieved pain immediately and enabled the nail to grow over the lateral nail fold (Fig. 4). The average

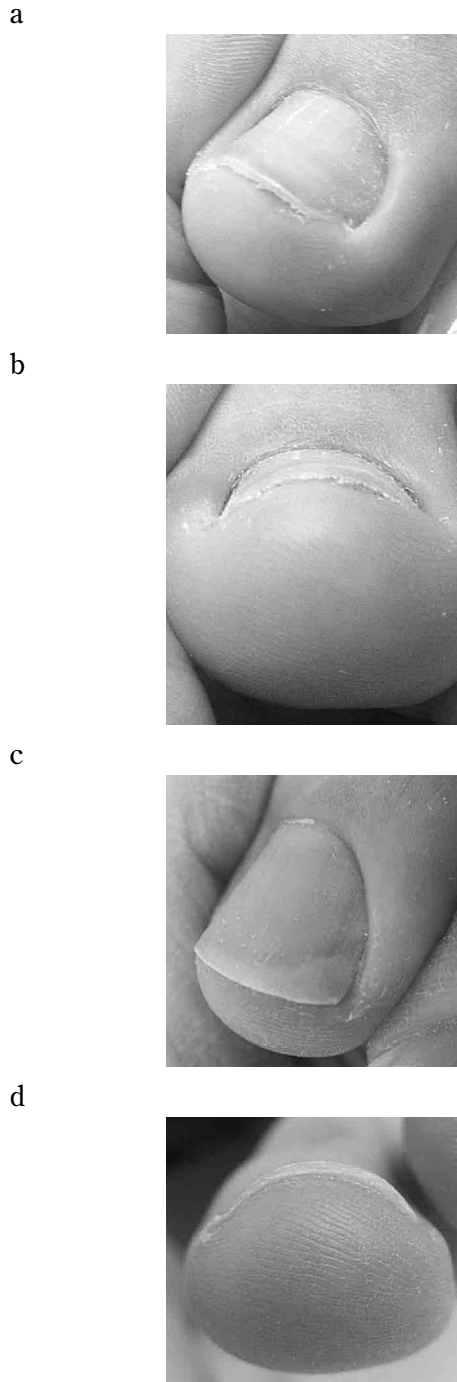
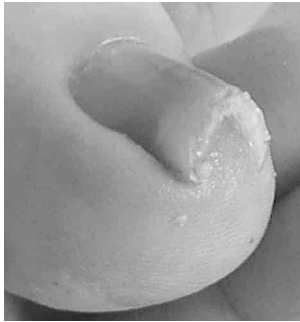

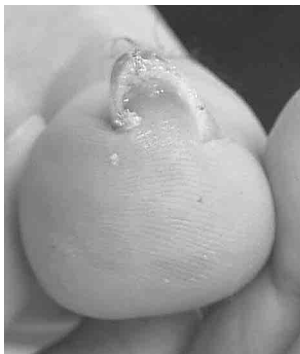Figure 4. The left hallux of a 19-year-old female patient. The lateral corner of the nail that was cut too short exerted substantial pressure on the nail wall and this caused pain (a and b). After a 10-month treatment period, the degree of nail deformity was reduced to 30° from 40° and the pressure was distributed along the lateral edge of the nail. During a 5-year follow-up period, there was no recurrence (c and d).

nail curvature was 55.4° and 34.4° at the initiation and termination of treatment, respectively. In patients with a severe degree of nail curvature, long-term application was required (Fig. 5). Of the 61 patients, only 5 reported recurrence.


a



b



c



d

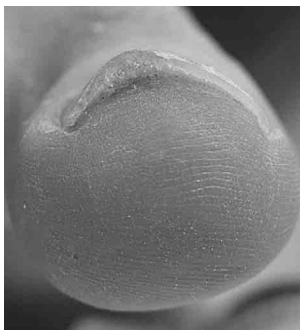

Figure 5. The right hallux of a 56-year-old female patient shown before (a and b) and after (c and d) a 3-month conservative treatment using the resin splint. The degree of nail deformity was reduced to 30° from 60° .

DISCUSSION

Many possible causes of ingrown toenails have been proposed (8); nonetheless, there seems to be a general consensus that increased pressure between the lateral border of the nail and the nail wall causes pain and promotes development of paronychia (5). All therapeutic measures used for ingrown nails aim to relieve this pressure. These techniques can be classified as surgical or conservative. Although many surgical approaches such as classic wedge excision and partial matrix phenolization have evolved, these surgical modalities have many disadvantages, such as prolonged wound healing and restriction of activities of daily living, scarring and deformation (1). Moreover, surgical treatments for ingrown toenails are thought to be extremely aggressive and unnecessary because they involve destruction of the nail matrix and consequent nail disfigurement (4). Thus, several authors prefer conservative methods to invasive surgical ones (1-5).

These noninvasive conservative treatment methods can be divided into two groups. The first group includes techniques based on nail splinting. The gutter treatment is a representative of this group (1). Although various types of materials have been used as the gutter in studies of nail-splinting techniques, the basic principle remains the same. Nail splinting separates the nail plate from the soft tissue so as to provide a channel for the nail to grow (3). Arai et al. used a vinyl intravenous drip infusion tube as the gutter splint. Simultaneously, they also used a sculptured nail (acrylic artificial nail) on an ingrown nail with nail loss and no granulation tissue as a prostheses and suitable fixation for gutter splints. They attributed the efficacy of the splints and sculptured nails to their protection of the surrounding soft tissue against distal penetrating spicules and lateral serrated nail edges (4).

The second group includes methods based on orthonyxia that employs direct force to correct the deformity of an over-curved nail plate. This principle is dynamic in contrast with the splint technique, which is based on a static principle. Harrer et al. successfully used a new orthonyxia device in patients with ingrown toenails (2). Two metal hooks on bilateral sides of the nail plate are fixed in place under tension by twisting a connecting wire between the hooks. The edges of the nail are lifted from the nail fold and the pressure exerted on the inflamed soft tissue is released immediately. A modified device in which a dental string is used instead of the

connecting wire in the original device has also been reported (6). Moreover, a super-elastic wire has also been used as a source of dynamic restoration force (7). Two holes are made at the distal free edge of the nail plate in the white portion. The wire is inserted into these holes and then cut with clippers so that it does not protrude from the nail. The above-mentioned dynamic treatments can improve the shape of the nail itself as well as release the pressure on the nail fold; this improvement of nail shape may result from continuous long-term tension on the nail plate.

Our method using the resin plate is based on the principle of nail splinting. The plate is integrated with the nail and functions as a sculptured nail. Simultaneously, direct force decreasing the degree of nail curvature is exerted upon the nail plate. This is the first procedure that uses the splinting and dynamic orthonyxia techniques together.

With regard to recurrence rates, considerable variation is observed among conservative treatments. In nail-splinting studies, the rate was 8.7% with the flexible plastic tube (3), 13.3% with the vinyl tube and the acrylic artificial nail (4) and 44-48% with the fine polyethylene tube (1). In the dynamic orthonyxia studies, the recurrence rate was 19% in the procedures using the hooks and wire (5) and 28.6% with the hooks and the dental string (6). In the present study, pain recurred in 5 of 61 patients (8.2%). We recommended the patients to continue with the splinting till the curvature of the deformed nail was reduced to less than 30° and most patients accepted this recommendation. This resulted in a lower recurrence rate than for other reported methods. We excluded patients with granulation tissue formation because the exudate from the granulation tissue hindered adhesion between the splint and the nail plate. We cannot deny the possibility that this selective exclusion may have led to the exclusion of critical cases and could thus be responsible for our good results.

However, the use of our method provides early relief from pain and the procedure itself is painless. It is also superior with respect to aesthetics because the resin device becomes almost pellucid and invisible after the procedures. In our opinion, it is an excellent procedure because of its clinical efficiency and the low recurrence rate. This procedure is indicated in patients with ingrown toenails

without granulation formation, especially in those who had cut their toenails too short during nail trimming. However, the intensity of the restoration force is weaker in our methods than in the other dynamic orthonyxia treatments. This may prolong the application period. We hope that increasing the elasticity of the resin plate may increase its ability to correct the defect, and consequently, shorten the application period of the device.

ACKNOWLEDGEMENTS

Financial support : NONE, Conflict of Interest : NONE.

REFERENCES

1. Wallace WA, Milne DD, Andrew T : Gutter treatment for ingrowing toenails. *Br Med J* 21 : 168-71, 1979
2. Nazari S : A simple and practical method in treatment of ingrown nails : splinting by flexible tube. *J Eur Acad Dermatol Venereol* 20 : 1302-6, 2006
3. Kim YJ, Ko JH, Choi KC, Lee CG, Lim KJ : Nail-splinting technique for ingrown nails : the therapeutic effects and the proper removal time of the splint. *Dermatol Surg* 29 : 745-8, 2003
4. Arai H, Arai T, Nakajima H, Haneke E : Formable acrylic treatment for ingrowing nail with gutter splint and sculptured nail. *Int J Dermatol* 43 : 759-65, 2004
5. Harrer J, Schöffl V, Hohenberger W, Schneider I : Treatment of ingrown toenails using a new conservative method. A prospective study comparing brace treatment with Emmert's procedure. *J Am Podiatr Med Assoc* 95 : 542-9, 2005
6. Erdogan FG, Erdogan G : Long-term results of nail brace application in diabetic patients with ingrown nails. *Dermatol Surg* 34 : 84-87, 2008
7. Moriue T, Yoneda K, Moriue J, Matsuoka Y, Nakai K, Yokoi I, Nibu N, Miyamoto I, Kubota Y : A simple therapeutic strategy with super elastic wire for ingrown toenails. *Dermatol Surg* 34 : 1729-32, 2008
8. Scher RK : Toenail disorders. *Clin Dermatol* 1 : 114-24, 1983