

ORIGINAL**Twenty five-gauge sutureless vitrectomy versus 20-gauge vitrectomy in epiretinal membrane surgery**

Khulood Mohammed Sayed^{1,2}, Takeshi Naito², Mahmoud Mohamed Farouk^{1,2},
Toshihiko Nagasawa², Takashi Katome², Ismail Mousa Abd El-Latif¹,
Ahmad Mostafa Abdallah¹, Usama Ali Mohamed¹, and Yoshinori Mitamura²

¹Department of Ophthalmology, Sohag Faculty of Medicine, Sohag University, Sohag, Egypt ; and

²Department of Ophthalmology, Institute of Health Biosciences, the University of Tokushima Graduate School, Tokushima, Japan

Abstract : Purpose : To compare visual outcomes, intraoperative and postoperative complications of 25-gauge transconjunctival sutureless vitrectomy (25-G TSV) versus conventional 20-gauge vitrectomy in epiretinal membrane (ERM) surgery. **Methods :** A retrospective comparative study was conducted on 200 eyes with idiopathic ERM who underwent either primary 20-gauge vitrectomy ($n=95$) or 25-G TSV ($n=105$) with 6 months follow up. The following parameters were collected and compared : age, gender, best corrected visual acuity (BCVA), intraocular pressure (IOP), postoperative anterior chamber inflammation, intraoperative and postoperative complications. **Results :** Twenty-five gauge group achieved a significantly better vision at the 1st postoperative month ($p=0.008$) and a significantly higher incidence of visual improvement 6 months postoperatively ($p=0.04$) than 20-gauge group. Intraocular pressure was significantly higher at the 1st, 3rd and 6th postoperative months compared with baseline in the 20-G group. However, in the 25-gauge group IOP remained near to the baseline at the same period. Twenty five-gauge group achieved a significantly lower anterior chamber inflammation and a lower incidence of postoperative cystoid macular edema (CME) ($p=0.01$), hyphema ($p=0.000$) and after cataract ($p=0.000$) than 20-gauge group. **Conclusions :** The 25-gauge sutureless vitrectomy achieves rapid and higher visual improvement, less postoperative inflammation and complications than the 20-gauge vitrectomy in ERM surgery. *J. Med. Invest.* 59 : 69-78, February, 2012

Keywords : 20-gauge vitrectomy, 25-gauge transconjunctival sutureless vitrectomy, epiretinal membrane, microcannulas

INTRODUCTION

Fujii *et al.* introduced a 25-gauge vitrectomy

Received for publication August 24, 2011 ; accepted October 12, 2011.

Address correspondence and reprint requests to Takeshi Naito, MD, PhD, Department of Ophthalmology, Institute of Health Biosciences, the University of Tokushima Graduate School, Kuramoto-cho, 3 chome, Tokushima 770-8503, Japan and Fax : +81-88-631-4848.

system with sutureless self-sealing sclerotomies (1) and found it to be a safe surgical procedure in a variety of vitreoretinal pathologies (2). Theoretically, the major advantages of sutureless vitrectomy include less traumatic conjunctival and scleral manipulation, less retinal phototoxicity and less postoperative corneal astigmatism (3). The microcannulas of the system permit interchangeability of instruments between entry sites and might protect the vitreous

base from mechanical traction (4).

However, evaluation of the true efficacy of 25-gauge vitrectomy requires that the visual outcome after 20-gauge and 25-gauge vitrectomy to be compared (5). Although a comparative study between the 20 and 25-gauge vitrectomy in epiretinal membrane (ERM) surgery was made twice before (5, 6); yet, these studies were performed on a very limited number of eyes and did not include a detailed analysis of intraoperative and postoperative complications occurred in both groups. The aim of this study was to evaluate the differences in the efficacy of 25-gauge transconjunctival sutureless vitrectomy (25-G TSV) in patients with ERM compared to the 20-gauge system in a large number of series (200 eyes) with longitudinal follow-up of these patients to determine the impact of each system on [1] Early and late visual outcomes; [2] Intra-operative and post-operative complications.

PATIENTS AND METHODS

Study Design

Ethics Committee approval was obtained, then a retrospective consecutive comparative case series study was conducted on all patients underwent vitrectomy for ERM surgery. Patients were recruited from the vitreoretinal clinics at the Department of Ophthalmology, Tokushima University Hospital, Tokushima, Japan.

Patients

The study was conducted on 200 eyes of 192 consecutive patients with idiopathic ERM who underwent either primary 20-gauge vitrectomy (group 1; $n=95$) from 2003 to 2006 or 25-G TSV (group 2; $n=105$) from 2006 to 2009 with at least 6 months follow up. Informed consent was obtained from all patients and the study was conducted in accordance to the tenets of the Declaration of Helsinki of Human studies. Inclusion criteria were: patients with idiopathic ERM, underwent primary vitrectomy with at least 6 months follow up. Eyes with prior vitreous surgery, glaucoma filtration surgery or patients with inadequate follow up were excluded.

Patients' medical records for both groups were reviewed and the following parameters were collected and compared: age, gender, BCVA (at baseline and 1, 3, 6 months postoperatively), IOP (at baseline and on the 1st, 5th day, 1, 3, 6 months postoperatively using Goldmann applanation tonometer).

Mean IOP of 3 successive measurements was taken. The degree of postoperative anterior chamber (AC) inflammation was also collected; it was graded qualitatively by slit-lamp examination (anterior chamber cell count, presence or absence of flare and/or fibrin formation). Lens status, vitreous fill, intraoperative suture use, intraoperative and postoperative complications were also collected. Preoperative and postoperative CME was evaluated either with slit-lamp biomicroscope or using optical coherence tomography (OCT).

Surgical Technique

All patients underwent a standardized surgical procedure for vitrectomy either 20 or 25-G PPV combined or not with phacoemulsification and aspiration (PEA) and intraocular lens (IOL) implantation (acrylic foldable IOL) under retrobulbar anesthesia by 3 surgeons. In our hospital, vitrectomy operations are combined with PEA and IOL implantation in all patients over 50 years and the conventional 20-G PPV procedures were converted to 25-G TSV by the middle of 2006.

In both groups, a core vitrectomy and vitrectomy around sclerotomy sites were done. Approximately 0.1 ml intravitreal injection of triamcinolone acetonide (TA) suspension was done. The posterior hyaloid membrane was detached at the optic disc by aspiration using a vitrectomy probe in eyes with no preoperative posterior vitreous detachment (PVD). The epiretinal membrane was removed, with or without internal limiting membrane (ILM) peeling according to the surgeon preference. All vitrectomies were performed with careful 360° scleral depression to shave the anterior as well as posterior vitreous base. Fluid-air or fluid-gas exchange were used in some cases based on surgical indication. The most common indications for fluid/air or fluid/gas exchange in our series were; intraoperative accidentally discovered or iatrogenic retinal break, choroidal detachment (CD), accidental retinal hit by endoinstruments even without intraoperative break and a preoperative CME to decrease the risk of postoperative MH.

Endolaser photocoagulation was performed in the setting of accidentally discovered or iatrogenic retinal tears.

In the 25-gauge vitrectomy group, the newly designed 25-gauge Naito microcannula system (Duckworth & Kent Inc., Hertfordshire, UK) was used (7). The conjunctiva and Tenon capsule were displaced over the sclera to avoid communication

between the conjunctival and scleral entry sites and to minimize possible fluid leakage postoperatively. The conjunctiva was fixed to the sclera with a fixation ring and the incisions were made by inserting a 25-gauge microvitrectoretinal (MVR) blade at a 30° to 40° angle through the conjunctiva, sclera and the pars plana 3.5-4 mm posterior to the limbus. The 25-gauge microcannulas were inserted through the conjunctival incision and the scleral tunnel using a cannula inserter.

Epiretinal membrane was peeled from the surface of the retina and removed using both the 25-gauge MVR and ILM forceps. Finally, after completion of vitrectomy, microcannulas were removed from the scleral tunnels and the conjunctiva was pushed laterally using a cotton wool applicator to separate its incision from the scleral incision and pressure was applied over the sclera for wound closure for a few seconds. At the end of the surgery, all sclerotomy sites were inspected to detect bleb formation or any frank leakage that may require suture placement.

In 20-gauge vitrectomy, sclerotomies were made after conjunctival peritomy and an infusion cannula was placed. Epiretinal membrane was peeled from the surface of the retina and removed using both the 20-gauge MVR and intraocular forceps. At the end of surgery, the sclerotomies were closed using an 8-0 Vicryl™ suture and conjunctiva was closed using a 7-0 silk suture.

Statistical analysis :

Visual acuity was measured with a Landolt C chart, recorded in decimal equivalent and then converted to the logarithm of the minimum angle of resolution (logMAR) equivalents for statistical analysis. Visual improvement was defined as increase in the postoperative vision by one line or more than baseline values. All parameters were statistically

analyzed using the paired *t*-test and independent *t*-test ; using SPSS software for Windows, with a *p* value of less than 0.05 was considered to be statistically significant. Z-test was used to compare between two proportions. We defined the postoperative hypotony as an IOP of less than 8 mmHg (8, 9). Increased IOP was defined as IOP of ≥ 22 mmHg considering 21 mmHg as the upper limit of normal. Anterior chamber cell grading was done according to the SUN (Standardization of Uveitis Nomenclature) working group grading scheme for anterior chamber cells (10) as follows : 0= $<$ 1 cell, 0.5+=1-5 cells, 1+=6-15 cells, 2+=16-25 cells, 3+=26-50 cells, 4+= $>$ 50 cells.

RESULTS

Patients in both groups were matched in their baseline characteristics (Table 1). There was no statistically significant difference in mean baseline logMAR BCVA (0.53 ± 0.27 vs. 0.45 ± 0.29 ; *p*=0.06, independent *t*-test) for the 20 and the 25-gauge groups. Mean preoperative IOP also was similar in both groups (13.99 ± 2.55 vs. 13.65 ± 3.35 mmHg ; *p*=0.42) in the 20 and 25-gauge groups respectively.

Intraoperative complications

We did not find any intraoperative problems related to 25-gauge instrumentation such as deformation of the microcannula, disconnection of the infusion cannula or breakage of the vitreous cutter. Intraoperatively, we reported 2 cases of iatrogenic retinal breaks occurred with 20-gauge vitrectomy both were nasal breaks and discovered intraoperatively. In these 2 cases posterior vitreous detachment was surgically induced. On the other hand, we reported one intraoperative retinal break with

Table 1. Patients' Demographics

Parameter		20-G	25-G	Total	P-value
Operated eye	OD	50	53	103	
	OS	45	52	97	
	Total	95	105	200	0.16
Gender	Male	44	46	90 (45%)	0.36
	Female	51	59	110 (55%)	0.36
Average age (yrs)		65.46	67.38		0.10
Lens Status	Phakic eyes	86 (91%)	95 (90%)	181 (91%)	0.51
	Pseudophakic	9 (9%)	10 (10%)	19 (9%)	0.51

20-G, 20-gauge vitrectomy group ; 25-G, 25-gauge vitrectomy group ; OD, right eye ; OS, left eye ; Data is presented as number of eyes (%)

25-gauge vitrectomy caused by retinal injury by ILM foreceps during ERM peeling. All intraoperative breaks were treated by intraoperative endolaser photocoagulation and if necessary gas tamponade. No intraoperative retinal breaks were related to sclerotomy sites in either group. We reported one case of intraoperative vitreous hemorrhage in 20-gauge group compared to no cases in 25-gauge group and there was no eyes of intraoperative choroidal detachment (CD) in the 20-gauge group compared to one case with the 25-gauge vitrectomy that disappeared by the 5th postoperative day without sequelae. There were no statistically significant differences between both groups regarding the intraoperative complications ($p > 0.05$). No eyes in 25-gauge group required a suture at the sclerotomy site because of leakage and no sclerotomies were converted to the 20-gauge procedure for the management of existing surgical pathology or intraoperative complications. At the end of the surgery, 55 versus 12 eyes were injected with air, 20 versus 2 eyes were injected with gas and 20 versus 91 eyes were left with fluid filled vitreous cavity in the 20 and 25-gauge groups respectively.

Postoperative results :

In both groups, mean logMAR BCVA improved significantly at the 1st postoperative month ($p=0.00$, paired t -test) and thereafter ($p=0.00$) compared with mean preoperative logMAR BCVA (p -gives 95% confidence intervals for this finding) (Fig. 1). Visual improvement was better in the 25 than in the 20-gauge group in all phases of postoperative follow up period, being significant only at the 1st postoperative month ($p=0.008$, independent t -test) (Fig. 1). Also the 25-gauge group established a higher incidence of visual improvement and a lower incidence of visual worsening at all phases of postoperative follow up than 20-G group, the incidence of visual improvement was significantly higher at the 6th postoperative month (82% vs. 71% of eyes) for the 25 and 20-gauge groups respectively ($p=0.04$) (Fig. 2).

Mean postoperative IOP of 20-gauge group was significantly higher than that of 25-gauge group in all phases of postoperative follow up ($p < 0.05$) (Fig. 3). When mean preoperative and postoperative IOP were compared for each group separately, we found

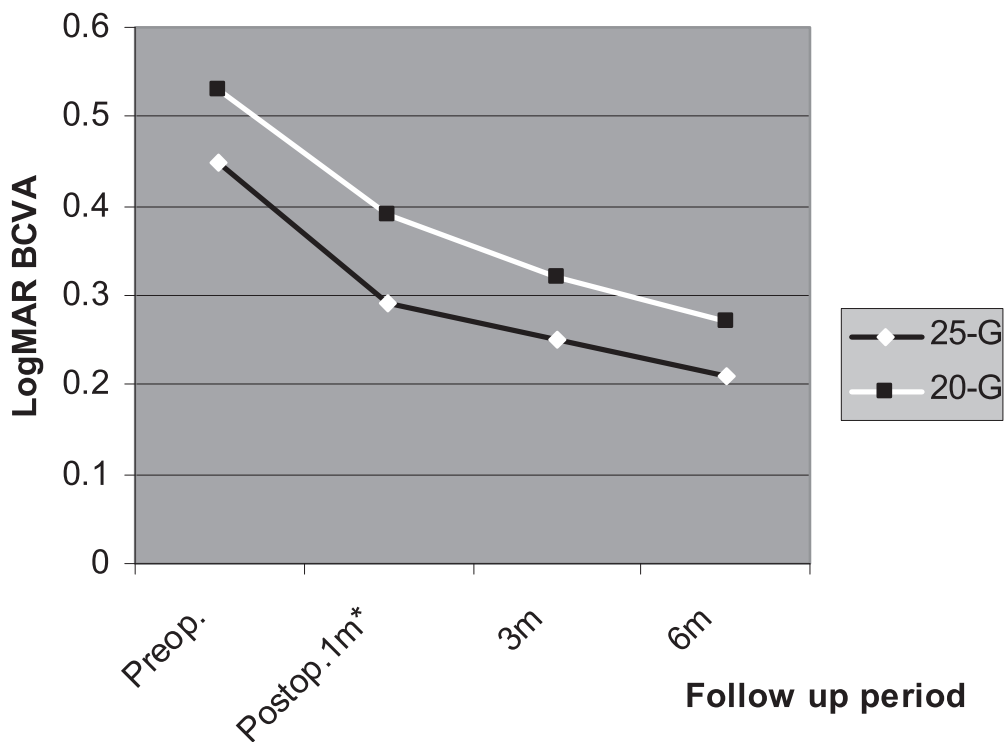


Fig. 1 Comparison between preoperative and postoperative mean logarithm of minimum angle of resolution best corrected visual acuity (logMAR BCVA) in 20- and 25-gauge vitrectomy.

Vision improved significantly in both groups when compared to baseline values.

BCVA was significantly better in the 25- than 20-G group at the 1st postoperative month

* p value is statistically significant (< 0.05)

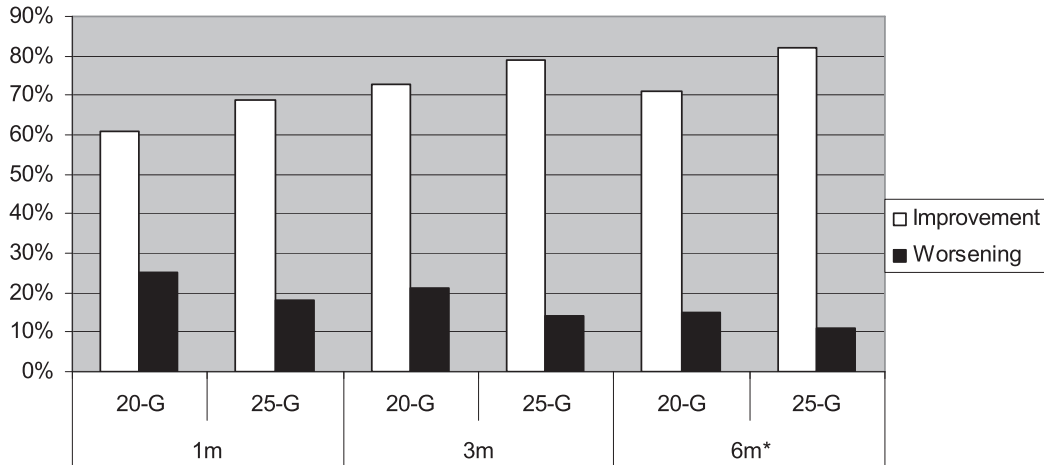


Fig. 2 Percentage of postoperative visual change in 20- and 25-G groups. Visual improvement was significantly higher in 25-G group at the 6th postoperative month. **p* value is statistically significant (< 0.05)

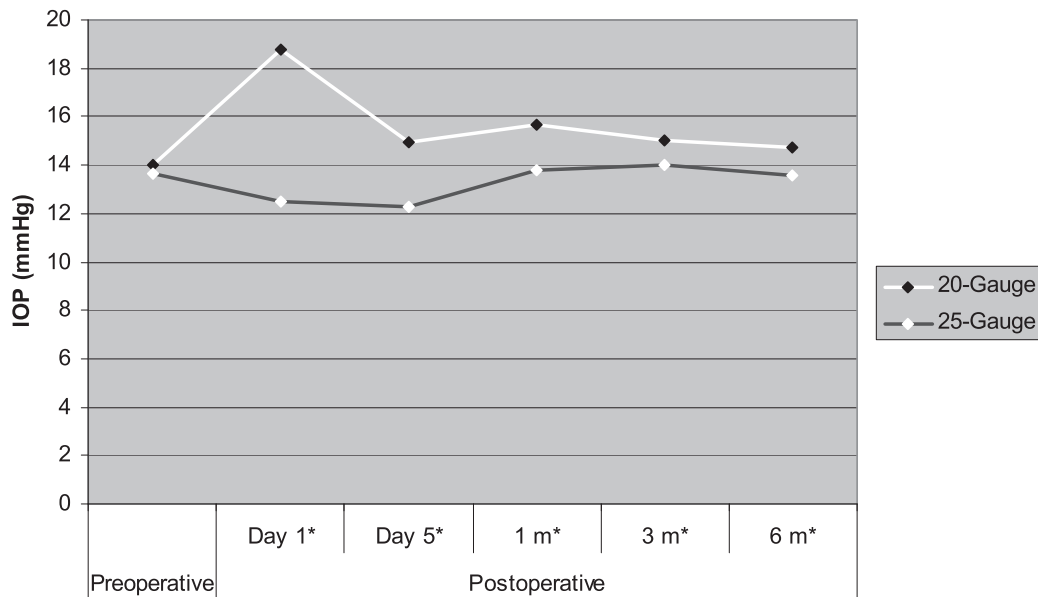


Fig. 3 Comparison between 20- and 25-G groups in preoperative and postoperative intraocular pressure (IOP) mmHg. IOP was significantly higher in 20-G than 25-G group at all phases of postoperative follow up periods. **p* value is statistically significant (< 0.05).

that ; in the 20-gauge group, the mean postoperative IOP was significantly higher than preoperative one in all phases of postoperative follow up period in contrast to 25-G group in which IOP decreases significantly only in early postoperative period (1st, 5th days) then it returned to near baseline values thereafter (Fig. 3).

Mean postoperative anterior chamber cell grading was significantly higher in 20 than 25-G group at the postoperative day 1 (3.61 ± 1.31 vs. 2.99 ± 1.33 ; $p=0.001$) and day 5 (3.31 ± 0.96 vs. 2.37 ± 1.14 , p -gives 95% confidence interval for this finding) but not

thereafter.

Twenty- gauge group showed a significantly higher incidence of anterior chamber flare at the 1st (15% vs. 5% ; $p=0.001$, Z test) ; and 5th postoperative day (20% vs. 6%, p -gives 95% confidence interval for this finding) for 20 and 25-gauge groups respectively. A higher incidence of fibrin formation has been reported also in the 20 than 25-G group but did not reach a statistically significant level, it was (5% vs 3%, $p=0.15$) at the 1st postoperative day and (3% vs 1%, $p=0.16$) at the 5th postoperative day for 20 and 25-G group respectively. (Fig. 4)

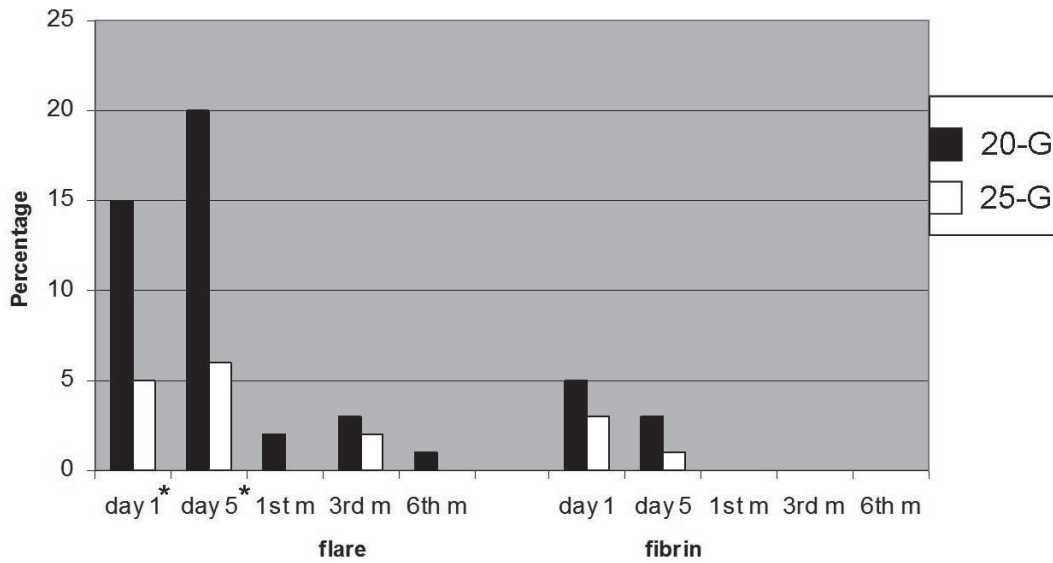


Fig. 4 Postoperative incidence of flare and fibrin formation for 20-G and 25-G groups. **p* value is statistically significant (< 0.05).

Postoperative Complications

Postoperative complications are illustrated in Fig. 5. Postoperative retinal breaks were reported in 3 eyes (3%) vs. 4 eyes (4%) in the 20 and 25-G groups respectively with no statistically significant difference between both groups (*p*=0.18). All postoperative breaks that had happened within the 1st postoperative month were discovered in eyes where surgical induction of PVD was performed in both groups. All postoperative breaks could be treated successfully by laser photocoagulation and passed

uneventually. Postoperative retinal detachment developed in 2 eyes (2%) at the 1st and 2nd postoperative months in the 20-gauge group versus 1 eye (1%) in the 25-gauge group at the 2nd postoperative month, no statistically significant difference between the 2 groups (*p*=0.25). All patients with postoperative retinal detachment could be treated successfully with re-vitrectomy, endolaser photocoagulation and gas tamponade.

High IOP (IOP ≥ 22 mmHg) at the 1st postoperative day was noted in 21 (22%) eyes of the 20-gauge group versus 2 (2%) eyes only in the 25-gauge

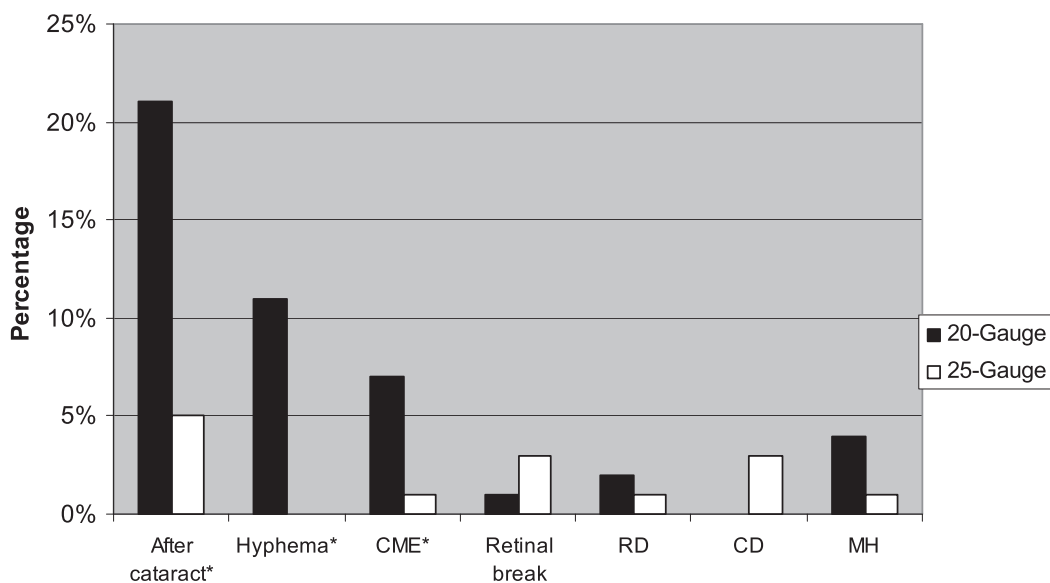


Fig. 5 Postoperative complications for 20-G and 25-G groups. **p* value is statistically significant (< 0.05).

RD, retinal detachment ; CD, choroidal detachment ; MH, macular hole ; CME, cystoid macular edema.

group. On the other hand, the most frequent complication in the 25-gauge group was the 1st postoperative day hypotony which was not observed in any patients of the 20-gauge group. Hypotony was noted in 23 (22%) eyes of the 25-gauge group, on the 1st postoperative day, all was fluid filled except 2 cases were air filled. Seven of 23 eyes with hypotony continued to the 5th postoperative day. The intraocular pressure returned to baseline values within 5 days thereafter without any intervention. Two patients had a CD with hypotony, both were fluid filled, spontaneous resolution occurred by the 5th postoperative day. Choroidal detachment without hypotony was noted in 1 eye of 25-gauge group, spontaneous resolution occurred before the 1st postoperative month. No eyes with CD were seen in the 20-G group.

In 25-G group ; postoperative leakage was noted in 16 eyes : 13 eyes with subconjunctival leakage (only positive bleb), 2 eyes with external leakage (positive Seidle test) and one eye with both external and subconjunctival leakage (positive conjunctival bleb and positive Seidle test). All eyes of external leakage were observed at the 1st postoperative day only, 6 eyes of positive conjunctival blebs continue to the 5th postoperative day, all were not present thereafter and all eyes passed uneventually.

In our case series, we observed improvement of the pre-existing CME associated with ERM in both groups. Seven eyes in the 20-gauge group manifested a postoperative CME within the follow up period, these eyes was associated with severe postoperative inflammation and anterior chamber red blood cell suspension or hyphema, compared to one eye of postoperative CME in the 25-G group which was associated with ERM recurrence. A significant difference between both groups in the incidence of postoperative CME has been reported ($p=0.010$). Of the 7 eyes of CME in 20-G group, 4 eyes progressed to MH within the 6 months of postoperative follow up. One of these MHs closed spontaneously at the 1st postoperative month. The other 3 eyes required reoperation within the follow up period, compared to one eye of MH has been reported in the 25-gauge group ($p=0.07$). There was a statistically significant higher incidence of postoperative hyphema in the 20-G group 11 (11%) eyes than in the 25-G group (no cases) (p -gives 95% confidence interval for this finding). Sterile endophthalmitis was recognized in one eye of the 25-gauge group which passed uneventually after topical and systemic steroid therapy with final vision of 0 logMAR

(20/20). We did not report any case of infectious endophthalmitis in either group.

After cataract developed at a significantly higher level in 20 than in 25-G group (20% (14 of 70 eyes) vs. 5% (4 of 80 eyes) for 20 and 25-G groups respectively, (p -gives 95% confidence interval for this finding) 2 eyes required YAG laser capsulotomy in 20-G group at the 6th postoperative month.

DISCUSSION

Surgical management of idiopathic ERM was well described and consists of vitrectomy and removal of the abnormal tissue (11, 12). In this study, the safety profile between 25 and 20-gauge vitrectomy was evaluated in patients with idiopathic ERM. We focused on 3 primary outcomes : postoperative BCVA, intraoperative and postoperative complications. The comparative study between the 20 and 25-gauge vitrectomy in the ERM surgery was done twice before ; in these 2 studies, the total number of patients enrolled was 46 and 67 eyes which is a limited number. In contrast, our study included large number of series that was not included before (200 eyes). Moreover ; it included a detailed analysis, not only of the postoperative BCVA in both groups, but also of a wide variety of intraoperative and postoperative complications which have an intimate relation to the visual outcome and had not been discussed in details in the previous studies.

Our study revealed that, although the postoperative BCVA was significantly improved in both groups than baseline values ; a faster visual recovery was achieved in the 25-gauge group. Although these results are comparable to the previous reports (5, 6, 9), the something new in our study is that : the incidence of visual improvement was higher for 25 than 20-G group at the 1st and 3rd postoperative months and reached a statistically significant level at the 6th postoperative month. These results are not in agreement with Rizzo *et al.* (5) who reported no statistically significant difference between both groups 6 months after surgery which may be due to their small sample size. Faster visual recovery and higher incidence of visual improvement with 25-gauge vitrectomy may be related to its significantly lower postoperative inflammation and less postoperative complications. The reported significantly higher postoperative inflammation in 20 than in 25-G group in our study is in agreement with Inoue *et al.* who reported that ; the postoperative anterior and posterior

segment inflammation is higher in the 20 than in the 25-gauge vitrectomy, which may be due to smaller sclerotomy size, lower BSS consumption and the reduced operating time with 25-G TSV that lead to a less flow of intravitreal fluid and less breakdown of blood retinal barrier (13). Regarding the postoperative mean IOP; it is important to note that the comparison between both groups at the 1st and 5th postoperative days cannot be done because of unmatched intraocular tamponading agent in both groups. By the 1st postoperative month; air/gas tamponade became nearly completely absorbed and comparison between groups would be reliable from 1 month and thereafter. We reported a significantly higher mean postoperative IOP in the 20-gauge group than the preoperative one in all phases of postoperative follow up period in contrast to the 25-G group in which IOP decreases significantly only in early postoperative period (1st, 5th days) and return to near baseline values thereafter without affection of visual outcome. This was in agreement with Byeon *et al.* (14) but in contrast to another study that found no significant difference between the preoperative and different postoperative IOP values with 25-gauge vitrectomy in ERM surgery (5). On the other hand, Byeon *et al.* (14) reported 3 cases of persistent high IOP within the 1st postoperative month with 25-G TSV which was not observed in our study, we did not report any cases of such IOP elevation, this may be due to our patient selection as ERM patients are not at the same risk for postoperative elevation of IOP as patients with PDR who were included in the latter study. The higher IOP with 20-G group may be due to the higher postoperative inflammation.

Intraoperative occurrence of small petechiae from the perifoveal capillary bed is a common phenomenon during removal of the ERM in both groups that was simply controlled by temporarily elevating the intraocular pressure with no effect on the final vision.

Retinal breaks and detachment as intraoperative complications were infrequent. In fact the 20-gauge surgery was associated with a slightly higher, albeit insignificant, incidence of intraoperative rhegmatogenous complications than 25-G group. These results were in agreement with the study of Shaikh *et al.* in which, rhegmatogenous complications took the upper hand in the intraoperative settings with no statistical significant difference between the 20 and 25-gauge groups (9). Based upon our observation and follow up, when intraoperative retinal breaks or

detachments do occur in the 25-gauge surgery, they can be treated effectively by limited interventions during surgery. Scleral buckling, silicone oil and/or conversion to 20-gauge vitrectomy do not appear to be necessary in dealing with such complications. No eyes in the 25-gauge study group were required conversion to a 20-gauge vitrectomy for the management of an existing surgical pathology or intraoperative complications which were the same as the results of previous studies (8, 9, 15) but in contrast to other studies in which 2 out of 50 eyes of 25-gauge vitrectomy needed to be converted to 20-gauge vitrectomy (14). This discrepancy in the results may be due to the use of the newly designed titanium 25-gauge microcannula system in our study, which was strong enough to remove strong membranes and the step of the microcannula was quite effective in preventing slippage or loss.

In our case series, no patients in the 25-gauge group required an intraoperative suture at the sclerotomy site because of leakage whereas, intraoperative suturing rate of 7.1% was previously reported (16) which may be due to the oblique scleral tunnel construction of the sclerotomy site in our case series.

The significantly higher postoperative inflammation that was noted in the 20-G group in our study can explain the significantly higher incidence of CME and subsequent development of MH. Also it can explain the higher incidence of hyphema, higher IOP and the significantly higher incidence of after cataract in the same group.

Retinal detachment, secondary to a retinal tear, was reported to be the second most frequent postoperative complication of vitrectomy for ERM surgery (progression of nuclear sclerosis being the 1st one) (17). A large variation exists on the previously reported incidence of breaks range from 0% to 7.2% (18, 19) and rhegmatogenous retinal detachment (RRD) after 20-G vitrectomy between 1% and 16% (20). It is considered to be a relatively rare complications following 25-G TSV (16). Published postoperative retinal detachment rates following 25-G TSV have ranged from 0% to 2.8% (2, 3, 14, 21). We reported no statistically significant difference between the 2 groups regarding the postoperative rhegmatogenous complications. Some concerns exist about vitreous incarceration at the sclerotomy sites, which may be a possible cause for postoperative complications such as endophthalmitis and retinal detachment in sutureless vitrectomy and vitreous incarceration in the sclerotomy site during withdrawal

of instruments could also cause significant anterior vitreoretinal traction and subsequent retinal tears (8, 22). Our results do not support this theory as our rate of postoperative rhegmatogenous complications was comparable in both groups and was at much lower rate than that reported by Tan *et al.* for the 25-gauge vitrectomy (22) with no reported cases of infectious endophthalmitis. This may be explained by our surgical trend for careful peripheral vitrectomy and meticulous shaving of the vitreous base with scleral depression with specific attention to the sclerotomy sites which also contributed to that, none of our rhegmatogenous complications were related to sclerotomy site but ; on the other hand, this meticulous shaving of the vitreous base at the sclerotomy site seems to be also responsible for our reported high incidence of postoperative leakage (15%) in the 25-gauge group. In agreement with Gupta *et al.* the postoperative hypotony was significant only at the 1st postoperative day (22%) this high incidence may be because the majority of eyes in the 25-gauge group were fluid filled eyes which put them at a higher risk for hypotony (16). This hypotony might not be an issue, because no intervention was needed in these cases.

This study demonstrates statistical strength over previously published reports. To the authors' best knowledge, this report represents the greatest number of comparison between the 20 and 25-gauge group in ERM surgery. Moreover, the 20-gauge vitrectomy group served as a control to the 25-gauge vitrectomy group, because the same surgeons who encountered somewhat higher postoperative complications with the 20-gauge vitrectomy are those who also performed the 25-gauge vitrectomy in this study, thus eliminating operator bias. Also, consecutive enrollment of patients allowing for evaluation of the safety, efficacy, and postoperative outcomes of the 25-gauge vitrectomy during the surgeon's initial learning curve. In addition, we included a detailed comparison of intraoperative and postoperative complications detected in both groups.

In conclusion, the results of this study demonstrate that, for patients with idiopathic ERM, 25-gauge vitrectomy is equal to 20-gauge vitrectomy regarding intraoperative complications and superior to it in having a significantly less postoperative inflammation and complications with subsequent rapid visual recovery, higher rate of visual improvement and earlier visual rehabilitation

CONFLICT OF INTEREST

None of the authors have any financial interests to disclose.

REFERENCES

1. Fujii GY, De Juan E Jr, Humayun MS, Chang TS, Pieramici DJ, Barnes A, Kent D : Initial experience using the transconjunctival sutureless vitrectomy system for vitreoretinal surgery. *Ophthalmology* 109 : 1814-1820, 2002
2. Fujii GY, De Juan E Jr, Humayun MS, Pieramici DJ, Chang TS, Awh C, Ng E, Barnes A, Wu SL, Sommerville DN : New 25-gauge instrument system for transconjunctival sutureless vitrectomy surgery. *Ophthalmology* 109 : 1807-1813, 2002
3. Lakhanpal RR, Humayun MS, De Juan E Jr., Lim JI, Chong LP, Chang TS, Javaheri M, Fujii GY, Barnes AC, Alexandrou TJ : Outcomes of 140 consecutive cases of 25-gauge transconjunctival surgery for posterior segment disease. *Ophthalmology* 112 : 817-824, 2005
4. Kellner L, Wimpfissinger B, Stolba U, Brannath W, Binder S : 25-gauge vs. 20-gauge system for pars plana vitrectomy : a prospective randomised clinical trial. *Br J Ophthalmol* 91 : 945-948, 2007
5. Rizzo S, Genovesi-Elbort F, Murri S, Murri S, Belting C, Vento A, Cresti F, Manca ML : 25-gauge sutureless vitrectomy and standard 20-gauge pars plana vitrectomy in idiopathic epiretinal membrane surgery : a comparative pilot study. *Graefes Arch Clin Exp Ophthalmol* 244 : 472-479, 2006
6. Kadonosono K, Yamakawa T, Uchino E, Yanagi Y, Tamaki Y, Araie M : Comparison of visual function after epiretinal membrane removal by 20-gauge and 25-gauge vitrectomy. *Am J Ophthalmol* 142 : 513-515, 2006
7. Naito T : Transconjunctival sutureless 25-gauge vitrectomy with newly designed microcannulas. *J Med Invest* 55 : 51-53, 2008
8. Ibarra MS, Hermel M, Prenner JL, Hassan TS : Longer-term outcomes of transconjunctival sutureless 25-gauge vitrectomy. *Am J Ophthalmol* 139 : 831-836, 2005
9. Shaikh S, Ho S, Preston P, Olson JC, Barnes CD : Untoward outcomes in 25-gauge versus 20-gauge vitreoretinal surgery. *Retina* 27 :

- 1048-1053, 2007
10. Jabs DA, Nussenblatt RB, Rosenbaum JT : Standardization of uveitis nomenclature for reporting clinical data. Results of the First International Workshop. *Am J Ophthalmol* 140(3) : 509-516, 2005
 11. de Bustros S, Thompson J, Michels R Rice TA, Glaser BM : Vitrectomy for idiopathic epiretinal membranes causing macular pucker. *Br J Ophthalmol* 72 : 692-695, 1988
 12. Park DW, Dugel PU, Garda J, Sipperley JO, Thach A, Sneed SR, Blaisdell J : Macular pucker removal with and without internal limiting membrane peeling : pilot study. *Ophthalmology* 110 : 62-64, 2003
 13. Inoue Y, Kodonsono K, Yamakawa T, Uchio E, Watanabe Y, Yanagi Y, Tamaki Y, Araie M : Surgically induced inflammation with 20-, 23-, and 25-gauge vitrectomy systems. An experimental study. *Retina* 29 : 477-480, 2009
 14. Byeon SH, Chu YK, Lee SC, Koh HJ, Kim SS, Kwon OW : Problems Associated with the 25-gauge transconjunctival sutureless vitrectomy system during and after surgery. *Ophthalmologica* 220 : 259-265, 2006
 15. Patelli F, Radice P, Zumbo G, Fineman MS, Kaiser RS, Ho AC, McNamara JA, Vander JE : 25-gauge macular surgery : results and complications. *Retina* 27 : 750-754, 2007
 16. Gupta OP, Weichel ED, Regillo CD, Fineman MS, Kaiser RS, Ho AC, McNamara JA, Vander JE : Postoperative complications associated with 25-gauge pars plana vitrectomy *Ophthalmic Surg Lasers Imaging* 38 : 270-275, 2007
 17. Donati G, Kapetanos AD, Pournaras CJ : Complications of surgery for epiretinal membranes. *Graefes Arch Clin Exp Ophthalmol* 236 : 739-746, 1998
 18. Moore JK, Kitchens JW, Smiddy WE, Mavroufides EC, Gregorio G : Retinal breaks observed during pars plana vitrectomy. *Am J Ophthalmol* 144 : 32-36, 2007
 19. Wimpissinger B, Binder S : Entry-site-related retinal detachment after pars plana vitrectomy. *Acta Ophthalmol Scand* ; 85 : 782-785, 2007
 20. Guillaubey A, Malvitte L, Lafontaine PO : Incidence of retinal detachment after macular surgery : a retrospective study of 634 cases. *Br J Ophthalmol* 91 : 1327-1330, 2007
 21. Shimada H, Nakashizuka H, Mori R, Mizutani Y, Hattori T : 25-gauge scleral tunnel transconjunctival vitrectomy. *Am J Ophthalmol* 142 : 871-873, 2006
 22. Tan HS, Mura M, de Smet MD : Iatrogenic Retinal Breaks in 25-gauge Macular Surgery. *Am J Ophthalmol* 148 : 427-430, 2009