

ORIGINAL

Changes of tumor and normal structures of the neck during radiation therapy for head and neck cancer requires adaptive strategy

Ryota Bando¹, Hitoshi Ikushima², Takashi Kawanaka³, Takaharu Kudo⁴, Motoharu Sasaki¹, Masahide Tominaga², Taro Kishi¹, Shunsuke Furutani³, Akiko Kubo³, and Koichi Tamura⁵

¹Department of Clinical Support, the Tokushima University Hospital, Tokushima, Japan, ²Department of Radiation Therapy Technology, ³Department of Radiology, ⁴Department of Oral Surgery, ⁵Department of Otorhinolaryngology and Communicative Neuroscience, Institute of Health Biosciences, the University of Tokushima Graduate School, Tokushima, Japan

Abstract : The treatment period over which radiation therapy is administered extends over several weeks. Since tumor shrinkage in response to radiation therapy and weight loss due to radiation-induced mucositis may impact on the dose distribution in both target and organ at risk in patients with head and neck cancer, the anatomical changes of tumor and neck volumes during this period should be taken into consideration. We investigated the anatomical changes that occurred in the target and normal structure of the neck during radiation therapy for pharyngeal cancer, and evaluated the necessity of an adaptive strategy. Ten patients with pharyngeal cancer who underwent radical chemoradiation therapy using 3-dimensional conformal radiation therapy RT (66-70 Gy in 33-35 fractions) between April 2009 and September 2010 were enrolled in the study. Patients underwent CT scans every week during their course of treatment. We analyzed the CT data in the radiation treatment planning system and measured changes of tumor, organ at risk, and neck volume. Gross tumor volume (GTV) was rapidly reduced by 28% of the original volume on average in the first 3 weeks. The right and left submandibular glands volume decreased to 70% and 63% of their initial volumes on average, respectively. The volume of the neck in the radiation fields decreased to 89% of its initial volume on average by the sixth week mainly caused by body weight loss due to acute radiation morbidity. Considerable anatomical change in the radiation field that will affect dose distribution of the target and organ at risk was observed during radiation therapy for head and neck cancer. *J. Med. Invest.* 60 : 46-51, February, 2013

Keywords : adaptive strategy, chemoradiation therapy, head and neck cancer

Received for publication May 14, 2012 ; accepted October 18, 2012.

Address correspondence and reprint requests to Hitoshi Ikushima, Department of Radiation Therapy Technology, Institute of Health Biosciences, the University of Tokushima Graduate school, 3-18-15 Kuramoto-cho, Tokushima 770-8503, Japan and Fax : +81-88-633-9051.

INTRODUCTION

Radiation therapy (RT) in general requires a treatment period of 5 to 7 weeks. Tumor shrinkage in response to RT and weight loss due to radiation-induced mucositis may impact on the dose distribution in both target and organ at risk in patients

with head and neck cancer. However, anatomical changes of tumor and normal tissues in the treatment field during the course of treatment are not considered. Anatomical changes during the treatment period may affect the therapeutic outcome of high precision external beam therapies such as intensity modulated radiation therapy (IMRT). IMRT enables conformal dose distribution to the target, and more highly precision is required in positioning of the target than conventional 3-dimensional conformal RT. Anatomical changes during the course of treatment can cause radiation overdose to the organ at risk or lack of dose to the target. In some studies (1-3), influence of anatomical changes that occurred during the course of image guided RT (IGRT) on dose distribution have been investigated using kilovoltage CT (KVCT) and megavoltage CT (MVCT). The study (4) that evaluated changes of gross tumor volume (GTV) occurring during RT for non-small-cell lung cancer concluded that additional radiation treatment planning is necessary when the gross tumor volume (GTV) had decreased by more than 30%. In the studies (5, 6) in which anatomical changes during RT for head and neck cancer were investigated, the possibility that anatomical changes could affect the dose distribution was underlined. In the present study, we investigated the necessity of an adaptive strategy for radiation therapy of head and neck cancer, by evaluating anatomical changes of the tumor and normal structures in the radiation fields.

MATERIALS AND METHODS

Patient characteristics

This prospective study was approved by our Institutional Review Board, and informed consent

was waived. Ten patients who underwent radical chemoradiation therapy (CRT) for pharyngeal cancer between April 2009 and September 2010 were enrolled in this study (Table 1).

Chemoradiation therapy

Radiation treatment planning was performed using a 3-dimensional radiation treatment planning system (RTPS, Xio ver. 4.5.0, Computerized Medical Systems, Maryland Heights, MO, USA) at the beginning of CRT with a prescription dose of 66-70 Gy/33-35 fractions. All patients underwent two courses of concurrent chemotherapy consisting of 5-fluorouracil+cisplatin.

Volume measurement of target and organ at risk

All contours of the target and organ at risk were delineated on the computed tomography (CT)-magnetic resonance imaging (MRI) fusion images by the same radiation oncologist (H. I.). The CT scan was performed using an Asteion Super 4 Edition multislice (Toshiba Medical Systems, Tochigi, Japan), and MR images were obtained using a Signa Excite HD 1.5T (GE Yokogawa Medical Systems, Tokyo, Japan). All patients underwent a CT scan every week during the treatment course at the same fixed position as the position used for RT. The position was maintained using an immobilizing mask made of thermoplastic plastics. The whole neck between the base of the skull and the supraclavicular region was scanned at a 3 mm slice thickness. Target and organ at risk delineated in this study are listed in Table 2.

During the course of the treatment period, the isocenter remained the same. The volume of the target and critical organ were measured on every CT scan, and body weight, serum protein, and acute radiation toxicity (common toxicity criteria version

Table 1. Patient characteristics

Pt. No	Gender	Age	cTNM	Stage	Disease	Hisotology
1	M	62	T3N2bM0	IVA	oropharyngeal cancer	SCC
2	M	78	T4aN1M0	IVA	oropharyngeal cancer	SCC
3	M	52	T3N2bM0	IVA	oropharyngeal cancer	SCC
4	M	68	T4N2cM0	IVA	oropharyngeal cancer	SCC
5	M	62	T4N2M0	IVA	epipharyngeal cancer	SCC
6	M	67	T1N2M0	III	epipharyngeal cancer	SCC
7	F	61	T2N2cM0	IVA	oropharyngeal cancer	SCC
8	M	54	T4N2bM0	IVB	oropharyngeal cancer	SCC
9	M	67	T2N2bM0	IVA	oropharyngeal cancer	SCC
10	M	64	T3N2cM1	IVA	hypopharyngeal cancer	SCC

SCC, squamous cell cancer

Table 2. Delineation of targets and organ at risk

GTV	Visible tumor on imaging
CTV1	GTV+5 mm isotropic margin
PTV1	CTV+3 mm isotropic margin
CTV2	Prophylactic lymph node area (7, 8).
PTV2	CTV2+3 mm isotropic margin
Normal tissue (submandibular glands, spinal cord)	Spinal cord was identified using an automatic outline drawing function.
Dens	The origin of the coordinate axes was set at the center of the dens in all radiotherapy planning.
Cervical volume	We defined it as the volume of the neck between the range of ± 3.9 cm from an isocenter. Outer contour of the neck was identified using an automatic outline drawing function.

GTV, gross tumor volume ; CTV, clinical target volume ; PTV, planning target volume

3.0) was evaluated every week during treatment.

The volume of the target and organ at risk was calculated automatically by delineating the contours on RTPS.

Estimated dose changes of the spinal cord caused by anatomical changes in IMRT

Fig. 1 is showing a dose distribution of postulated IMRT planning. Estimated change of maximum dose of the spinal cord if IMRT was applied to the same situation of anatomical changes derived from the data of the present study was calculated. Upper limit of dose of spinal cord was set at 40 Gy in the treatment planning of IMRT.

Statistical analysis

Analysis of variance was performed using Excell ver. 2007. (Microsoft Corporation, Tokyo, Japan) Two-factor ANOVA was used to evaluate a statistical significance in reduction of GTV, submandibular gland, neck volume, body weight loss, and serum protein. Turkeykramer method of post-hoc-test was used for the comparison between the groups every week. Test of coefficient of correlation of Pearson was used to evaluate the correlation between body weight loss and cervical volume reduction.

RESULTS

Changes of GTV and the submandibular gland of a case who had oropharyngeal cancer are shown in Fig. 1. Changes of GTV and volume of the submandibular glands are shown in Figs 2, 3 and 4. A marked reduction of GTV by 28% of the initial volume was seen by the third week during RT ($P < 0.01$). By the sixth week, an average reduction of

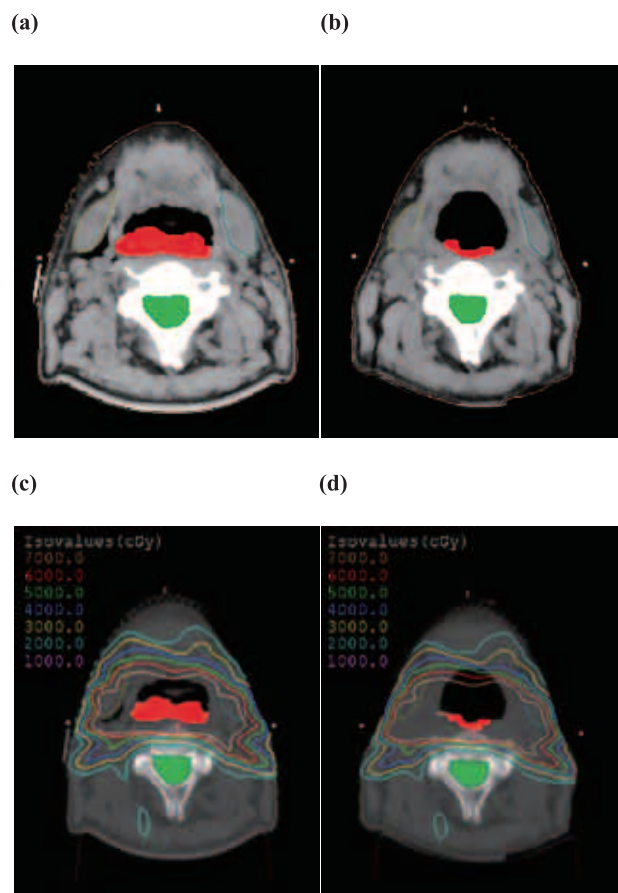


Fig. 1. Axial images of computed tomography (CT) of a patient with oropharyngeal cancer, Gross tumor volume and spinal cord were delineated on CT.

(a) : Planning CT at initiation of radiation therapy

(b) : Four weeks after initiation of radiation therapy

(c) : Dose distribution chart of IMRT on initial treatment planning CT

(d) : Dose distribution chart of IMRT projected on CT image at 4 weeks after initiation of radiation therapy

volume of 30 and 27% was observed in the right and left submandibular gland, respectively ($P < 0.01$). Not only GTV but also the volume of the submandibular glands and the cervical volume were reduced

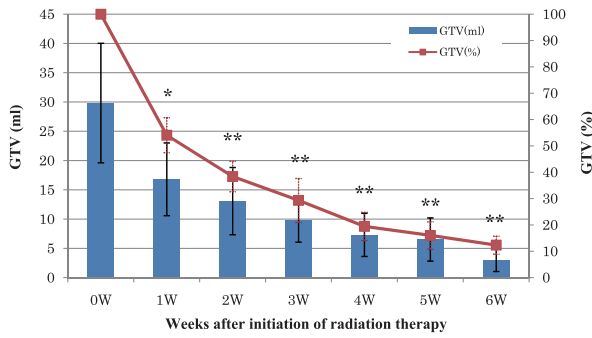


Fig. 2. Weekly changes of GTV, columns and bars mean averages \pm SE, * $p < 0.05$ vs. 0W, ** $p < 0.01$ vs. 0W

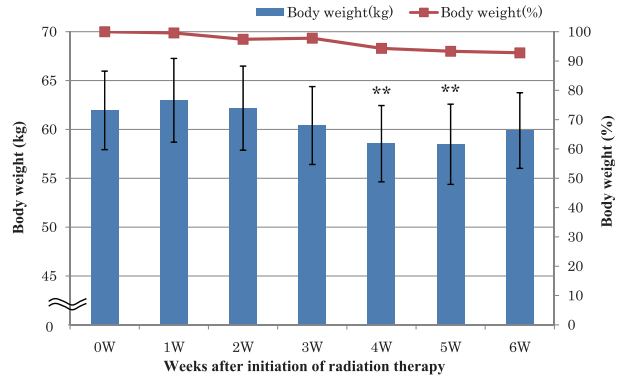


Fig. 5. Weekly changes of body weight, columns and bars mean averages \pm SE, * $p < 0.05$ vs. 0W, ** $p < 0.01$ vs. 0W

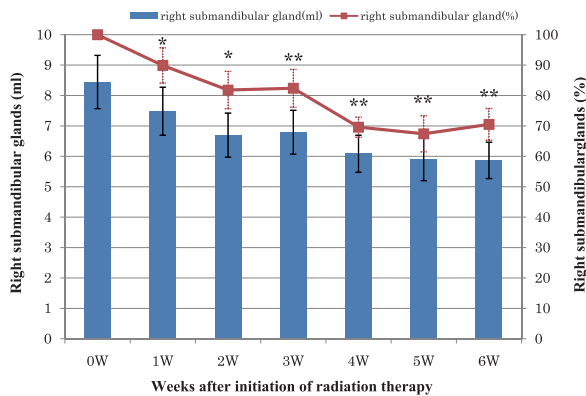


Fig. 3. Weekly changes of volume of right submandibular gland, columns and bars mean averages \pm SE, * $p < 0.05$ vs. 0W, ** $p < 0.01$ vs. 0W

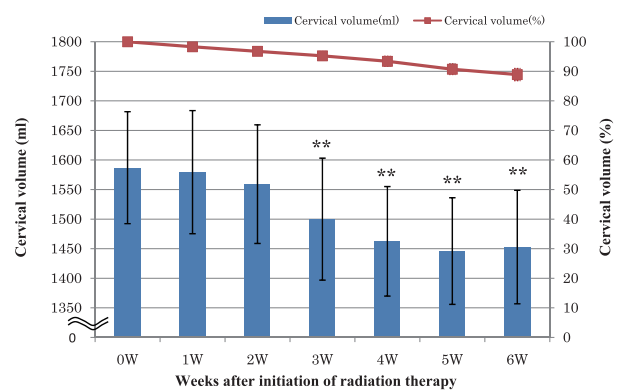


Fig. 6. Weekly changes of cervical volume, columns and bars mean averages \pm SE, * $p < 0.05$ vs. 0W, ** $p < 0.01$ vs. 0W

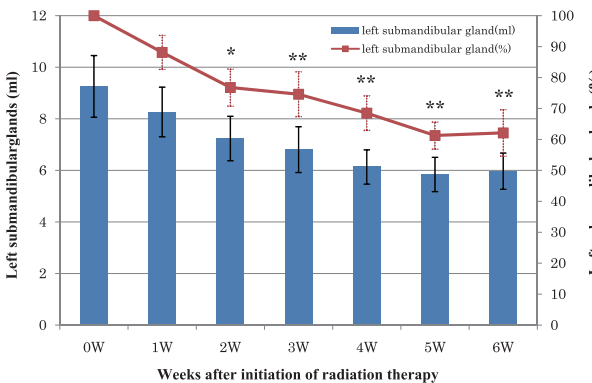


Fig. 4. Weekly changes of volume of left submandibular gland, columns and bars mean averages \pm SE, * $p < 0.05$ vs. 0W, ** $p < 0.01$ vs. 0W

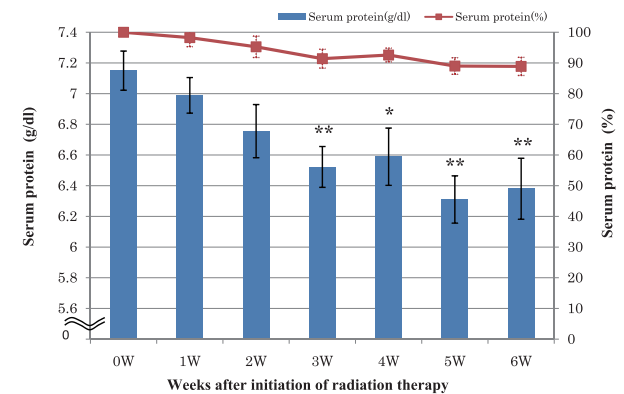


Fig. 7. Weekly changes of Serum protein, columns and bars mean averages \pm SE, * $p < 0.05$ vs. 0W, ** $p < 0.01$ vs. 0W

by 4 weeks after the beginning of CRT ($P < 0.01$). Changes of body weight, volume of the neck and serum protein are shown in Fig. 5, 6, and 7. CTC Grade of radiation mucositis increased up to 2 or 3 during RT in all patients.

There was body weight loss of 7%, neck volume reduction of 11%, and serum protein reduction of 12% on average during CRT, caused by eating disorder due to radiation mucositis. There was statis-

tically significant correlation between the body weight loss and the cervical volume reduction ($r = 0.59$, $P < 0.07$). (Fig. 8)

When IMRT plan was applied to the same situation of anatomical changes derived from the present study, cumulated dose of spinal cord exceeded upper dose limit of 40 Gy defined at the initial treatment planning in 2 patients (patient No2 and 10). (Fig. 9)

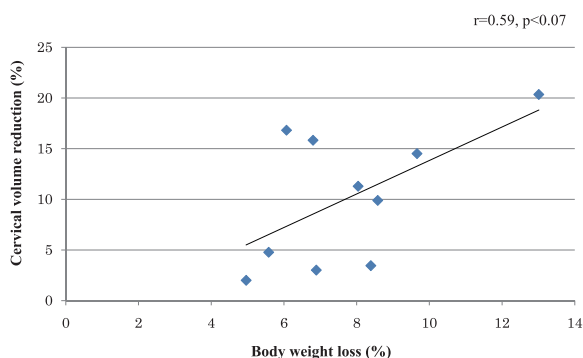


Fig. 8. Coefficient of correlation of the body weight loss and the cervical volume reduction

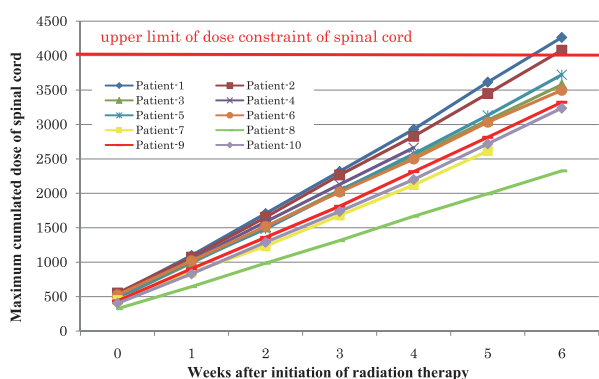


Fig. 9. Changes of maximum dose of spinal cord when intensity-modulated radiation therapy plan was applied to the same situation of anatomical changes derived from the present study. Upper dose limit of spinal cord was set at 40 Gy in dose constraint of initial radiation treatment planning of intensity modulated radiation therapy.

DISCUSSION

Considerable anatomical changes occurred during CRT, especially in tumor volume as a response of CRT within 3 weeks after initiation of CRT. Significant scaling down of normal soft tissue surrounding the tumor and organ at risk caused by hypoalimentation as a consequence of acute radiation morbidity and volume reduction of salivary glands probably caused by functional deterioration due to CRT were also observed. IMRT simulation using these data showed that anatomical changes during CRT became a risk to increase radiation dose of organ at risk over the upper limit of dose constraint defined at treatment planning.

There are a number of previous studies (9, 10) concerning anatomical changes of organ at risk during the course of RT. They reported that the parotid volume decreased during the course of RT period. Barker J (5) reported that the mean dose of radiation delivered to the parotid glands had increased

by more than 10% during RT (11). Lee *et al.* (12) reported that the location of the parotid glands in the radiation field shifted to the center, while this change in location was not seen in most of the parotid glands which were not irradiated. These authors found that the parotid volume decreased and that consequently the mean dose of radiation delivered to the parotid glands was increased. In the present study, we did not evaluate anatomical changes of the parotid glands because reproducibility in the contouring of parotid glands could not be maintained due to the complexity of its shape. Some authors reported that the submandibular glands in the radiation field shifted to a central location, and to a higher region of the oral cavity (12), while there was no change in the position of the unirradiated submandibular glands.

Maintenance of adequate nutritional supplementation during CRT seems to be an important countermeasure that can reduce anatomical changes due to body weight loss. Good nutritional status will also contribute to recovery from acute radiation morbidity. Nutritional supplementation via a temporal gastrostoma is one way of maintaining the patient's nutritional status. However, anatomical changes caused by tumor shrinkage and volume reduction of the salivary gland are an unavoidable event in CRT for head and neck cancer.

IMRT enables conformal dose distribution around the target, and more precision is required than conventional 3-dimensional conformal RT. Anatomical changes that occur during the course of treatment may cause lack of dose to the target and overdose to the organ at risk. The introduction of an adaptive strategy in highly precise external beam RT for head and neck cancer can reduce the influence of anatomical changes during the course of CRT. Barke *et al.* (5) reported that the therapeutic ratio can be improved by performing adaptive planning in RT for head and neck cancer. An appropriate schedule for an adaptive radiation treatment plan has not yet been established. In practice, we perform a re-treatment planning of IMRT when a total dose of 30 Gy is delivered, because GTV rapidly reduces within first 3 weeks. Re-planning based on CT data for every individual irradiation during a course of fractionated treatment is ideal. However, It is impossible to perform re-planning according to the daily anatomical changes. Development of treatment planning software with deformable registration algorithms (13, 14) is necessary to enable an ideal adaptive strategy.

REFERENCES

1. Barker J, Garden A, Dong L, O'Daniel J, Wang H, Court L, Morrison W, Rosenthal D, Chao C, Mohan R, Ang K : Radiation-Induced Anatomic Changes During Fractionated Head & Neck Radiotherapy : A Pilot Study Using An Integrated CT-LINAC System. *Int J Radiat Oncol Biol Phys* 57 : 304, 2003
2. Lee C, Langen KM, Lu W, Haimerl J, Schnarr E, Ruchala KJ, Olivera GH, Meeks SL, Kupelian PA, Shellenberger TD, Mañon RR : Evaluation of geometric changes of parotid glands during head and neck cancer radiotherapy using daily MVCT and automatic deformable registration *Radiation Oncology* 89 : 81-88, 2008
3. Castadot P, Geets X, Lee JA, Christian N, Grégoire V : Assessment by a deformable registration method of the volumetric and positional changes of target volumes and organs at risk in pharyngo-laryngeal tumors treated with concomitant chemo-radiation. *Radiation Oncology* 95 : 209-217, 2010
4. Woodford C, Yartsev S, Dar AR, Bauman G, Van Dyk J : Adaptive Radiotherapy Planning On Decreasing Gross Tumor Volumes As Seen On Megavoltage Computed Tomography Images. *Int J Radiat Oncol Biol Phys* 69 : 1316-1322, 2007
5. Barker J, Garden A, Dong L, O'Daniel J, Wang H, Court L, Morrison W, Rosenthal D, Chao C, Mohan R, Ang K : Quantification Of Volumetric And Geometric Changes Occurring During Fractionated Radiotherapy For Head-And-Neck Cancer Using An Integrated CT/LINEAR Accelerator System. *Int J Radiat Oncol Biol Phys* 59 : 960-970, 2004
6. Bhide SA, Davies M, Burke K, McNair HA, Hansen V, Barbachano Y, El-Hariry IA, Newbold K, Harrington KJ, Nutting CM : Weekly volume and dosimetric changes during chemoradiotherapy with intensity-modulated radiation therapy for head and neck cancer : a prospective observational study. *Int J Radiat Oncol Biol Phys* 76 : 1360-1368, 2010
7. Kinoshita R, Tsuchiya K, Ohmori K, Obinata K, Fujita K, Aoyama H, Oita M, Nishioka T, Suzuki K, Shirato H : Intensity-Modulated Radiation Therapy For Head And Neck Region. *J Jpn Soc Ther Radiol Oncol* 18 : 191-197, 2006
8. Chao KS, Wippold FJ, Ozyigit G, Tran BN, Dempsey JF : Determination and delineation of nodal target volumes for head-and-neck cancer based on patterns of failure in patients receiving definitive and postoperative IMRT. *Int J Radiat Oncol Biol Phys* 53(5) : 1174-1184, 2002
9. Han C, Chen YJ, Liu A, Schultheiss TE, Wong JY : Actual Dose Variation Of Parotid Glands And Spinal Cord For Nasopharyngeal Cancer Patients During Radiotherapy. *Int J Radiat Oncol Biol Phys* 70 : 1256-1262, 2008
10. O'Daniel JC, Garden AS, Schwartz DL, Wang H, Ang KK, Ahmad A, Rosenthal DI, Morrison WH, Asper JA, Zhang L, Tung SM, Mohan R, Dong L : Parotid Gland Dose in Intensity-Modulated Radiotherapy for Head and Neck Cancer : Is What You Plan What You Get? *Int J Radiat Oncol Biol Phys* 69 : 1290-1296, 2007
11. Lee C, Langen KM, Lu W, Haimerl J, Schnarr E, Ruchala KJ, Olivera GH, Meeks SL, Kupelian PA, Shellenberger TD, Mañon RR : Assessment Of Parotid Gland Dose Changes During Head And Neck Cancer Radiotherapy Using Daily Megavoltage Computed Tomography And Deformable Image Registration. *Int J Radiat Oncol Biol Phys* 71 : 1563-1571, 2008
12. Vásquez Osorio EM, Hoogeman MS, Al-Mamgani A, Teguh DN, Levendag PC, Heijmen BJ : Local Anatomic Change In Parotid And Submandibular Glands During Radiotherapy For Oropharynx Cancer And Correlation With Dose, Studied In Detail With Nonrigid Registration. *Int J Radiat Oncol Biol Phys* 70 : 875-882, 2008
13. Castadot P, John A, Lee JA, Adriane P, Geets X, Grégoire V : Comparison Of 12 Deformable Registration Strategies In Adaptive Radiation Therapy For The Treatment Of Head And Neck Tumors. *Radiation and Oncology* 89 : 1-12, 2008
14. Kashani R, Hub M, Balter JM, Kessler ML, Dong L, Zhang L, Xing L, Xie Y, Hawkes D, Schnabel JA, McClelland J, Joshi S, Chen Q, Lu W : Objective assessment of deformable image registration in radiotherapy : a multi-institution study. *Med Phys* 35(12) : 5944-5953, 2008