

ORIGINAL

The involvement of fibroblast growth factor receptor signaling pathways in dermatofibroma and dermatofibrosarcoma protuberans

Takeshi Ishigami, Yasutoshi Hida, Yoshihiro Matsudate, Kazutoshi Murao, and Yoshiaki Kubo

Department of Dermatology, Institute of Health Biosciences, the University of Tokushima Graduate School, Tokushima, Japan

Abstract : Fibroblast growth factors (FGFs) and their receptors (FGFRs) control a wide range of biological functions ; however, their involvement in the pathogenesis of dermatofibroma (DF) and dermatofibrosarcoma protuberans (DFSP) is currently unknown. In this study, we first confirmed the histological diagnosis by detecting fusion *COL1A1-PDGFB* transcripts in DFSP, and examined the expression of all FGFRs (FGFR1-4), some of their ligands (FGF1, 2, 9), and forkhead box N1 (FOXN1) as a downstream target of FGFR3 in DF and DFSP by immunohistochemical analysis. Although we failed to detect the expression of FGF1 and FGF9 as specific ligands for FGFR3 in DF, overexpression of FGFR3 and FOXN1 was observed in the epidermal regions of DF, suggesting that the epidermal regions of DF were similar to seborrheic keratosis both in terms of histological features and the activation of FGFR3/FOXN1. In addition, strong expression of FGF2 and FGFR4 was observed in the tumor lesions of DF. Expression patterns of FGFR3/FOXN1 and FGF2/FGFR4 in DF were in contrast with those of DFSP. The activation of FGFR signaling pathways may be not only relevant to the pathogenesis of DF, but also very useful in the differential diagnosis of DF and DFSP. *J. Med. Invest.* 60 : 106-113, February, 2013

Keywords : *dermatofibroma, dermatofibrosarcoma protuberans, fibroblast growth factor receptors, fibroblast growth factors, forkhead box N1*

INTRODUCTION

Dermatofibroma (DF) is a common benign fibrohistiocytic tumor that is histologically characterized by proliferating fibroblasts, collagen, capillaries, and histiocytes and is accompanied by seborrheic keratosis-like epidermal hyperplasia with hyperpigmentation of the basal layer (1). Dermatofibrosarcoma protuberans (DFSP) is a slowly growing dermal

neoplasm of intermediate malignancy that is histologically composed of spindle cells with a storiform pattern and is often characterized by an attenuated or ulcerated epidermis in the absence of hyperpigmentation (1). Despite these characteristic features, it is sometimes difficult to distinguish between DF and DFSP. Although CD34 and factor XIII have been widely used to distinguish DF from DFSP, these markers often show an overlap and lack of specificity (2). Cytogenetically, DFSP is characterized by a reciprocal translocation, t (17 ; 22) (q22 ; q13), and a supernumerary ring chromosome derived from this translocation, and the fusion transcripts of *COL1A1* and *PDGFB* genes were detected in DFSP as a reliable and useful diagnostic

Received for publication November 21, 2012 ; accepted January 17, 2013.

Address correspondence and reprint requests to Yoshiaki Kubo, Department of Dermatology, Institute of Health Biosciences, the University of Tokushima Graduate School, Kuramoto-cho, Tokushima, 770-8503, Japan and Fax : +81-886-32-0434.

marker for DFSP (3). However, *COL1A1-PDGFB* fusions have not been detected in around 8% of the lesions of DFSP (4).

Fibroblast growth factors (FGFs) and their receptors (FGFRs) control a wide range of biological functions including the regulation of cellular proliferation, survival, migration, and differentiation (5). The FGF family comprises 18 ligands that exert their actions through 4 highly conserved transmembrane tyrosine kinase receptors (FGFR1, FGFR2, FGFR3, and FGFR4) (5). Although overexpression of FGFR2 has been reported in the epidermal and dermal regions of DF (6), the involvement of other FGFRs in DF and all 4 FGFRs in DFSP has not yet been examined.

Among FGFRs, the activating mutations of FGFR3 have been reported to be involved in several cancers including bladder carcinoma (7), cervix carcinoma (7), oral squamous cell carcinoma (8), and colorectal carcinoma (9). The activation of FGFR3 signaling pathways in benign epidermal lesions, e.g., seborrhoeic keratosis (10, 11) and epidermal nevus (12), has been described previously. We also reported the activation of FGFR3 in seborrhoeic keratosis (13) and acanthosis nigricans (14). In addition, the transcriptional factor forkhead box N1 (FOXN1) has been identified as a downstream target of FGFR3 (15). The activation of FGFR3 induces the transcription of FOXN1, and FOXN1 also induces the transcription of FGFR3, indicating a positive feedback loop between FGFR3 and FOXN1 (15).

In this study, we first examined the presence of the fusion transcripts of *COL1A1-PDGFB* genes in DFSP to confirm the histological diagnosis. Next, in order to understand the involvement of FGFRs in the pathogenesis of seborrhoeic keratosis-like epidermal changes in DF and the tumor lesions of DF and DFSP, we investigated the expression of all 4 FGFRs (FGFR1, FGFR2, FGFR3, and FGFR4), some of their ligands (FGF1, FGF2, and FGF9), and FOXN1 in DF and DFSP by immunohistochemical analysis (16).

MATERIALS AND METHODS

Samples

Specimens of 20 DF, 6 DFSP, 11 seborrhoeic keratosis, and 20 normal skins were obtained with informed consent from patients who underwent resection at the Tokushima University Hospital.

RT-PCR analysis to detect the fusion transcripts of COL1A1-PDGFB genes

Tissue samples were from 6 cases of DFSP, which were diagnosed on the basis of histological findings and were positive for CD34 staining. Total RNA was extracted from frozen tissues using the RNeasy Mini Kit (Qiagen, Hilden, Germany), and reverse transcription was performed with random hexamers using the Omniscript RT kit (Qiagen). To detect the fusion transcripts of *COL1A1-PDGFB* genes, PCR was performed using 16 kinds of *COL1A1* forward primers and a specific *PDGFB* reverse primer according to the method of Wang *et al* (17). If obvious PCR products were obtained, these products were directly sequenced as previously reported (13).

Immunohistochemistry

An immunohistochemical investigation was performed as described previously (13). Sections were incubated with primary antibodies: a rabbit polyclonal anti-FGFR1 antibody (diluted 1 : 50, clone sc-405; Santa Cruz Biotechnology, Santa Cruz, CA, U.S.A.), a rabbit polyclonal anti-FGFR2 antibody (diluted 1 : 200, clone sc-20735; Santa Cruz Biotechnology, Santa Cruz, CA, U.S.A.), a mouse monoclonal anti-FGFR3 antibody (diluted 1 : 25, clone sc-13121; Santa Cruz Biotechnology, Santa Cruz, CA, U.S.A.), a rabbit polyclonal anti-FGFR4 antibody (diluted 1 : 100, clone sc-124; Santa Cruz Biotechnology, Santa Cruz, CA, U.S.A.), a goat polyclonal anti-FGF1 antibody (diluted 1 : 200, clone sc-1884; Santa Cruz Biotechnology, Santa Cruz, CA, U.S.A.), a rabbit polyclonal anti-FGF2 antibody (diluted 1 : 200, clone sc-79; Santa Cruz Biotechnology, Santa Cruz, CA, U.S.A.), a mouse monoclonal anti-FGF9 antibody (diluted 1 : 200, clone sc-8413; Santa Cruz Biotechnology, Santa Cruz, CA, U.S.A.), and a rabbit polyclonal anti-FOXN1 antibody (diluted 1 : 200, clone sc-30195; Santa Cruz Biotechnology, Santa Cruz, CA, U.S.A.) at 4°C overnight. After slides were washed in PBS, FGFR1, FGFR2, FGFR3, FGFR4, FGF2, FGF9, and FOXN1 were detected with the Envision+ kit (Dako, Kyoto, Japan) for 30 min. After further washing, immunoperoxidase staining was developed using a diaminobenzidine chromogen (Dako) followed by counterstaining with the Mayer's haematoxylin. After slides were washed in PBS, FGF1 was detected with an anti-goat streptavidin-biotin kit (Histofine SAB-PO (R); Nichirei, Tokyo, Japan), according to the

manufacturer's instructions. Sections were incubated in diaminobenzidine tetrahydrochloride until the desired staining was attained and counterstained with Mayer's haematoxylin. Immunoreactivity for FGFR1 in breast cancer, FGFR2 in the normal epidermis of skin, FGFR3 in the internal root sheath of hair follicles, FGFR4 and FGF1 in pancreatic cancer, FGF2 in colon cancer, FGF9 in lung cancer, and FOXN1 in seborrhoeic keratosis were regarded as positive controls, respectively. For the evaluation of the grade of immunoreactivity, the following scale was used: (-) negative (<5% positive cells); (+) weakly positive (5-24% positive cells); (++) moderately positive (25-50% positive cells); and (+++) strongly positive (>50% positive cells). Immunohistochemical analysis was performed by two doctors in a blind fashion, without knowledge of clinicopathological information.

Statistical analysis

The χ^2 test was used for examining the difference between DF and DFSP in immunoreactivity for each of FGFR2, FGFR3, FGFR4, FGF2, and FOXN1.

RESULTS

RT-PCR analysis to detect the fusion transcripts of COL1A1-PDGFB genes

The characteristics of 6 patients with DFSP are summarized in Table 1. The fusion transcripts of COL1A1-PDGFB genes were detected in all cases of DFSP, whose histological diagnosis was confirmed. RT-PCR analysis followed by sequence analysis revealed that each end of exons 25, 44, 47, 34, 2, and 17 of the COL1A1 gene were fused with the start of exon 2 of the PDGFB gene in each case of DFSP, respectively. For example, the end of exon 17 of the COL1A1 gene was fused with the start of exon 2 of the PDGFB gene in a sample from patient 6 (Figure 1).

Table 1. Summary of 6 patients with DFSP

Patients	Age/sex	Sites	CD34	COL1A1 breakpoints
1	38/M	Upper arm	+	Exon 25
2	25/F	Abdomen	+	Exon 44
3	84/F	Chest	+	Exon 47
4	29/M	Abdomen	+	Exon 34
5	43/M	Subclavicular	+	Exon 2
6	47/F	Abdomen	+	Exon 17

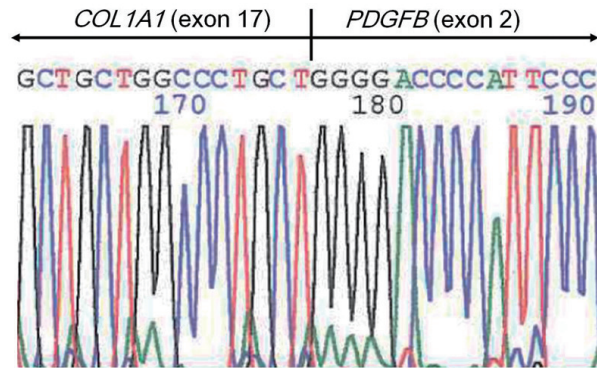


Figure 1. DNA sequencing. A fusion transcript of the end of exon 17 in the COL1A1 gene bound with the start of exon 2 in the PDGFB gene was identified.

Immunohistochemical analysis

Results of the immunohistochemistry analysis for FGFR2 and FGFR3 in epidermal regions of DF and DFSP are summarized in Table 2. All normal epidermis samples tested negative (-) to weakly positive (+) in the suprabasal to granular layer (data not shown). All cases of DF were moderately (++) to strongly positive (+++), and the expression of FGFR3 was shown to be strong in the basal layer; however, all cases of DFSP were negative to weakly positive (+) (Figure 2). The difference in FGFR3 expression between DF and DFSP was significant (Table 2). All normal epidermis samples were weakly positive (+) for FGFR2 (data not shown). Although 17 of 20 cases (85%) of DF were moderately positive (++) for FGFR2, the difference in FGFR2 expression between DF and DFSP was not significant (Table 2). Expression patterns of FGFR1 and FGFR4 in epidermal regions of DF and DFSP were similar to the normal epidermis (data not shown).

A summary of the expression of FOXN1 as a downstream target of FGFR3 in the epidermal regions of DF and DFSP, and seborrhoeic keratosis is shown in Table 2. Almost all normal skin samples were negative, and FOXN1 was localized to the nucleus in normal epidermis samples (data not shown). Seventeen of 20 cases (85%) of DF were moderately (++) to strongly positive (+++), and the expression of FOXN1 was shown to be strong in the basal layer (Figure 3). All cases of DFSP were negative (-) (Figure 3). Nine of 11 cases (82%) of seborrhoeic keratosis were strongly positive (+++), and the expression of FOXN1 was shown to be strong in the suprabasal to granular layer (Figure 3). The difference in FOXN1 expression between

Table 2. Summary of protein expression in the epidermal regions

Lesions	FGFR3 expression				FGFR2 expression				FOXN1 expression				Sum
	(-)	(+)	(++)	(+++)	(-)	(+)	(++)	(+++)	(-)	(+)	(++)	(+++)	
the epidermal regions of DF	0	0	5	15	0	3	17	0	0	3	2	15	20
the epidermal regions of DFSP	4	2	0	0	0	4	2	0	6	0	0	0	6
Seborrhoeic keratosis	-	-	-	-	-	-	-	-	0	0	2	9	11

In FGFR3 expression, DF vs DFSP : $P < 0.000001$; in FOXN1 expression, DF vs DFSP : $P < 0.000001$. The differences between DF and DFSP in FGFR2 expression were not statistically significant ($P > 0.05$). (-), < 5% positive cells ; (+), 5-24% ; (++) , 25-50% ; (+++) , > 50%.

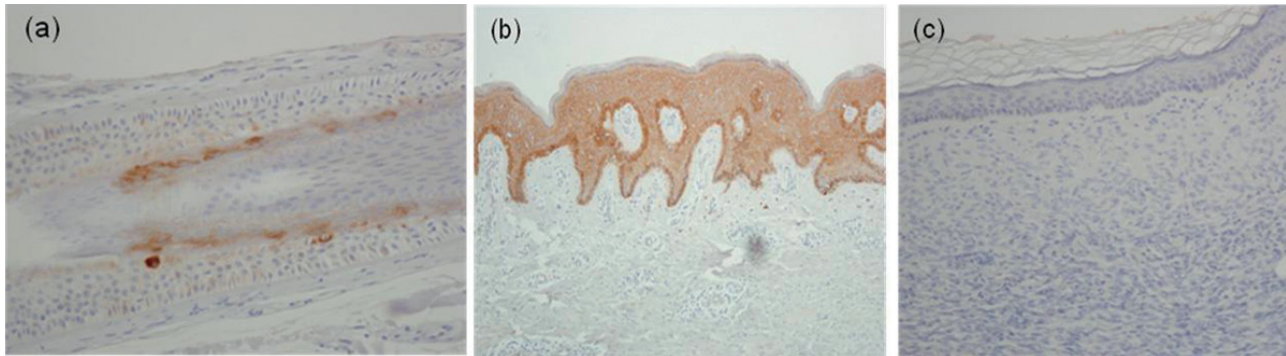


Figure 2. Immunohistochemical staining for FGFR3. Typical images of FGFR3 staining in the internal root sheath of a hair follicle (a), dermatofibroma (DF) (b), and dermatofibrosarcoma protuberans (DFSP) (c). (a) Cytoplasm and cell membrane of the internal root sheath of hair follicles were regarded as a positive control. (b) Strongly positive (+++) staining for FGFR3 in DF. FGFR3 expression was strong in the basal layer. (c) Negative (-) staining for FGFR3 in DFSP.

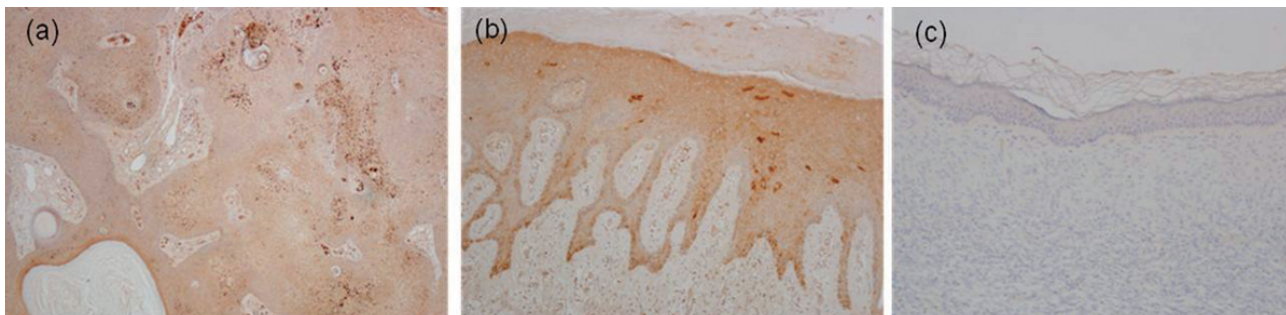


Figure 3. Immunohistochemical staining for FOXN1. Typical images of FOXN1 staining in seborrhoeic keratosis (a), DF (b), and DFSP (c). (a) Seborrhoeic keratosis was regarded as a positive control. FOXN1 expression was strong in the suprabasal to granular layer. (b) Strongly positive (+++) staining for FOXN1 in DF. FOXN1 expression was strong in the basal layer. (c) Negative (-) staining for FOXN1 in DFSP.

DFSP and DF was significant (Table 2).

Results of the analysis for FGFR4 in the tumor lesions of DF and DFSP are shown in Table 3. All normal dermis samples were negative (-). Sixteen of 20 cases (80%) of DF were moderately (++) to strongly positive (+++), while all cases of DFSP were negative (-) to weakly positive (+) (Figure 4). The difference in FGFR4 expression between DF and DFSP was significant (Table 3). On the other hand, expressions for FGFR1, FGFR2, and FGFR3 were negative (-) in the tumor lesions of DF and DFSP as well as normal dermis samples (data not shown).

Results of the analysis for FGF2 in the tumor lesions of DF and DFSP are shown in Table 3. All normal dermis samples were negative (-). All cases of DF were moderately (++) to strongly positive (+++), while 5 of 6 cases (83%) of DFSP were negative (-) to weakly positive (+) (Figure 5). The difference in FGF2 expression between DF and DFSP was significant (Table 3). Expressions of FGF1 and FGF9 were negative (-) in the epidermal and dermal regions of DF and DFSP as well as normal skin, and expression patterns of FGF2 in the epidermal regions of DF and DFSP were similar to normal epidermis samples (data not shown).

Table 3. Summary of protein expression in the tumor lesions

Lesions	FGFR4 expression				FGF2 expression				Sum
	(-)	(+)	(++)	(+++)	(-)	(+)	(++)	(+++)	
the tumor lesions of DF	0	4	8	8	0	0	7	13	20
the tumor lesions of DFSP	2	4	0	0	2	3	1	0	6

In FGFR4 expression, DF vs DFSP : $P < 0.00000001$; in FGF2 expression, DF vs DFSP : $P < 0.000000001$. (-), $< 5\%$ positive cells ; (+), 5-24% ; (++) , 25-50% ; (+++) , $> 50\%$.

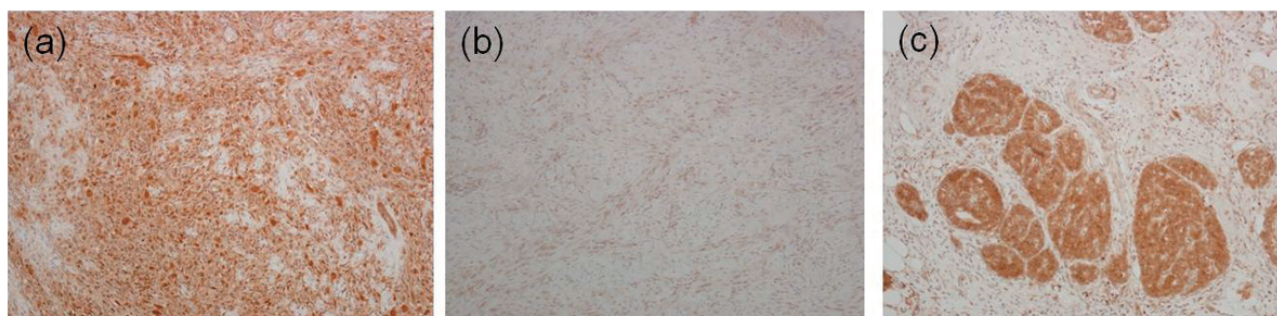


Figure 4. Immunohistochemical staining for FGFR4. Typical images of FGFR4 staining in DF(a), DFSP(b), and a pancreatic cancer (c). (a) Strongly positive (+++) staining for FGFR4 in DF. (b) Negative (-) staining for FGFR4 in DFSP. (c) A pancreatic cancer was regarded as a positive control.

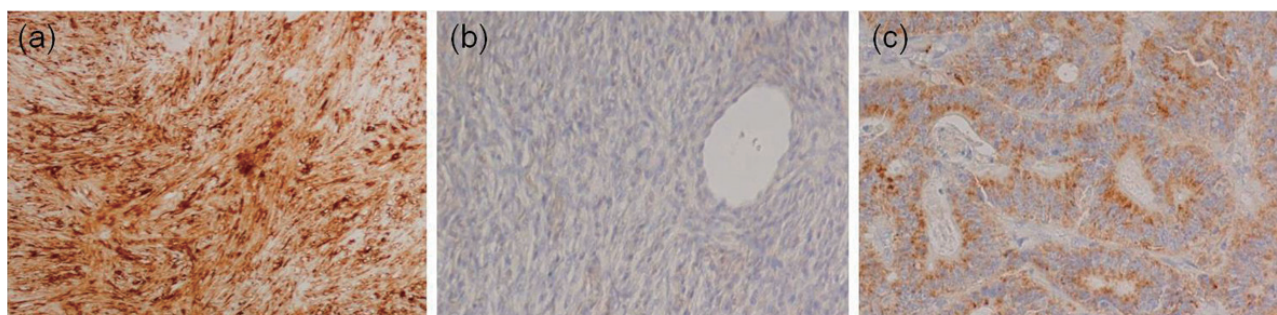


Figure 5. Immunohistochemical staining for FGF2. Typical images of FGF2 staining in DF (a), DFSP (b), and a colon cancer (c). (a) Strongly positive (+++) staining for FGF2 in DF. (b) Negative (-) staining for FGF2 in DFSP. (c) A colon cancer was regarded as a positive control.

DISCUSSION

Transmembrane tyrosine kinase receptors of FGFRs consist of FGFR1, FGFR2, FGFR3, and FGFR4, and the activation of each of the FGFR signaling pathways has been reported to be observed in several kinds of cancers (18). Among them, the activation of FGFR3 signaling pathways in benign epidermal lesions including seborrheic keratosis (10, 11, 13), epidermal nevus (12), and acanthosis nigricans (14) has been reported. In this study, the epidermal regions of DF were moderately (++) to strongly positive (+++), and the expression of FGFR3 was shown to be strong in the basal layer (Figure 2). On the other hand, no expression

of FGFR3 was seen in the epidermal regions of DFSP. The epidermal regions of DF were similar to seborrheic keratosis both in terms of histological features and the molecular characteristics of overexpression of FGFR3. We believe that overexpression of FGFR3 may contribute to the development of epidermal changes in DF.

In previous studies, the roles of FGFR2 (6) and EGF/EGFR (19) were proposed for the induction of epidermal hyperplasia in the epidermal regions of DF. We also showed that the expression of FGFR2 was moderately positive (++) in 17 of 20 epidermal regions (85%) of DF. However, the difference in FGFR2 expression between DF and DFSP was not significant (Table 2). We suppose that FGFR3 may

be more relevant to the induction of epidermal hyperplasia in the epidermal regions of DF than FGFR2. Han K-H *et al.* demonstrated that the expression of EGFR is equally distributed throughout the epidermis overlying DF, suggesting an etiologic factor of EGF/EGFR in the induction of epidermal hyperplasia (19). As EGFR and FGFR3 are both transmembrane tyrosine kinase receptors (TKRs) and are located upstream of the RAS/ a mitogen-activated protein kinase (MAPK) pathway (20), the activation of FGFR3 may also contribute to RAS/ MAPK pathways in the epidermal regions of DF.

Crosstalk between fibroblasts and keratinocytes via a variety of cytokines and their receptors has been proposed for the induction of epidermal hyperplasia in the epidermis overlying DF (21). Therefore, we examined the expression of FGF1 and FGF9, both of which are specific ligands for b isoform of FGFR3 (FGFR3b) expressed in epithelial tissues, in the tumor lesions of DF (8, 16). However, we failed to detect the expression of FGF1 and FGF9 in the epidermal and dermal regions of DF by immunohistochemical analysis. We could not prove crosstalk between fibroblasts and keratinocytes via these ligands and FGFR3.

Next, we examined the expression of FOXN1 in the epidermal regions of DF and DFSP, and seborrhoeic keratosis. Almost all normal skin samples tested negative, and FOXN1 was localized to the nucleus in normal epidermis samples as previously reported (22). We also confirmed the expression of FOXN1 in seborrhoeic keratosis as previously reported (15), and the expression of FOXN1 was shown to be strong in the suprabasal to granular layer. Strong expression of FOXN1 was also observed in the epidermal regions of DF, and the expression of FOXN1 was shown to be strong in the basal layer. On the other hand, expression was negative (-) to weakly positive (+) in the epidermal regions of DFSP. Although we cannot understand the difference in the distribution of FGFR3 expression between seborrhoeic keratosis and the epidermal regions of DF, a positive feedback loop between FGFR3 and FOXN1 for affecting the proliferation and differentiation of epidermal keratinocytes must be formed in the epidermal regions of DF as well as seborrhoeic keratosis. Since epidermal changes in DF must be not neoplastic but reactive, there would be no possibility that the epidermal regions of DF harbor somatic activating mutations of the *FGFR3* gene as we previously found in seborrhoeic keratosis (13). Unknown mechanisms rather than

activating mutations of the *FGFR3* gene or overexpression of ligands for FGFR3 may exist for turning on a positive feedback loop between FGFR3 and FOXN1.

In addition to the proliferation and differentiation of epidermal keratinocytes, FOXN1 has been reported to be involved in pigmentation of the epidermis (23). Hyperpigmentation in the basal layer is generally seen in the epidermal regions of DF. Overexpression of FOXN1 in epidermal keratinocytes may promote melanogenic stimulation in adjacent epidermal melanocytes, inducing hyperpigmentation in the basal layer of the epidermal regions of DF. Previously, Shishido E *et al.* proposed an important role for fibroblastic tumor cell-derived stem cell factor (SCF) in the pathogenesis of epidermal hyperpigmentation in DF (24). Since SCF derived from human fibroblasts regulates cutaneous pigmentation, FOXN1 may have different physiological effects from SCF.

We showed strong expressions of FGF2 and FGFR4 in the tumor lesions of DF, while FGF2 and FGFR4 were negative in the tumor lesions of DFSP. FGF2, which is a ligand for all four FGFRs, has been reported to be involved in the invasion of cancer cells and proliferation of fibroblasts around cancer cells in an autocrine or paracrine fashion (25). As for FGFR4, the activation of FGFR4 signaling pathways has been observed in several kinds of cancers including hepatocellular carcinomas, breast cancers, and lung cancers (18). In addition, activating mutations of the *FGFR4* gene have also been identified in rhabdomyosarcomas, which are pediatric sarcomas arising from skeletal muscle (26). Overexpression of both FGFR4 and one of its ligand, FGF2, may contribute to the development of the benign tumor lesions of DF through the proliferation of fibroblasts in an autocrine or paracrine fashion. The degree to which overexpression of FGF2/FGFR4 is involved in the pathogenesis of DF needs further investigation.

In conclusion, overexpression of FGFR3/FOXN1 in the epidermal regions of DF and FGF2/FGFR4 in the tumor lesions of DF was observed. These expression patterns were in contrast with those of cases of DFSP, whose diagnoses were confirmed by the presence of the fusion transcripts of *COL1A1-PDGFB* genes. The activation of FGFR signaling pathways may be not only relevant to the pathogenesis of DF, but also very useful in the differential diagnosis of DF and DFSP.

CONFLICTS OF INTEREST

None of the authors have any conflicts of interest to declare.

ACKNOWLEDGEMENTS

This work was supported in part by grants from the Ministry of Education, Culture, Sports, Science, and Technology of Japan.

REFERENCES

1. Heenan PJ : Tumors of the fibrous tissue involving the skin. *Lever's Histopathology of the Skin*, 8th edition. 847-887, 1997
2. Goldblum JR, Tuthill RJ : CD34 and factor-XIIIa immunoreactivity in dermatofibrosarcoma protuberans and dermatofibroma. *Am J Dermatopathol* 19 : 147-153, 1997
3. Simon MP, Pedeutour F, Sirvent N, Grosgeorge J, Minoletti F, Coindre JM, Terrier-Lacombe MJ, Mandahl N, Craver RD, Blin N, Sozzi G, Turc-Carel C, O'Brien KP, Kedra D, Fransson I, Guilbaud C, Dumanski JP : Deregulation of the platelet-derived growth factor B-chain gene via fusion with collagen gene COL1A1 in dermatofibrosarcoma protuberans and giant-cell fibroblastoma. *Nat Genet* 15 : 95-98, 1997
4. Sirvent N, Maire G, Pedeutour F : Genetics of dermatofibrosarcoma protuberans family of tumors : from ring chromosomes to tyrosine kinase inhibitor treatment. *Genes Chromosomes Cancer* 37 : 1-19, 2003
5. Turner N, Grose R : Fibroblast growth factor signalling : from development to cancer. *Nature Rev Cancer* 10 : 116-129, 2010
6. Skroza N, Rotolo S, Ceccarelli S, Romano F, Innocenzi D, Frati L, Angeloni A, Marchese C : Modulation of the expression of the FGFR2-IIIb and FGFR2-IIIc molecules in dermatofibroma. *J Dermatol Sci* 51 : 53-57, 2008
7. Cappellen D, De Oliveira C, Ricol D, de Medina S, Bourdin J, Sastre-Garau X, Chopin D, Thiery JP, Radvanyi F : Frequent activating mutations of FGFR3 in human bladder and cervix carcinomas. *Nat Genet* 23 : 18-20, 1999
8. Zhang Y, Hiraishi Y, Wang H, Sumi KS, Hayashido Y, Toratani S, Kan M, Sato JD, Okamoto T : Constitutive activating mutation of the FGFR3b in oral squamous cell carcinoma. *Int J Cancer* 117 : 166-168, 2005
9. Jang JH, Shin KH, Park JG : Mutation in fibroblast growth factor receptor 2 and fibroblast growth factor receptor 3 genes associated with human gastric and colorectal cancers. *Cancer Res* 61 : 3541-3543, 2001
10. Logié A, Dunois-Lardé C, Rosty C, Levrel O, Blanche M, Ribeiro A, Gasc JM, Jorcano J, Werner S, Sastre-Garau X, Thiery JP, Radvanyi F : Activating mutations of tyrosine kinase receptor FGFR3 are associated with benign skin tumors in mice and humans. *Hum Mol Genet* 14 : 1153-1160, 2005
11. Hafner C, Hartmann A, van Oers JM, Stoehr R, Zwarthoff EC, Hofstaedter F, Landthaler M, Vogt T : FGFR3 mutations in seborrheic keratoses are already present in flat lesions and associated with age and localization. *Mod Pathol* 20 : 895-903, 2007
12. Hafner C, van Oers JM, Vogt T, Landthaler M, Stoehr R, Blaszyk H, Hofstaedter F, Zwarthoff EC, Hartmann A : Mosaicism of activating FGFR3 mutations in human skin causes epidermal nevi. *J Clin Invest* 116 : 2201-2207, 2006
13. Hida Y, Kubo Y, Arase S : Activation of fibroblast growth factor receptor 3 and oncogene-induced senescence in skin tumours. *Br J Dermatol* 160 : 1258-1263, 2009
14. Hida Y, Kubo Y, Nishio Y, Murakami S, Fukumoto D, Sayama K, Hashimoto K, Arase S : Malignant acanthosis nigricans with enhanced expression of fibroblast growth factor receptor 3. *Acta Derm Venereol* 89 : 435-437, 2009
15. Mandinova A, Kolev V, Neel V, Hu B, Stonely W, Lieb J, Wu X, Colli C, Han R, Pazin MJ, Ostano P, Dummer R, Brissette JL, Dotto GP : A positive FGFR3/FOXN1 feedback loop underlies benign skin keratosis versus squamous cell carcinoma formation in humans. *J Clin Invest* 119 : 3127-3137, 2009
16. Eswarakumar VP, Lax I, Schlessinger J : Cellular signaling by fibroblast growth factor receptors. *Cytokine Growth Factor Rev* 16 : 139-149, 2005
17. Wang J, Hisaoka M, Shimajiri S, Morimitsu Y, Hashimoto H : Detection of COL1A1-PDGFB fusion transcripts in dermatofibrosarcoma protuberans by reverse transcription-polymerase chain reaction using archival formalin-fixed, paraffin-embedded tissues. *Diagn Mol Pathol*

- 8 : 113-119, 1999
18. Haugsten EM, Wiedlocha A, Olsnes S, Wesche J : Roles of fibroblast growth factor receptors in carcinogenesis. *Mol Cancer Res* 8 : 1439-1452, 2010
 19. Han KH, Huh CH, Cho KH : Proliferation and differentiation of the keratinocytes in hyperplastic epidermis overlying dermatofibroma. *Am J Dermatopathol* 23 : 90-98, 2001
 20. Torley D, Bellus GA, Munro CS : Genes, growth factors and acanthosis nigricans. *Br J Dermatol* 147 : 1096-1101, 2002
 21. Yamamoto T : Dermatofibroma : a possible model of local fibrosis with epithelial/mesenchymal cell interaction. *J Eur Acad Dermatol Venereol* 23 : 371-375, 2009
 22. Prowse DM, Lee D, Weiner L, Jiang N, Magro CM, Baden HP, Brissette JL : Ectopic expression of the nude gene induces hyperproliferation and defects in differentiation : implications for the self-renewal of cutaneous epithelia. *Dev Bio* 212 : 54-67, 1999
 23. Weiner L, Han R, Scicchitano BM, Li J, Hasegawa K, Grossi M, Lee D, Brissette JL : Dedicated epithelial recipient cells determine pigmentation patterns. *Cell* 130 : 932-942, 2007
 24. Shishido E, Kadono S, Manaka I, Kawashima M, Imokawa G : The mechanism of epidermal hyperpigmentation in dermatofibroma is associated with stem cell factor and hepatocyte growth factor expression. *J Invest Dermatol* 117 : 627-633, 2001
 25. Hase T, Kawashiri S, Tanaka A, Nozaki S, Noguchi N, Kato K, Nakaya H, Nakagawa K, Yamamoto E : Fibroblast Growth Factor-2 Accelerates Invasion of Oral Squamous Cell Carcinoma. *Oral Science International* : 1-9, 2006
 26. Taylor JG 6th, Cheuk AT, Tsang PS, Chung JY, Song YK, Desai K, Yu Y, Chen QR, Shah K, Youngblood V, Fang J, Kim SY, Yeung C, Helman LJ, Mendoza A, Ngo V, Staudt LM, Wei JS, Khanna C, Catchpoole D, Qualman SJ, Hewitt SM, Merlino G, Chanock SJ, Khan J : Identification of FGFR4-activating mutations in human rhabdomyosarcomas that promote metastasis in xenotransplanted models. *J Clin Invest* 119 : 3395-3407, 2009