

CASE REPORT

Huge retroperitoneal dedifferentiated liposarcoma presented as acute pancreatitis : Report of a case

Yusuke Arakawa¹, Kazuo Yoshioka^{1,4}, Hitomi Kamo¹, Koichiro Kawano³, Takeshi Yamaguchi¹, Yuko Sumise¹, Natsu Okitsu¹, Shizuo Ikeyama², Kojiro Morimoto¹, Yoshihiro Nakai¹, and Seiki Tashiro^{1,5}

¹Department of Surgery, Taoka Hospital, ²Department of Radiology, Taoka Hospital, ³Department of Digestive Endoscopy, Taoka Hospital, 4-2-2 Bandai-cho, Tokushima 770-0941, JAPAN, ⁴Clinical professor, department of digestive and transplantation surgery, the University of Tokushima graduate school, ⁵Professor Emeritus of the University of Tokushima graduate school

Abstract : A 74-year-old male with abdominal pain was admitted to the emergency room in our hospital. The high value of serum amylase was shown in his blood test. The post-contrast computed tomography (CT) showed the huge retroperitoneal tumor with a thin-walled mass occupying most of the part of the right retroperitoneal space. The tumor spread into the soft tissues around the pancreas; as a result, the duodenum was compressed and the pancreas was displaced to the right side. The irregular pancreatic outline, obliterated peripancreatic fatty tissue and fluid in the left anterior pararenal space were revealed, so acute pancreatitis was diagnosed. The diagnostic biopsy of retroperitoneal tumor was done, and the pathological findings of retroperitoneal mass revealed dedifferentiated liposarcoma. The medical treatment against acute pancreatitis was performed firstly. After the patient recovered from that, the surgical resection of the tumor with the right kidney and right adrenal gland was completed successfully. The patient remained well, without any evidence of recurrence three months after surgery. However, the histology showed dedifferentiated liposarcoma; therefore, postoperative regular examination is necessary. *J. Med. Invest.* 60 : 164-168, February, 2013

Keywords : retroperitoneal tumor, liposarcoma, acute pancreatitis

INTRODUCTION

Retroperitoneal liposarcoma was a rare tumor which represents 10 to 15% of all soft-tissue sarcomas, and the annual incidences are estimated at 2.5 per million population and accounts for approximately 20 percent of all retroperitoneal sarcomas

Received for publication November 8, 2012; accepted January 28, 2013.

Address correspondence and reprint requests to Yusuke Arakawa, MD, Staff Surgeon, Department of Surgery, Taoka Hospital, 4-2-2 Bandai-cho, Tokushima 770-0941, JAPAN and Fax : +81-88-655-3077.

(1). No specific etiological association has been identified. This tumor usually originated from the peritoneal fatty tissues, occupied abdominal space and showed a typical appearance on a computed tomography (CT) or magnetic resonance image (MRI) (2). Most common symptom of retroperitoneal liposarcoma is abdominal distention. Patients with this tumor notice gradual abdominal enlargement over many years. This report presents an extremely rare case of the man with huge retroperitoneal dedifferentiated liposarcoma and development of acute pancreatitis.

CASE REPORT

A 74-year-old male, with no significant medical or social history, was referred to our hospital for urgent abdominal pain and severe abdominal distention. Laboratory studies at referral included leukocytes count 119,00 /mm³, hemoglobin 13.7 g/dl, platelet count 37.8x10³ /mm³, albumin 4.2 g/dl, total bilirubin (T-BIL) 0.4 mg/dl, aspartate transaminase (AST) 41 IU/l, alanine transaminase (ALT) 16 IU/l, γ -glutamyl transpeptidase (γ -GTP) 57 IU/l, alkaline phosphatase (ALP) 292 U/l, amylase 898 IU/l, negative Hepatitis B surface and envelope antigens, and negative hepatitis C antibody, carcinoembryonic antigen (CEA) 1.4 ng/ml, carbohydrate antigen 19-9 (CA19-9) 29.8 U/ml, and neuron-specific enolase (NSE) 5.4 ng/ml. The CT showed a huge right sided retroperitoneal heterogeneous mass which was composed of a large part of the

radiolucent fatty component and several dense solid components enhanced with intravenous contrast containing central part without enhancement (Fig 1a). Axial T1-weighted MRI also demonstrated fatty component with high intensity signal and several solid components which contained solid part (Fig 1b). The tumor spread into the soft tissues around the pancreas. The irregular pancreatic outline and obliterated peripancreatic fatty tissue were revealed (Fig 1c). The duodenum was compressed and the pancreas was displaced to the right side. The fluid in the left anterior pararenal space was shown (Fig 1d), so acute pancreatitis which was graded as Grade 3 according to the Japanese guidelines for acute pancreatitis was diagnosed (3). The right side kidney and adrenal gland were also rotated and displaced upward and forward with normal patent renal vessels and without pelviureteric obstruction significantly.

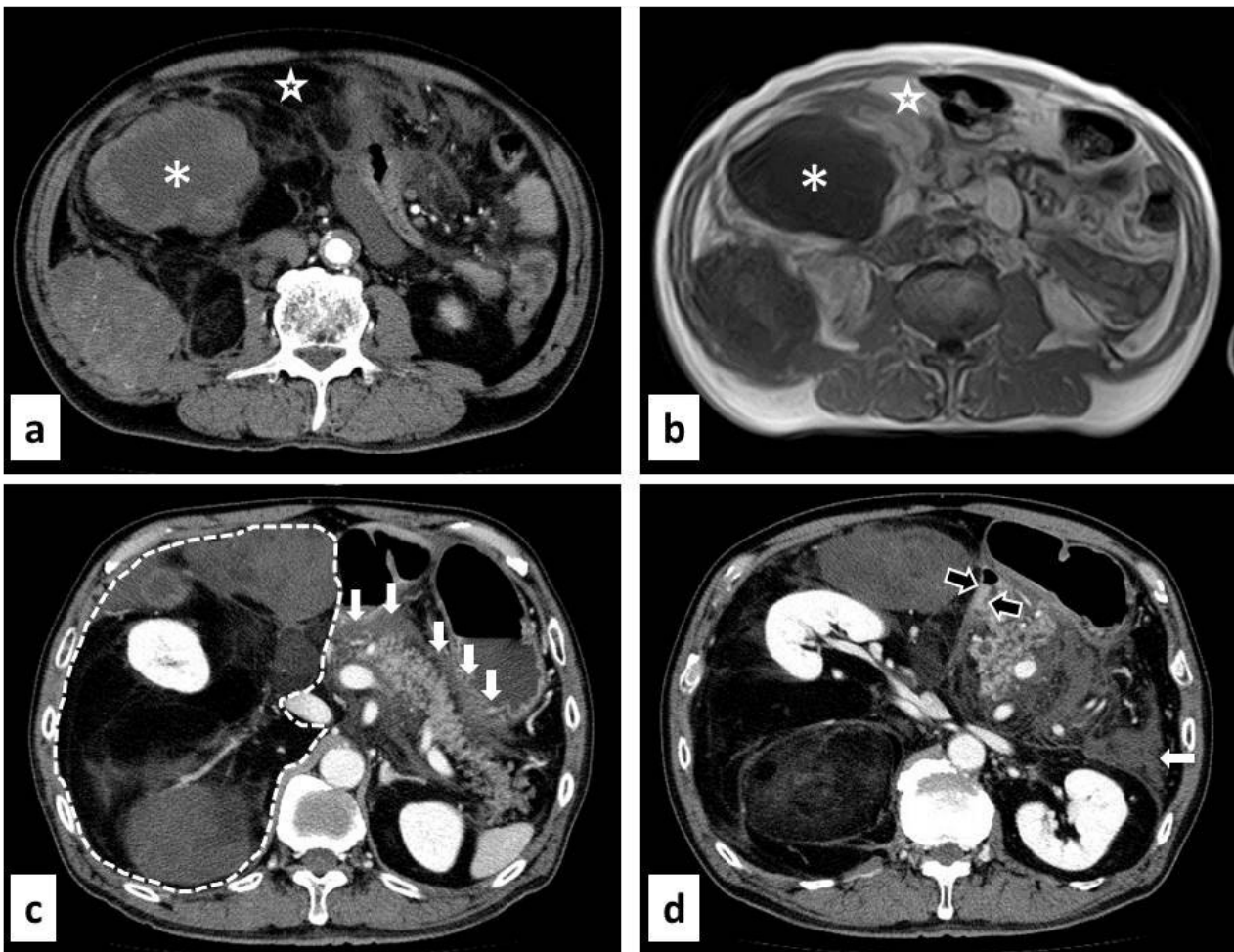


Fig 1a-d. Finding of imaging modalities. a Enhanced computed tomography (CT) showed radiolucent fatty component (star) and several dense solid components enhanced with intravenous contrast containing central no enhancing part (asterisk). b Axial T1-weighted magnetic resonance image demonstrated fatty component (star) with high intensity signal and several solid components which contained dedifferentiated part (asterisk). c Enhanced CT showed a huge tumor lesion, occupying right abdominal space (dotted line), the irregular pancreatic outline, obliterated peripancreatic fatty tissue (arrow). d Enhanced CT showed the duodenum was compressed by tumor (unfilled arrow) and the fluid in the left anterior pararenal space (arrow).

The diagnostic biopsy guided with ultrasonography of retroperitoneal tumor was done, and the pathological findings of retroperitoneal mass revealed high grade round cell sarcoma. The result of the immunohistochemical staining was compatible for liposarcoma; vimentin (+), desmin (+), CAM5.2 (-), EMA (-), LCA (-), L26 (-), UCHL-1 (-), S100 (-), CD99 (-), HHF35 (-), SMA (+) and myoglobin (-).

The medical treatment against acute pancreatitis was done firstly with antibiotics and the inhibitor for pancreatic enzyme. After the patient recovered from that, the surgical resection of the tumor with the right kidney and the right adrenal gland through a full-length right pararectal incision with subcostal arch incision was done successfully en bloc. In the operative findings, the huge retroperitoneal tumor displaced the right colon anteriorly and medially and compressed the duodenum. The tumor extended along the peripancreatic space. The mass measured twenty by thirty-four centimeters and 4.3 kilograms. This tumor contained soft yellow fat-like part and firm whitish part (Fig 2). Microscopically, the tumor was composed of bizarre cells (Fig 3a). The tumor cells were positive for vimentin staining (Fig 3b) desmin staining (Fig 3c) and alpha smooth muscle actin staining (Fig 3d). The postoperative pathological diagnosis showed dedifferentiated liposarcoma. The postoperative course

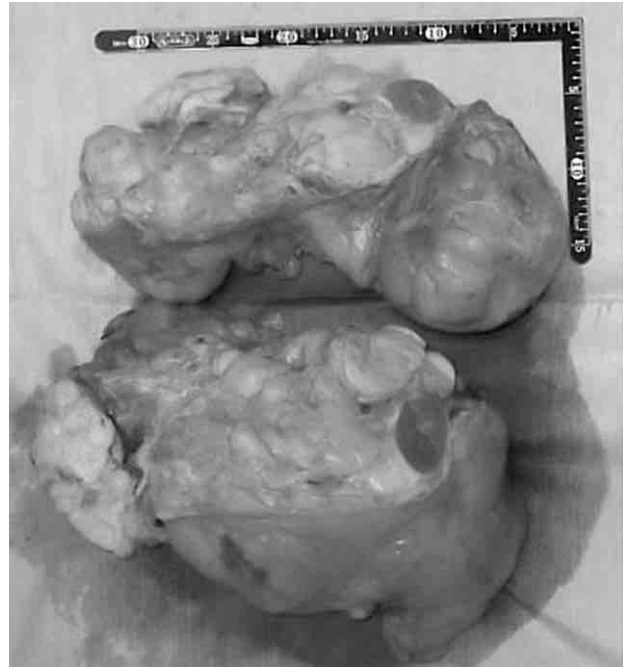

Fig. 2. Macroscopic findings of the tumor. The mass measured twenty by thirty-four centimeters and 4.3 kilograms. Cut surface of the tumor, showing soft yellow fat-like part and firm whitish part.

was uneventful, and the patient was discharged thirty-one days later. The patient remained well, without any evidence of recurrence three months after surgery. However, the histology showed dedifferentiated liposarcoma; therefore, postoperative regular examination is necessary.

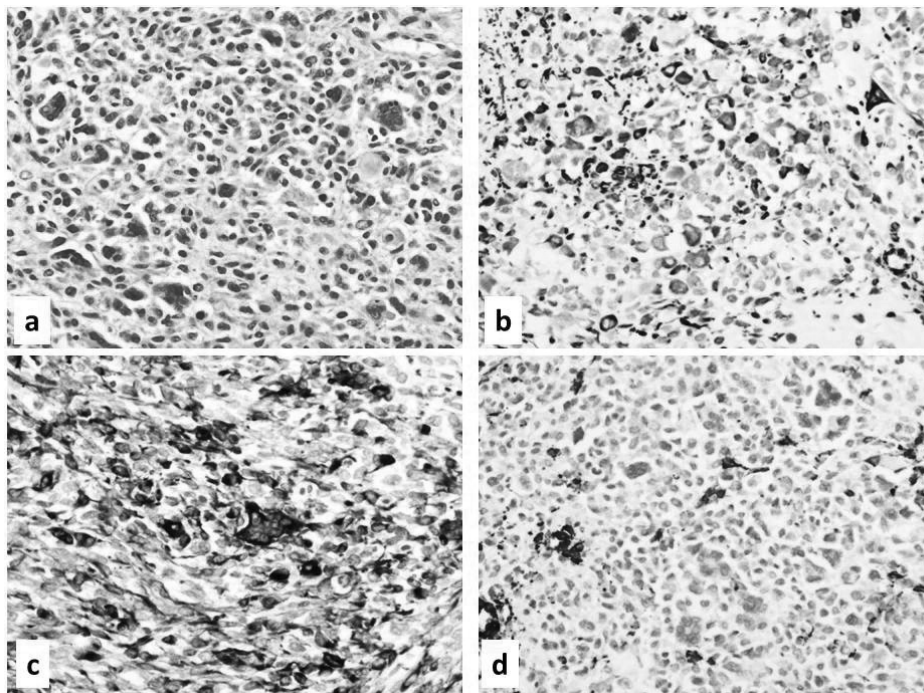


Fig. 3. Microscopic findings of the tumor. Tumor is composed of bizarre cells with mitosis in the nucleus (a, H&E, x200). The vimentin, desmin and alpha smooth muscle actin stainings were positive in the tumor, suggesting smooth muscle origin. (b: vimentin, c: desmin, d: alpha smooth muscle actin, x200).

DISCUSSION

Liposarcoma is one of the most common soft tissue sarcoma. Tumors are currently classified into three groups : well differentiated liposarcoma with or without dedifferentiation, myxoid and round cell/cellular myxoid liposarcoma, and pleomorphic liposarcoma. Dedifferentiated liposarcoma is originally defined as the existence of a high-grade, non-lipogenic sarcoma (4).

In liposarcoma, high-grade tumors (dedifferentiated liposarcoma) are significantly associated with an increased risk of local recurrence (2, 4-6). Chemotherapy and radiotherapy have not been recommended because of little evidence. So the surgical resection is the only effective treatment option. The rate of complete resection for primary tumor is 80% (5). Resection of adjacent structure is required in 57% to 77% of cases to achieve complete resection of the tumor (2, 5). Even the palliative resection is worthwhile to treat troublesome symptoms of recurrence (2). Distant metastases are uncommon, occurring in 5% of cases, while most patients die of local tumor. The negative margins of surgical resection are associated with overall survival and disease free survival, while the roles of adjuvant chemotherapy remain controversial (2, 4-6).

The imaging appearance is frequently sufficiently characteristics to allow specific diagnosis in retroperitoneal liposarcoma (1, 4). However, patients with retroperitoneal liposarcoma reveals very slow progressive abdominal distention, so some gastrointestinal or genitourinary symptoms are rare. The clinical presentation is nonspecific and often absent until last stage of evolution. Even the diameter of tumor is more than 20 cm, only 34% of patients with dedifferentiated liposarcoma and 18% of patients with well differentiated liposarcoma experienced pain (7). The poor prognosis of retroperitoneal liposarcoma is explained by their volume and the proximity to large blood vessels and renal tractus, which leads to incomplete resection. Therefore, early detection is necessary for curative surgical resection (2).

The current case revealed severe abdominal pain as a manifestation of acute pancreatitis. The huge tumor might lead to an obstruction of the ampulla and acute pancreatitis. The similar situation has been reported due to the other causes such as duodenal web, annular pancreas and duodenal cancer. Annular pancreas is also a rare congenital anomaly due to an embryologic migration fault (8). Duodenal

webs are rare clinical entity, they are a well-recognized developmental anomaly causing duodenal obstruction in infants, necessitating surgical intervention in order to restore gastrointestinal patency (9).

We were unable to find a similar case in the literature in "PubMed" using "pancreatitis" and "retroperitoneal liposarcoma" as key words. So this was the first case that acute pancreatitis appeared due to the massive growth and invasion of retroperitoneal liposarcoma.

CONFLICT OF INTEREST STATEMENT

Yusuke Arakawa and other co-authors have no conflict of interest.

REFERENCES

- Peterson JJ, Kransdorf MJ, Bancroft LW, O'Connor MI : Malignant fatty tumors : classification, clinical course, imaging appearance and treatment. *Skeletal Radiol* 32 : 493-503, 2003
- Neuhaus SJ, Barry P, Clark MA, Hayes AJ, Fisher C, Thomas JM : Surgical management of primary and recurrent retroperitoneal liposarcoma. *Br J Surg* 92 : 246-252, 2005
- Takeda K, Yokoe M, Takada T, Kataoka K, Yoshida M, Gabata T, *et al* : Assessment of severity of acute pancreatitis according to new prognostic factors and CT grading. *J Hepatobiliary Pancreat Sci* 17 : 37-44, 2010
- Tateishi U, Hasegawa T, Beppu Y, Satake M, Moriyama N : Primary dedifferentiated liposarcoma of the retroperitoneum. Prognostic significance of computed tomography and magnetic resonance imaging features. *J Comput Assist Tomogr* 27 : 799-804, 2003
- Lewis JJ, Leung D, Woodruff JM, Brennan MF : Retroperitoneal soft-tissue sarcoma : analysis of 500 patients treated and followed at a single institution. *Ann Surg* 228 : 355-365, 1998
- Singer S, Antonescu CR, Riedel E, Brennan MF : Histologic subtype and margin of resection predict pattern of recurrence and survival for retroperitoneal liposarcoma. *Ann Surg* 238 : 358-370 ; discussion 370-351, 2003
- Fabre-Guillevin E, Coindre JM, Somerhausen Nde S, Bonichon F, Stoeckle E, Bui NB : Retroperitoneal liposarcomas : follow-up analysis of

- dedifferentiation after clinicopathologic reexamination of 86 liposarcomas and malignant fibrous histiocytomas. *Cancer* 106 : 2725-2733, 2006
8. Jarry J, Wagner T, Rault A, Sa Cunha A, Collet D : Annular pancreas : a rare cause of acute pancreatitis. *JOP* 12 : 155-157, 2011
 9. Lytras D, Olde-Damink SW, Imber CJ, Hatfield A, Amin Z, Malago M : Duodenal web in an adult presenting with acute pancreatitis and acquired megaduodenum : report of a case. *Surg Today* 41 : 426-429, 2011