

ORIGINAL**Magnetic resonance imaging in adolescent symptomatic navicular tuberosity**

Mitsuhiko Takahashi¹, Toshinori Sakai¹, Koichi Sairyo¹, Shoichiro Takao², Seiichi Mima³, and Natsuo Yasui¹

¹Department of Orthopaedics and ²Department of Radiologic Science, the Institute of Health Biosciences, the University of Tokushima, Tokushima, Japan and ³Suihou-Daiichi Hospital, Minami-Awaji, Japan

Abstract : *Background* The accessory navicular bone is one of the most common accessory ossicles, which sometimes become symptomatic. Abnormalities in magnetic resonance (MR) image, e.g. edema-like bone marrow pattern, have been reported for symptomatic accessory navicular. However, it has not been completely understood the edema-like bone marrow pattern correlates to the symptom of navicular tuberosity. *Methods* We investigated the edema-like bone marrow pattern in correlation with alleviation of the symptom and the presence of accessory navicular bone. Ten adolescents with pain localized to the navicular tuberosity were recruited and seven cases were further examined with consecutive MR images. *Results* Edema-like bone marrow pattern was found in all symptomatic navicular but not in asymptomatic navicular. Intensity of the pattern diminished with alleviation of the symptom. Moreover, this correlation was recognized even in the patients who had no accessory navicular bones. *Conclusions* MR images could be used not only for diagnosis but for monitor of healing in adolescent symptomatic navicular. There may be different pathologic mechanism for adolescent symptomatic navicular tuberosity, such as an osteitis, in adolescents. *J. Med. Invest.* 61 : 22-27, February, 2014

Keywords : *accessory navicular, magnetic resonance image, edema-like bone marrow pattern, adolescents*

INTRODUCTION

The accessory navicular bone, which is also termed “os tibiale externum”, is one of the most common accessory ossicles, with a reported incidence of ~10-26% (1-3). As most accessory navicular bones are asymptomatic, they are often erroneously considered as normal anatomic and roentgenographic variants. However, they can become

symptomatic when trauma affects the synchondrosis of the accessory navicular. The symptomatic condition is mainly associated with type II accessory navicular bone, in which there is a large, triangular ossification center adjacent to the navicular tuberosity that is connected by a synchondrosis measuring 1-3 mm (4, 5). This type of accessory navicular bone can be easily distinguished from type I accessory navicular bone which is a sesamoid imbedded in the tibialis posterior tendon and separated from the navicular tuberosity by at least 3 mm (5-7). The cause of symptom is thought to be repetitive tension and shear stress across the synchondrosis as a result of the pull of the posterior tibial tendon (8).

Recently, it has been reported that magnetic

Received for publication June 24, 2013 ; accepted August 8, 2013.

Address correspondence and reprint requests to Mitsuhiko Takahashi, MD, PhD, Department of Orthopaedics, the Institute of Health Biosciences, the University of Tokushima, 3-18-15 Kuramoto, Tokushima 770-8503, Japan and Fax : +81-88-633-0178.

resonance (MR) images of symptomatic type II (synchondrosis type) accessory navicular bone showed an “edema-like bone marrow pattern” (9-11). Edema-like MR abnormality was also reported in the posterior tibial tendon in adults with flatfoot (12, 13). However, these MR abnormalities have been described mostly in the symptomatic adults, but not in the adolescents with symptomatic navicular tuberosity, nor in correlation with the alleviation of symptom or the presence of accessory navicular. Therefore, the purpose of this study was to evaluate the prevalence of edema-like bone marrow pattern of adolescent symptomatic navicular tuberosity in correlation with the course of symptom and the presence of accessory navicular bone. We hypothesized that edema-like bone marrow pattern could tell the symptom of navicular tuberosity and the intensity of the pattern could tell the intensity of symptom.

MATERIALS AND METHODS

The investigation was performed in accordance with the institutional review board and ethics committee of the University of Tokushima. The subjects of this investigation were ten consecutive adolescent patients (5 males and 5 females) with a mean age of 11.5 years (range 9 to 14 years) presenting with pain localized to the navicular tuberosity (Table 1). Two patients complained of bilateral symptoms and the others had unilateral symptom (5 on the right and 3 on the left); all symptoms were aggravated by physical activity. No patients complained of pain or tenderness on another part of the foot.

Either acute injury or chronic overuse preceded the onset of symptoms in all cases with continuous participation in athletic activities. The average duration of symptom before presentation was ~1.8 months. Physical examination revealed that all except one patient (case 6, see Table 1) had flexible flatfoot. Static footprints were recorded on a Harris-Beath mat in the half body weight-bearing position (14). The arch index described by Staheli *et al.* (15) was used to confirm the presence of flexible flatfoot. The symptom was managed non-operatively with suspension of athletic activities in all cases and by wearing a medial longitudinal arch support in all patients with flexible flatfoot until relief of symptom. In more advanced cases, non-steroidal anti-inflammatory medications were used. The symptom was successfully healed in all cases and no patients required surgical intervention to alleviate symptom. The mean period until alleviation of symptom was 3.7 months (range 1.0 to 8.0 months, Table 1).

All patients underwent bilateral radiographic assessments at the initial presentation to determine the type of accessory navicular bone, followed by MR examination within two weeks after the initial presentation. MR examinations were performed on a Signa Profile 0.2-T whole-body MR imaging system (GE Medical System, Milwaukee, WI) using a standard extremity coil. Pulse sequences comprised spin-echo (SE) T1-weighted (repetition time/echo time (TR/TE), 400-500/16-20, 4.0 mm slice thickness; 22 cm field of view, 256 × 256 matrix) and SE T2-weighted fat saturated (TR/effective TE, 4,200-4,500/30-38, 4.0 mm slice thickness; 16-22 cm field of view, 256 × 256 matrix) images obtained in the horizontal and axial planes. MR abnormality was

Table 1. Clinical manifestations of the cases in this study

Case	Age (years)	Gender ¹	Symptomatic side	Type ²	Presence of flatfeet	Athletic activity	Duration of symptom (months)	Period for alleviation (months)	Abnormality at the initial MR examination	Number of MR studies	Diminution of MR abnormality
1	14	F	Right	II	+	Athletics	1.5	3.5	+	1	ND
2	13	F	Bilateral	II	+	Swimming	2.0	4.0	+	2	+
3	12	M	Left	II	+	Baseball	2.0	4.5	+	3	+
4	12	M	Right	-	+	Tennis	4.0	8.0	+	3	+
5	12	M	Left	-	+	Soccer	2.0	4.0	+	4	+
6	12	M	Right	II	-	Basketball	1.2	1.0	+	1	ND
7	11	F	Right	II	+	Baseball	1.0	3.5	+	1	ND
8	11	M	Right	-	+	Soccer	3.0	4.0	+	3	+
9	9	F	Bilateral	II	+	Volleyball	0.5	2.5	+	2	+
10	9	F	Left	II	+	Baseball	1.0	2.0	+	2	+

1; Female (F) or male (M), 2; type of accessory navicular if present and (-) is used in case of absence, ND; not determined, +; present, -; absent.

“edema-like bone marrow pattern”, which was depicted as an area of low signal intensity on T1-weighted images with high signal intensity on T2-weighted fat-saturated images (9, 16, 17). Neither conventional T2-weighted image nor contrast enhancement using an infusion of gadolinium was applied in this study. Seven patients (cases 2, 3, 4, 5, 8, 9 and 10) were willing to be further examined with consecutive MR imaging until heal of the symptom (an average of 2.7 times per patient in this group). We investigated the relationships of the symptom alleviation with type of accessory navicular bone on radiograph and edema-like bone marrow pattern on MRI.

RESULTS

On radiographic examination, accessory navicular bones were found in 7 cases, all of which were bilateral and were classified into type II. In the remaining three patients (cases 4, 5 and 8), no accessory navicular bones were detected on either side. No tarsal coalition or other abnormality was detected.

All symptomatic naviculars presented an edema-like bone marrow pattern (Fig. 1-3) irrespective of whether an accessory navicular bone was present or not. In those patients who took bilateral feet MR examinations, this pattern was observed only on the symptomatic side (Fig. 1). For the seven patients with consecutive MR examinations, the intensity of edema-like bone marrow pattern diminished with alleviation of symptom (Fig. 2 and 3). Surprisingly in the 3 patients without accessory navicular on either side (cases 4, 5 and 8), the navicular tuberosity only presented edema-like bone marrow pattern

on the symptomatic side (Fig. 3). This pattern again diminished with the alleviation of symptom. There were no MR abnormalities of the insertion of the posterior tibial tendon, such as signal change of the tendon substance and surrounding fluid throughout this study. We were unable to find any correlation between presence of flatfeet and specific MR findings.

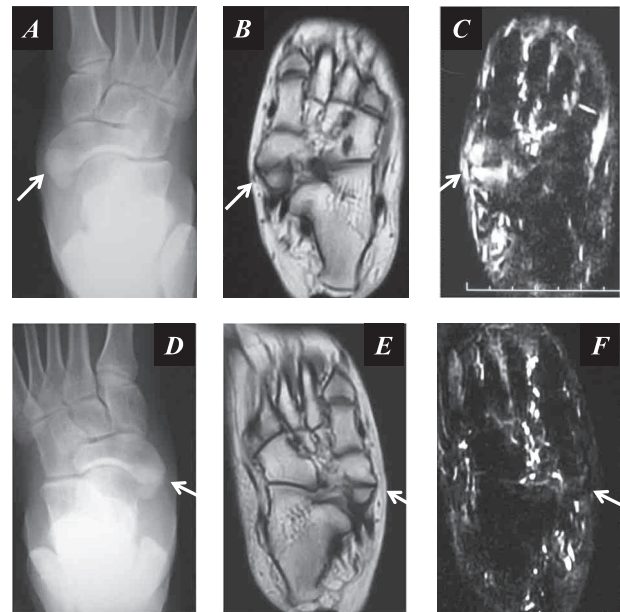


Fig. 1. Bilateral type II accessory navicular bones in case 1. Anteroposterior radiograph (A) of the symptomatic (right) side shows a type II accessory navicular bone (arrow). The ipsilateral T1-weighted (B) and T2-weighted fat saturated (C) horizontal MR images demonstrate edema-like bone marrow pattern on the both the accessory navicular bone and the navicular tuberosity facing to the synchondrosis (arrows), which might be described as “kissing edema pattern”. In contrast, despite the presence of accessory navicular bone (D), asymptomatic navicular bone (in the left foot) does not show edema-like bone marrow pattern on either T1-weighted (E) or T2-weighted fat saturated (F) MR image (arrows).

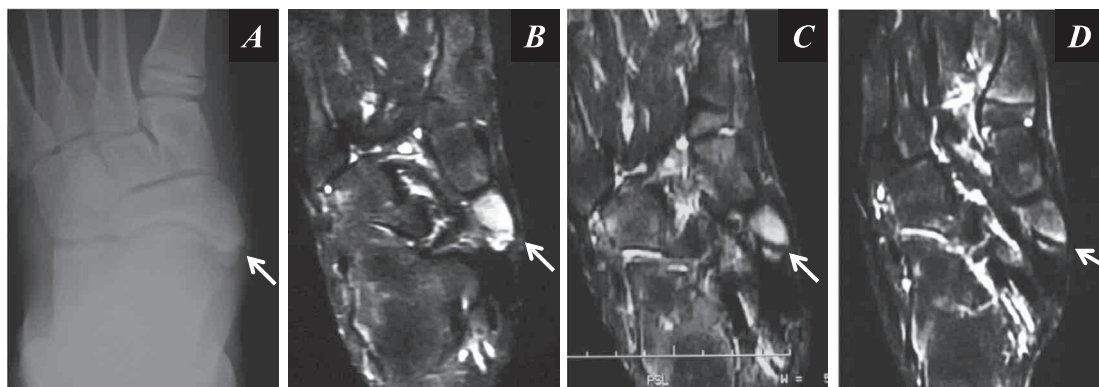


Fig. 2. For case 3, type II accessory navicular bone on radiograph (A). T2-weighted fat saturated MR image demonstrates the same pattern as the case 1 at the first examination (B). The edema-like bone marrow pattern gradually diminishes with alleviation of the symptom a month (C) and three months (D) after the first presentation.

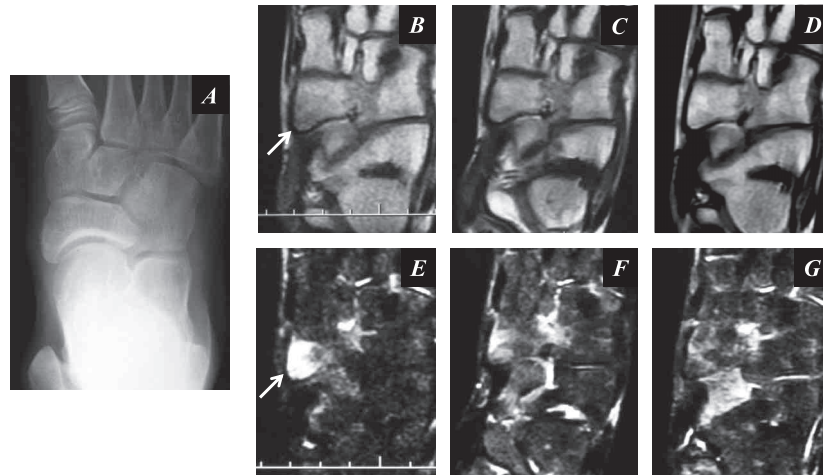


Fig. 3. For case 4, no accessory navicular bone is detected on the radiograph (A). T1-weighted (B, C and D) and T2-weighted fat saturated (E, F and G) horizontal MR images at the initial (B and E), after 2 months (C and F) and after 8 months (D and G) demonstrate the gradual diminution in the edema-like bone marrow pattern with alleviation of the symptom.

DISCUSSION

Symptomatic accessory navicular bones are very common conditions and have been reported to occur commonly in adolescence (18, 19). The results of this study indicate that symptomatic navicular in adolescence is described by an edema-like bone marrow pattern on MR image regardless of whether an accessory navicular is present or not, and that alleviation of the symptom is proportional to the diminish of the edema-like bone marrow pattern. The edema-like bone marrow pattern has been typically shown for symptomatic type II accessory navicular bones, in which the both sides of the synchondrosis present this pattern (9-11). In the present study, there were three patients who did not have accessory navicular bones (cases 4, 5 and 8) but still showed an edema-like bone marrow pattern on the navicular tuberosity. Wong *et al.* suggested the other pathologic mechanism for symptomatic navicular tuberosity in their study of 18 adolescents who had flexible flatfoot with pain of the navicular tuberosity and completed MR examination (20). They concluded that the symptom was not confined to the accessory navicular synchondrosis, and that an enthesopathy like process occurred at the insertion of posterior tibial tendon to the navicular in some cases (20). In the present study, three patients who did not have accessory navicular bone obviously showed bone marrow abnormality, although no patients showed MR abnormality of posterior tibial tendon. In addition to the mechanisms described by Wong *et al.*, we speculate another pathologic mechanism in adolescents, such as an

osteitis or osteochondrosis. Thus, we have to manage carefully the adolescent patients with symptomatic navicular tuberosity even without an accessory bone.

The edema-like bone marrow pattern in the navicular tuberosity diminished with the alleviation of symptom managed non-operatively in this study. The intensity of edema-like bone marrow pattern, especially the signal intensity on T2-weighted fat saturated images, may indicate pain intensity, despite the small number of patients in the current study and no quantifications of the intensity. To our knowledge, among previous studies of symptomatic foot conditions, only one tried to demonstrate a relationship between MR parameters and pain (16). There was, however, no correlation between bone marrow edema volume and peak pain intensity among patients with various ages. They did not investigate any relationships between bone marrow edema intensity and peak pain intensity.

Our study might have several limitations related to study design. First, the sample number was small and any statistical analyses were not performed in this study. Second, we did not have surgical or histologic correction of samples. The edema-like bone marrow pattern have been reported to reflect several different pathologic conditions except for true edema, such as bone marrow necrosis and fibrosis (21), fibrovascular tissue ingrowth and increased blood flow to the area (22), and reactive new bone formation (9). The background of conditions such as age of the patient, the cause of trauma, and anatomic location should be taken into account. Because we did not examine sagittal MR images in this study,

it is possible that we failed to detect pathologic conditions of the posterior tibial tendon, which were presented in previous studies (10, 20). Bone marrow signal changes were definitely detected on both the horizontal and axial MR images of all the symptomatic navicular in our study. Finally, the low-magnetic field MR used in this study might influence the results. There were several studies that compared the low-field and high-field MR images in musculoskeletal system. Kersting-Sommerhoff *et al.* reported 92% accordance of MR diagnoses between the low- and high-field for knee lesion and superior ability of the high-field to detect cartilage lesion (23). Taouli *et al.* concluded that high-field MRI and low-field dedicated MRI showed similar results in terms of cross-sectional grading of bone erosions, joint-space narrowing, and synovitis in the hands and wrists of patients with rheumatoid arthritis (24). Meanwhile, fat saturation might result in incomplete fat suppression in several conditions under low-field MR (25). Thus, the influences by low-field MR would be small.

In summary, symptomatic navicular in adolescents showed an edema-like bone marrow pattern on MR image. This pattern diminished with the alleviation of symptom managed non-operatively. Thus, MR images could be used for the diagnosis of symptomatic navicular and its intensity could monitor of the healing process, although MR would not be necessary for complete healing. Symptom occurred even at the navicular tuberosity without accessory navicular bone, which indicates different pathologic mechanism in adolescents is working, such as an osteitis or osteochondrosis.

CONFLICT OF INTEREST

No benefit or fund was received in support of this study.

REFERENCES

- Grogan DP, Gasser SI, Ogden JA : The painful accessory navicular : a clinical and histopathological study. *Foot Ankle* 10(3) : 164-169, 1989
- Kruse RW, Chen J : Accessory bones of the foot : clinical significance. *Mil Med* 160(9) : 464-467, 1995
- Shands AR, Jr., Wentz IJ : Congenital anomalies, accessory bones, and osteochondritis in the feet of 850 children. *Surg Clin North Am* : 1643-1666, 1953
- Lawson JP, Ogden JA, Sella E, Barwick KW : The painful accessory navicular. *Skeletal Radiol* 12(4) : 250-262, 1984
- Sella EJ, Lawson JP, Ogden JA : The accessory navicular synchondrosis. *Clin Orthop Relat Res* Aug(209) : 280-285, 1986
- Ray S, Goldberg VM : Surgical treatment of the accessory navicular. *Clin Orthop Relat Res* (177) : 61-66, 1983
- Bareither DJ, Muehleman CM, Feldman NJ : Os tibiale externum or sesamoid in the tendon of tibialis posterior. *J Foot Ankle Surg* 34(5) : 429-434, 1995
- Sella EJ, Lawson JP : Biomechanics of the accessory navicular synchondrosis. *Foot Ankle* 8(3) : 156-163, 1987
- Miller TT, Staron RB, Feldman F, Parisien M, Glucksman WJ, Gandolfo LH : The symptomatic accessory tarsal navicular bone : assessment with MR imaging. *Radiology* 195(3) : 849-853, 1995
- Choi YS, Lee KT, Kang HS, Kim EK : MR imaging findings of painful type II accessory navicular bone : correlation with surgical and pathologic studies. *Korean J Radiol* 5(4) : 274-279, 2004
- Mosel LD, Kat E, Voyvodic F : Imaging of the symptomatic type II accessory navicular bone. *Australas Radiol* 48(2) : 267-271, 2004
- Schweitzer ME, Karasick D : MR imaging of disorders of the posterior tibialis tendon. *AJR Am J Roentgenol* 175(3) : 627-635, 2000
- Khoury NJ, el-Khoury GY, Saltzman CL, Brandser EA : MR imaging of posterior tibial tendon dysfunction. *AJR Am J Roentgenol* 167(3) : 675-682, 1996
- Kanatli U, Yetkin H, Cila E : Footprint and radiographic analysis of the feet. *J Pediatr Orthop* 21(2) : 225-228, 2001
- Staheli LT, Chew DE, Corbett M : The longitudinal arch. A survey of eight hundred and eighty-two feet in normal children and adults. *J Bone Joint Surg Am* 69(3) : 426-428, 1987
- Zanetti M, Steiner CL, Seifert B, Hodler J : Clinical outcome of edema-like bone marrow abnormalities of the foot. *Radiology* 222(1) : 184-188, 2002
- Hayes CW, Conway WF, Daniel WW : MR imaging of bone marrow edema pattern : transient osteoporosis, transient bone marrow edema

- syndrome, or osteonecrosis. *Radiographics* 13(5) : 1001-1011, 1993
18. Macnicol MF, Voutsinas S : Surgical treatment of the symptomatic accessory navicular. *J Bone Joint Surg Br* 66(2) : 218-226, 1984
 19. Chen YJ, Hsu RW, Liang SC : Degeneration of the accessory navicular synchondrosis presenting as rupture of the posterior tibial tendon. *J Bone Joint Surg Am* 79(12) : 1791-1798, 1997
 20. Wong MW, Griffith JF : Magnetic resonance imaging in adolescent painful flexible flatfoot. *Foot Ankle Int* 30(4) : 303-308, 2009
 21. Zanetti M, Bruder E, Romero J, Hodler J : Bone marrow edema pattern in osteoarthritic knees : correlation between MR imaging and histologic findings. *Radiology* 215(3) : 835-840, 2000
 22. Saadat E, Jobke B, Chu B, Lu Y, Cheng J, Li X, Ries MD, Majumdar S, Lnk TH : Diagnostic performance of in vivo 3-T MRI for articular cartilage abnormalities in human osteoarthritic knees using histology as standard of reference. *Eur Radiol* 18(10) : 2292-2302, 2008
 23. Kersting-Sommerhoff B, Hof N, Lenz M, Gerhardt P : MRI of peripheral joints with a low-field dedicated system : a reliable and cost-effective alternative to high-field units? *Eur Radiol* 6(4) : 561-565, 1996
 24. Taouli B, Zaim S, Peterfy CG, Lynch JA, Stork A, Guermazi A, Fan B, Fye KH, Cenant HK : Rheumatoid arthritis of the hand and wrist : comparison of three imaging techniques. *AJR Am J Roentgenol* 182(4) : 937-943, 2004
 25. Delfaut EM, Beltran J, Johnson G, Rousseau J, Marchandise X, Cotten A : Fat suppression in MR imaging : techniques and pitfalls. *Radiographics* 19(2) : 373-382, 1999