

ORIGINAL**Three-dimensional sodium chloride (NaCl) model for simulated mandibular reconstruction surgery : a new environmentally friendly material**

Yoshiro Abe*, Ichiro Hashimoto*, Shinji Matsuo*, Keiichi Goishi*,
Keisuke Kashiwagi*, Hirokazu Nagai**, Youji Miyamoto**, and Hideki Nakanishi*

*Department of Plastic and Reconstructive Surgery, Institute of Health Biosciences, the University of Tokushima Graduate School, Tokushima, Japan, **Department of Oral Surgery, Institute of Health Biosciences, the University of Tokushima Graduate School, Tokushima, Japan

Abstract : Background : Mandibular reconstruction using a fibular graft is a difficult procedure that requires technical expertise to enable adequate occlusal function and restore an aesthetic appearance. Here we used three-dimensional (3D) sodium chloride (NaCl) models for simulated mandibular reconstruction surgery. This study aimed to reveal the accuracy of mandibular reconstruction with fibular grafts using this model. Methods : Mandibular reconstructions using 3D NaCl models were performed in 5 cases. The maxilla, mandible, and fibular models were developed using computed tomography (CT) data. We performed preoperative cutting and simulation surgery using this model. Angles between the body of the corpus and symphysis were measured from the axial view (n = 4). Angles between the ramus and the body of the corpus were measured from the lateral and axial views (n = 6). These angles were measured on simulated models and postoperative CT images were compared. Results : Differences between the angles measured on the simulated models and postoperative CT images were 0-5° (mean, 1.9°). Conclusions : We were able to reproduce the neomandibles with precise osteotomies using the 3D NaCl models. We believe that simulated mandibular reconstruction surgery using this model might help reduce the number of intraoperative neomandibular segment adjustments. J. Med. Invest. 61 : 318-324, August, 2014

Keywords : mandibular reconstruction, fibular, simulated surgery, three-dimensional model

INTRODUCTION

Use of the free osteocutaneous fibula flap is the preferred method for both primary and secondary mandibular reconstruction cases, such as immediate reconstruction after oncologic surgical ablation, replacement of exposed titanium reconstruction plate,

and reconstruction of mandibular osteomyelitis following irradiation (1-8). To restore the mandibular shape after resection, the fibula flap is partitioned into segments using closed wedge osteotomies. Determination of the angles between the bone segments and the lengths of the individual segments is complicated and requires intraoperative reassessment (9-12). If more time is required to assemble the bone segments, the risk of intraoperative complications, such as thrombi of the vascular pedicle or flap loss, increases (13). Therefore, the simulation of several surgical procedures using special software or a three-dimensional (3D) preoperative

Received for publication December 27, 2013 ; accepted February 18, 2014.

Address correspondence and reprint requests to Yoshiro Abe, M.D., Ph.D. Department of Plastic and Reconstructive Surgery, the University of Tokushima Graduate School, 3-18-15 Kuramoto, Tokushima 770-8503, Japan and Fax : +81-88-633-7297.

models made of plaster and a photopolymerization resin have been reported for assisting with operative planning and adjusting the setting for neomandibular reconstruction (14-17).

In the present study, we used a 3D sodium chloride (NaCl) model in a simulated surgery that allowed for adjustment of the occlusal relationship and confirmation of the shape of the mandible and fibula. Because preoperative simulation using the 3D NaCl model enables direct confirmation of the occlusal relationship or the location of the articular head, an optimal and symmetrical neomandible can be created after adjustment of the occlusal position on the simulated NaCl model. Compared with other published 3D models, the 3D NaCl model has several advantages: explicit coloring of the model's interior; strength and quality resembling real bone; relative low cost of the main material (salt); and environmental friendliness because of its high solubility in water. Therefore, we believe that NaCl may be an ideal environmentally friendly material for use in simulation surgery. However, the accuracy of this model has not yet been proven. The aim of this study was to determine the accuracy of the 3D NaCl models for simulated mandibular reconstruction surgery.

METHODS

Five patients underwent reconstruction with a free vascularized fibula bone graft using a 3D NaCl model (Sony EMCS Corp., Aichi, Japan) between September 2011 and November 2012 at Tokushima University Hospital. The subjects were men aged ranging 36-74 years (mean age, 59.6 years). Patient demographics are presented in Table 1. We report 2 cases of primary reconstruction immediately after resection of an ameloblastoma from the mandibular bone and 3 cases of secondary reconstruction due to plate exposure, plate corruption, and osteomyelitis following irradiation. In cases of plate exposure or plate corruption, fibular bones were transplanted

after these plates were removed. The neomandible was assembled with fibular bone segments and titanium miniplates were used to connect each segment and mandibular bone. In all cases, the fibular bone was elevated with a skin flap and vascular pedicles. Fibular arteries and veins of the transplanted flaps were anastomosed to the recipient vessels on the neck during microscopic surgery.

NaCl model creation process

Data obtained from a computed tomography (CT) scan involving the maxilla, mandible, and fibula were encoded using digital imaging and communication in medicine data in CD-R format and sent to a production company. One-millimeter slices of the area of interest were used in the present study. The 3D NaCl model was created as follows: 5% of a bonding material was mixed in NaCl particles measuring 30 μm in diameter, and after repeated reactions of these materials in combination with water, the 3D NaCl model was laminated with multiple layers (Figure 1).

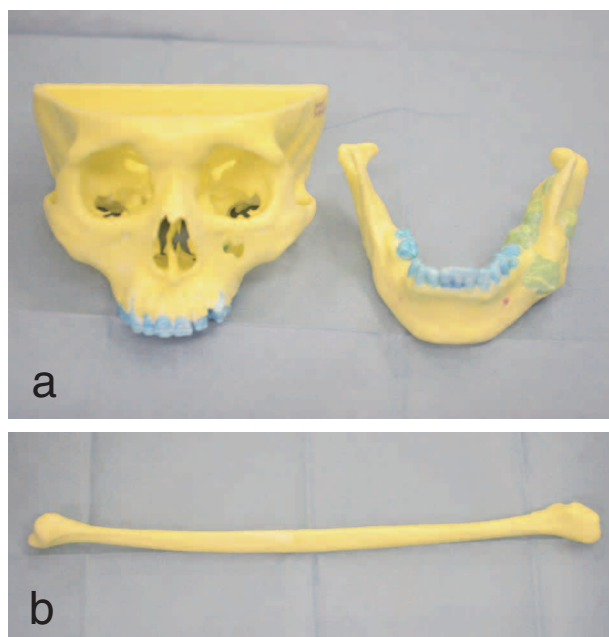


Figure 1. Three-dimensional NaCl models. (a) Mandible and maxilla models. The tumor to be resected is visible in the left mandible body. (b) Fibula model, slightly twisted.

Table 1. Patient Demographics

Case No.	Age (yr)	Sex	Diagnosis	Type of Reconstruction	Bone Defects	Number of Osteotomies
1	68	M	Plate exposure	Secondary	B-S-B	2
2	57	M	Plate corruption	Secondary	R-B	1
3	74	M	Irradiated osteomyelitis	Secondary	B-S-B	2
4	63	M	Ameloblastoma	Primary	R-B	1
5	36	M	Ameloblastoma	Primary	R-B	1

B, body of corpus; S, symphysis; R, ramus.

NaCl model simulation process

The mandible is categorized into bone units, namely, the ramus (R), body of the corpus (B), and symphysis (S), according to Urken's classification (2). Mandibular reconstruction in the present study was performed according to bone units (Figure 2). In the case of primary reconstruction, the original contour of the mandible on the 3D NaCl model was copied onto tracing paper. A line representing the expected mandibular defects and the optimal neomandible to be created using fibular bone segments was drawn on the same paper. The length of each bone segment, the angles between R and B observed from both lateral and axial views, and the angles between B and S observed from the axial view were measured on the paper. The 3D NaCl model of the fibula was cut into "bone segments" based on the measured lengths and the segments were attached at the measured angles to form the simulated NaCl model (Figure 2).

In the case of secondary reconstruction, adjustment of the mandible position was often required when original occlusion was lost. The optimal neomandible with correct occlusal position was drawn

on paper, while a simulated NaCl model was created by the same procedure used for the primary reconstruction. Especially in cases of reconstruction involving the articular head, it was important to confirm the correct position of the articular head of the neomandible by using simulated models. The harvested fibula could be cut and assembled to create a neomandible during surgery in the same manner as that in the simulated NaCl model.

Measurements and evaluations

The angles between B and S were measured from the axial view on the simulated 3D models and on the neomandible using postoperative CT images (n=4) (Figures 2a, 2b). The angles between R and B were measured from the lateral and axial views on the simulated 3D models and on the neomandible using the postoperative CT images (n=6) (Figures 2c, 2d, 2e, 2f). Postoperative error was defined as differences between angles measured on the simulated 3D models and angles measured on the postoperative CT images. The postoperative errors were measured on 10 angles in 5 patients.

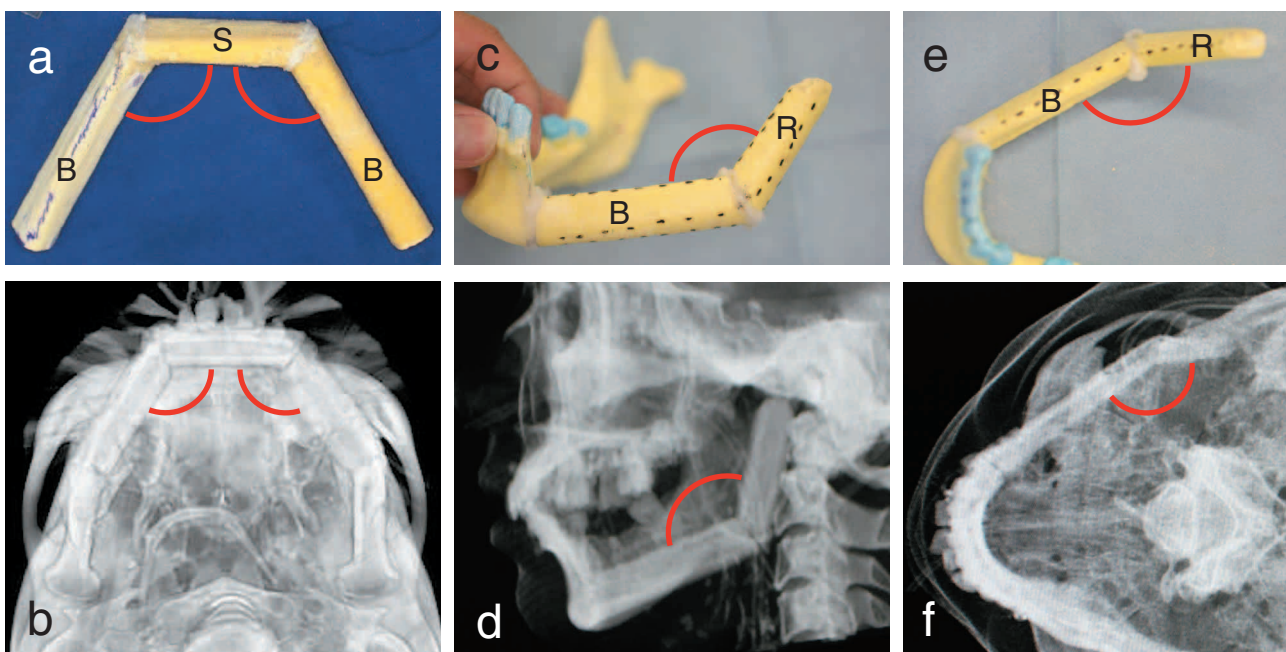


Figure 2. Simulated NaCl models and postoperative computed tomography (CT) images for angle measurement. (a) The red arcs indicate the angles between the body of the corpus (B) and symphysis (S) on the simulated NaCl model in case 1. Measured angles are 60° and 55° . (b) The red arcs indicate the postoperative angles between B and S on the CT image in case 1. Measured angles are 62° and 60° . (c) The red arc indicates the angle between R and B from the lateral view on the simulated NaCl model in case 5. The measured angle is 135° . (d) The red arc indicates the postoperative angle between R and B from the lateral view on the CT image in case 5. The measured angle is 130° . (e) The red arc indicates the angle between R and B from the axial view on the simulated NaCl model in case 5. The measured angle is 150° . (f) The red arc indicates the postoperative angle between R and B from the axial view on the CT image in case 5. The measured angle is 150° .

RESULTS

All of the transplanted tissues survived in the present study. The angles measured on the simulated models and CT images are shown in Table 2. In cases 1 and 3, bilateral angles between B and S observed from the axial view were measured. In cases 2, 4, and 5, angles between R and B observed from the lateral and axial view were measured. The

postoperative error was 0-5° (mean, 1.9°). In case 1, the mandibular defect existed on the B-S-B region of the mandible. The neomandible was assembled with fibular bone segments according to the simulation with the 3D NaCl model. The differences between angles measured on the simulated models and on the CT images were 2 and 5° at bilateral angles between B and S observed from the axial view. Symmetrical facial appearance was achieved (Figure 3).

Table 2. Measurements of the Angles on Simulated Models and CT Images

Case No.	Angles on Simulated Models	Angles on CT Images	Postoperative Errors
1	60°, 55° *	62°, 60° *	2°, 5°
2	130°, 145° **	130°, 150° **	0, 5°
3	58°, 60° *	60°, 60° *	2°, 0
4	130°, 145° **	130°, 145° **	0, 0
5	135°, 150° **	130°, 150° **	5°, 0

*bilateral angles between B and S observed from the axial view.

**angles between R and B observed from the lateral and axial view ; first figure indicates the angle observed from the lateral view and second figure indicates the angle observed from the axial view.

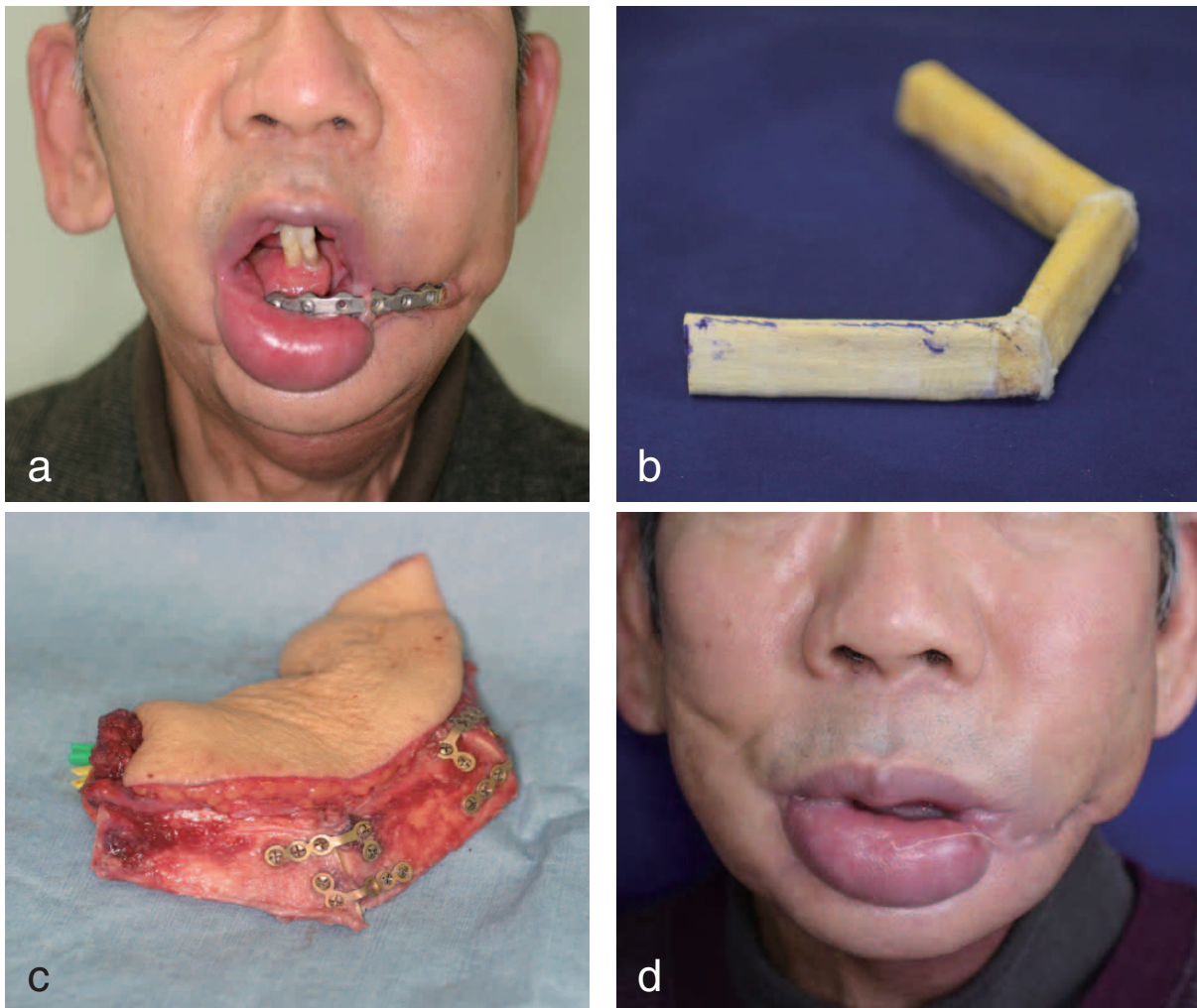


Figure 3. Case 1. (a) Preoperative image. An exposed plate and contracted mucosa are visible under the plate. (b) The simulated NaCl model. (c) The neomandible is assembled with 3 pieces of fibula according to the simulated NaCl model. A skin flap and 2 clips for vascular pedicles are visible. (d) Six months after the surgery, satisfactory appearance of the mandible is noted.

In case 2, the mandibular defect existed on the B-R region including the mandibular head. The simulated NaCl model was prepared after the malocclusion was corrected. The neomandible was assembled with fibular bone segments according to the simulation using the 3D NaCl model. The differences between angles measured on the simulated models and on the CT images were 0 and 5° at angles between R and B observed from the lateral and axial view. A symmetrical facial appearance was achieved with a satisfactory occlusal relationship (Figure 4). All osteotomies were performed accurately and errors were within 5°. Completing the preoperative simulation with the 3D NaCl model resulted in a shortened time required to measure osteotomy angles intraoperatively and correct adjustment of each fibular bone segment in the occlusal position.

DISCUSSION

In the present study, we estimated the accuracy of NaCl model use for mandibular reconstruction in a simulation surgery using the 3D NaCl model. In fact, the postoperative angles achieved in clinical cases, as measured on CT images, were very close to the optimal angles on the simulated NaCl model. The postoperative shape of the neomandible closely resembled the shape of the simulated NaCl model because the 3D NaCl model accurately represented the actual bone, and the resected area of the mandible could be easily and precisely determined because the mandibular tumors can be reproduced and confirmed in different colors. The surgical procedure used to assemble the neomandible could be performed smoothly and successfully because we could observe the fibular shape on the 3D NaCl model and assemble the bone segments prior to the

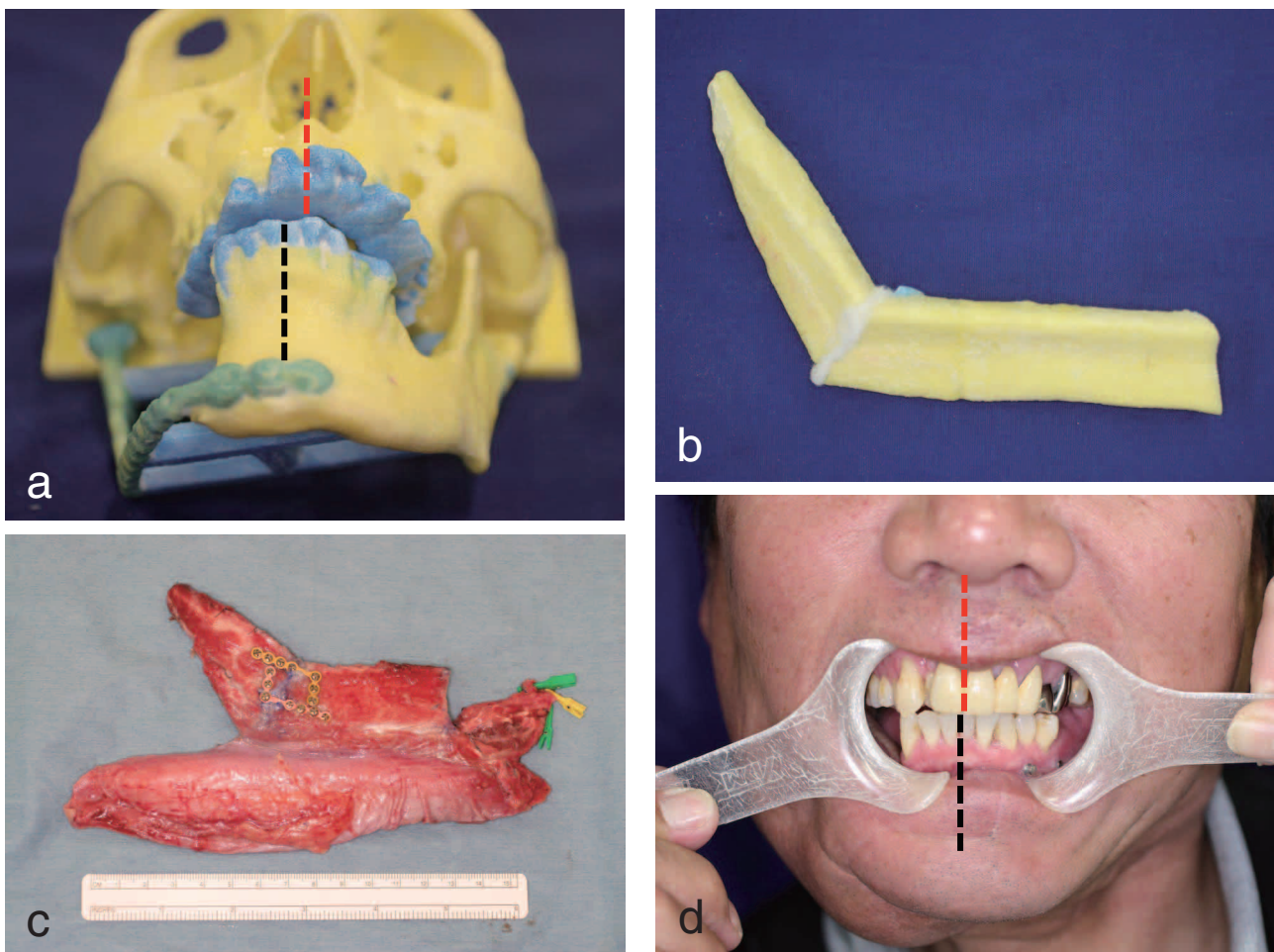


Figure 4. Case 2. (a) Preoperative 3D NaCl models of the maxilla and mandible show malocclusion. The black and red dots indicate the centerline of each jaw. Note the gap between the centerlines. (b) The simulated NaCl model. (c) The neomandible is assembled with 2 pieces of fibula according to the simulated NaCl model. A skin flap and vascular pedicle with 3 clips are visible with the fibula. (d) Six months after the surgery, the gap between the centerlines is decreased.

surgery. Bone segment assembly is a complicated procedure because the cortex of the fibula is composed of 3 twisted and curved aspects whose degrees of curvature differ among individuals. Therefore, preoperative knowledge of these features of each fibula would lead to accurate osteotomy during surgery.

Mandibular reconstruction remains a challenging procedure for reconstructive surgeons because mandibular occlusal function and aesthetic appearance are affected by the chosen reconstructive techniques, surgeon's expertise, and position and shape of the grafted bone (3, 10). Recent methods such as computer-aided operation planning for extensive mandibular reconstruction or virtual surgical planning have been reported (9, 10). Moreover, the 3D images on a display may not be convenient for complicated surgical planning. Because it is difficult to restore the occlusal position preoperatively by using these procedures, it may not be possible to achieve a symmetrical appearance of the reconstructed mandible during an actual operation (16). In contrast, preoperative simulation using our 3D model enables direct confirmation of the occlusal relationship or the location of the articular head. An optimal and symmetrical neomandible can be created after adjustment of the occlusal position on the simulated NaCl model is performed.

Compared with other published reports on 3D models made of plaster or photopolymerization resin, our 3D NaCl model has the following advantages: various coloring of the interior materials according to CT values; strength and quality resembling real bone; relative low cost of the main material (salt); and environmental friendliness due to high solubility in water. Tooth roots, nerves, or neural tubes, which have different CT values from those of bone, can be dyed in different colors. In our experiences, plaster 3D models were occasionally damaged during simulation surgery due to the material's weakness. In contrast, the 3D NaCl model is prepared using a very strong material that cannot be shattered or cracked during the simulation surgery. The powder released by resin models may cause severe health impairments when the resin model is cut during the simulation. Disposal of the resin model may present an environmental concern and become a problem because it is a hazardous chemical substance (11). Therefore, we believe that NaCl may be an ideal material for solving these health and environmental issues. This model does have one disadvantage, however: it becomes soft

in high-humidity environments because of its high water solubility. Thus, a desiccant must be included in the package to preserve such models.

Although the 3D NaCl model was developed in 2010, to our knowledge, the present study is the first to describe its use in simulated mandibular reconstruction. The findings of this study encourage reconstructive surgeons to improve techniques and perspectives to achieve better mandibular reconstruction outcomes. The use of this model also reduces repetitive and complicated intraoperative procedures required to adjust the neomandible. With further development of this model, it can be used in cases of osteotomy for congenital cranial deformities or posttraumatic deformities, as previous 3D models have already been used for such cases. Additional coloring of internal structures such as tooth roots or neural tubes in this 3D model may prevent extensive injuries to such structures during the actual surgery.

CONFLICT OF INTEREST

The authors declare no conflicts of interest relevant to this manuscript.

REFERENCES

1. Hidalgo DA: Fibular Free Flap: A New Method of Mandible Reconstruction. *Plast Reconstr Surg* 84: 71-79, 1989
2. Urken ML, Weinberg H, Vickery C, Buchbinder D, Lawson W, Biller HF: Oromandibular Reconstruction Using Microvascular Composite Free Flaps. Report of 71 Cases and a New Classification Scheme for Bony, Soft-Tissue, and Neurologic Defects. *Arch Otolaryngol Head Neck Surg* 117: 733-744, 1991
3. Hidalgo DA: Aesthetic Improvements in Free-Flap Mandible Reconstruction. *Plast Reconstr Surg* 88: 574-585, 1991
4. Hidalgo DA, Rekow A: A Review of 60 Consecutive Fibula Free Flap Mandible Reconstructions. *Plast Reconstr Surg* 96: 585-596, 1995
5. Shpitzer T, Neligan PC, Gullane P, Freeman JE, Boyd BJ, Rotstein LE, Brown DH, Irish JC, Gur E: Oromandibular Reconstruction with the Free Fibula Flap: Analysis of 50 Consecutive Flaps. *Arch Otolaryngol Head Neck Surg* 123:

- 939-944, 1997
6. Urken M, Buchbinder D, Costantino PD, Sinha U, Okay D, Lawson W, Biller HF : Oromandibular Reconstruction Using Microvascular Composite Flaps. Report of 210 Cases. *Arch Otolaryngol Head Neck Surg* 124 : 46-55, 1998
 7. Takushima A, Harii K, Asato H, Nakatsuka T, Kimata Y : Mandibular Reconstruction Using Microvascular Free Flaps : A Statistical Analysis of 178 Cases. *Plast Reconstr Surg* 108 : 1555-1563, 2001
 8. Wei FC, Celik N, Yang WG, Chen IH, Chang YM, Chen HC : Complications after Reconstruction by Plate and Soft-Tissue Free Flap in Composite Mandibular Defects and Secondary Salvage Reconstruction with Osteocutaneous Flap. *Plast Reconstr Surg* 112 : 37-42, 2003
 9. Kahler SH, Manders EK : Planned Angle Osteotomy. *Plast Reconstr Surg* 87 : 969-973, 1991
 10. Strackee SD, Kroon FHM, Jaspers JEN, Bos KE : Modeling a Fibula Transplant in Mandibular Reconstructions : Evaluation of the Effects of a Minimal Number of Osteotomies on the Contour of the Jaw. *Plast Reconstr Surg* 108 : 1915-1921, 2001
 11. Strackee SD, Kroon FHM, Spierings PTJ, Jaspers JEN : Development of a Modeling and Osteotomy Jig System for Reconstruction of the Mandible with a Free Vascularized Fibula Flap. *Plast Reconstr Surg* 114 : 1851-1858, 2004
 12. Moro A, Cannas R, Boniello R, Gasparini G, Pelo S : Techniques on Modeling the Vascularized Free Fibula Flap in Mandibular Reconstruction. *J Craniofac Surg* 20 : 1571-1573, 2009
 13. Chang SY, Huang JJ, Tsao CK, Nguyen A, Mittakanti K, Lin CY, Cheng MH : Does Ischemia Time Affect the Outcome of Free Fibula Flaps for Head and Neck Reconstruction? A Review of 116 Cases. *Plast Reconstr Surg* 126 : 1988-1995, 2010
 14. Hallermann W, Olsen S, Bardyn T, Taghizadeh F, Banic A, Iizuka T : A New Method for Computer-Aided Operation Planning for Extensive Mandibular Reconstruction. *Plast Reconstr Surg* 117 : 2431-2437, 2006
 15. Antony AK, Chen WF, Kolokythas A, Weimer KA, Cohen MN : Use of Virtual Surgery and Stereolithography-Guided Osteotomy for Mandibular Reconstruction with the Free Fibula. *Plast Reconstr Surg* 128 : 1080-1084, 2011
 16. Goto M, Katsuki T, Noguchi N, Hino N : Surgical Simulation for Reconstruction of Mandibular Bone Defects Using Photocurable Plastic Skull Models : Report of Three Cases. *J Oral Maxillofac Surg* 55 : 772-780, 1997
 17. Kernan BT, Wimsatt JA : Use of a Stereolithography Model for Accurate, Preoperative Adaptation of a Reconstruction Plate. *J Oral Maxillofac Surg* 58 : 349-351, 2000