

REVIEW

A new concept of transforaminal ventral facetectomy including simultaneous decompression of foraminal and lateral recess stenosis : Technical considerations in a fresh cadaver model and a literature review

Koichi Sairyo⁽¹⁾, Kosaku Higashino⁽¹⁾, Kazuta Yamashita⁽¹⁾, Fumio Hayashi⁽¹⁾, Keizo Wada⁽¹⁾, Toshinori Sakai⁽¹⁾, Yoichiro Takata⁽¹⁾, Fumitake Tezuka⁽¹⁾, Masatoshi Morimoto⁽¹⁾, Tomoya Terai⁽²⁾, Takashi Chikawa⁽³⁾, Hiroshi Yonezu⁽¹⁾, Akihiro Nagamachi⁽¹⁾, and Yoshihiro Fukui⁽⁴⁾

⁽¹⁾Department of Orthopedics, Tokushima University, ⁽²⁾Department of Orthopedic Surgery, Tokushima Prefecture Naruto Hospital, ⁽³⁾Department of Orthopedic Surgery, Tokushima Municipal Hospital, ⁽⁴⁾Department of Anatomy, Tokushima University

Abstract : Percutaneous endoscopic surgery for the lumbar spine, which was established in the last decade, requires only an 8-mm skin incision and causes minimal damage to the paravertebral muscles ; thus, it is considered to be a minimally invasive technique for spinal surgery. It has been used to perform percutaneous endoscopic discectomy via two main approaches : the TF approach is a posterolateral one through the intervertebral foramen and can be done under local anesthesia ; the IL approach is a more traditional one through the interlaminar space and is difficult to perform under local anesthesia. Recently, these techniques have been applied for lumbar spinal stenosis (LSS), the TF method for foraminal stenosis under local anesthesia, and the IL method for central and lateral recess stenosis under general anesthesia. In this study, using a fresh human cadaver model, we performed simultaneous decompression of the lateral recess and foraminal stenosis at L4-5 using the TF approach. Computed tomography confirmed enlargement of the lateral recess and intervertebral foramen. This technique, which can be performed under local anesthesia, should benefit elderly patients with LSS and poor general condition due to multiple comorbidities. Finally, we introduce the concept of percutaneous transforaminal ventral facetectomy using a spinal percutaneous endoscope. *J. Med. Invest.* 64 : 1-6, February, 2017

Keywords : Percutaneous endoscopic surgery, lumbar spinal stenosis, foraminoplasty, ventral facetectomy

INTRODUCTION

Endoscopic surgery for lumbar disorders was introduced in the 1990s. The two main forms at present are micro-endoscope-assisted tubular surgery and percutaneous full endoscopic surgery. As shown in Figure 1, microendoscope-assisted tubular surgery, such as microendoscopic discectomy (MED) (1, 2), was developed in an attempt to reduce the invasiveness of the traditional Love's procedure (i.e., interlaminar decompression). MED is usually performed under general anesthesia and involves dissection of the paravertebral muscles via a skin incision of approximately 16 mm. This technique has recently been applied to decompression surgery for patients with lumbar spinal stenosis (LSS). Although a steep learning curve is required, decompression has been achieved using the MED technique (3, 4).

The more recent technique of percutaneous full endoscopic surgery is an adaptation of the percutaneous nucleotomy (PN) procedure devised by Hijikata (5), and it can be performed under local anesthesia. Hijikata did not use a spinal endoscope ; therefore, it was unable to introduce a cannula into a herniated mass in the neural canal. Percutaneous techniques were subsequently tried (6-10), with single-portal endoscopic discectomy being developed around

the end of the last century (8-10). This technique became known as percutaneous endoscopic discectomy (PED) and was initially indicated for herniated nucleus pulposus (HNP) (8-10). PED was first performed using a transforaminal (TF) posterolateral approach

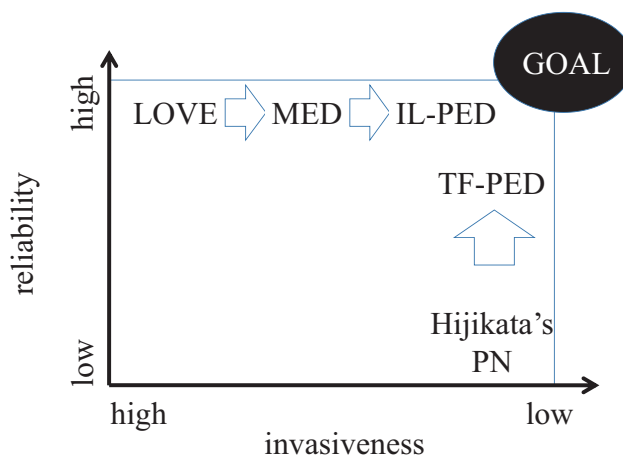


Figure 1 : Reliability and degree of invasiveness of a variety of disc surgeries. MED : microendoscopic discectomy, IL-PED : interlaminar approach of percutaneous endoscopic discectomy, TF-PED : transforaminal approach of percutaneous endoscopic discectomy, PN : percutaneous nucleotomy

Received for publication July 29, 2016 ; accepted September 19, 2016.

Address correspondence and reprint requests to Koichi Sairyo, MD, PhD, Professor and Chairman, Department of Orthopedics, Tokushima University Graduate School 3-18-15 Kuramoto, Tokushima 770-8503, Japan and Fax : +81-88-633-0178.

similar to that used in Hijikata's PN technique (8-10). Because the TF-PED procedure requires only a small skin incision (approximately 8 mm) and damage to the paravertebral muscles is minimal, it is considered to be the least invasive. PED can also be performed using an interlaminar (IL) approach (11, 12). IL-PED is indicated in some cases, particularly with a high iliac crest, where HNP at the L5-S1 level are anatomically difficult to access via the TF approach. However, IL-PED usually requires general anesthesia, which is its main disadvantage compared with TF-PED.

With the advent of specialized instrumentation such as the ultra-thin high-speed drill and trephine reamer for use in the small working space of an endoscopic system, PED can now be used in decompression surgery for LSS (lumbar spinal stenosis). Here, we review the state-of-the-art PED techniques for LSS, describe a novel decompression technique using transforaminal PED, and propose the new concept of ventral facetectomy.

LITERATURE REVIEW

Type of the lumbar spinal stenosis and PED

There are three types of LSS: intervertebral foraminal stenosis, lateral recess stenosis, and central canal stenosis (13).

1) Intervertebral foraminal stenosis

The exiting nerve root is impinged due to the foraminal stenosis, and TF-PED can be used to enlarge the intervertebral foramen. Under local anesthesia, the superior articular process can be partially drilled and the exiting nerve can be decompressed; if needed, disc bulging can be managed simultaneously.

2) Lateral recess stenosis

This disorder is amenable to IL-PED, particularly if unilateral, and is not technically demanding for surgeons experienced in using this approach for HNP.

3) Central canal stenosis

Most recently, central canal stenosis has also been treated using IL-PED, whereby bilateral decompression can be performed with the unilateral approach.

Decompression surgery using TF-PED

The most important benefit of this approach is that surgery is possible under local anesthesia. Nowadays, patients undergoing spinal surgery are typically older, given the steadily increasing longevity of populations worldwide. Surgical procedures that can be performed under local anesthesia are preferred in the elderly population, given the common comorbidities in this age group.

Foraminal stenosis compressing the exiting nerve root is potentially a good indication for TF-PED because the technique enables access to the neural canal through the intervertebral foramen. In a report underscoring the importance of foraminal stenosis as a cause of residual symptoms in patients with failed back surgery, Yeung and Gore described 30 patients treated with TF-PED technique in whom foraminoplasty could be performed under local anesthesia (14). The mean visual analog score in these patients improved from 7.2 preoperatively to 4.0 postoperatively and the Oswestry Disability Index from 48% to 31%. As a complication, transient dysesthesia occurred in 4 patients in the early postoperative period. Further, Ahn *et al.* reported excellent or good clinical results in at least 80% of 35 patients with foraminal stenosis treated by TF-PED technique (15). Two patients in their series also experienced transient dysesthesia postoperatively.

Foraminoplasty has also been reported to be effective for safe removal of an intra-canalicular herniated mass (16, 17). With this procedure, the intervertebral foramen can be enlarged, allowing safe removal of the herniated mass without damage to the exiting nerve root (16, 17), which is one of the recognized complications of TF surgery (18, 19). Essentially, this technique involves using a

high-speed burr to remove the excessive bone. Henmi *et al.* (17) reported their experience with foraminoplasty using the high-speed burr followed by ventral epiduroscopic observation (20, 21). After foraminotomy, a cannula could be inserted safely into the ventral epidural space in the neural canal. The ventral epidural space could then be observed and the extruded fragments inspected. There has also been a report by Li *et al.* of a 92.5% success rate in 134 consecutive patients who underwent foraminoplasty using a trephine reamer followed by TF-PED (22).

As already mentioned, TF-PED is a challenging procedure in patients with an HNP at L5-S1 and a high iliac crest; thus, IL-PED was developed for these patients (12, 13). In 2016, Choi *et al.* clearly described the usefulness of foraminoplasty in patients with a high iliac crest (23). Lee *et al.* (24) and Abe *et al.* (25) also used foraminoplasty to obtain safe access to the neural canal and remove an HNP at the lumbosacral junction, with outcomes as successful as those reported by Choi *et al.*

Figure 2 shows the results for a patient treated at our institution in whom the foramen at L5-S1 was enlarged by foraminoplasty and an intracanalicular HNP was removed. The endoscopic view clearly shows decompression of the S1 nerve root (arrows) traveling just beside the S1 pedicle (Figure 3).

Decompression surgery using IL-PED

Decompression of both the lateral recess and the central stenosis is possible with this approach. The IL technique was first used for unilateral decompression of lateral recess stenosis (26) and subsequently for bilateral decompression of lateral recess stenosis and central stenosis using the unilateral approach (27, 28). In 2007, Ruetten *et al.* reported a study in which they compared the outcome of IL-endoscopic decompression with that of microsurgical decompression in 161 patients (26). After 2 years of follow-up, the clinical outcome was similar in the two groups, but the complication and revision rates were significantly reduced in the endoscopic group.

In 2011, Komp *et al.* reported their clinical outcome data for 74 patients who underwent bilateral decompression using the IL-PED system with a unilateral approach (27). After 2 years of follow-up, 51 patients (70.8%) had either no leg pain or leg pain that was almost completely resolved and 16 (22.2%) had either occasional pain or pain that was greatly reduced. However, there were complications in this series, including postoperative transient dysesthesia (n=5), transient urinary retention (n=2), injury to the dura (n=2), and increased paresis (n=1). In 2015, the same group reported a study comparing conventional microscopic decompression and full endoscopic posterior decompression in which the clinical outcome was similar in both groups but again with a lower complication rate noted in the endoscopic group (28).

This technique was pioneered in Japan by Professor Akira Dezawa in Teikyo University Mizonokuchi Hospital. He performed the first posterior decompression using the PED system in patients with the lumbar spinal stenosis in 2009 (29) and developed an ultra-thin high-speed drill specifically for use with this system (30), first for lateral recess stenosis and then for central stenosis. Decompression surgery can now be performed for both pathologies using the IL-PED approach, now known as percutaneous endoscopic laminectomy.

CADAVERIC STUDY

This investigation was approved by institutional review board of our institution. We used a fresh cadaveric model (male, 68 years old) to assess the technical feasibility of transforaminal ventral facetectomy including foraminal and lateral recess decompression. The left L4-5 level was selected. With the cadaver in a prone

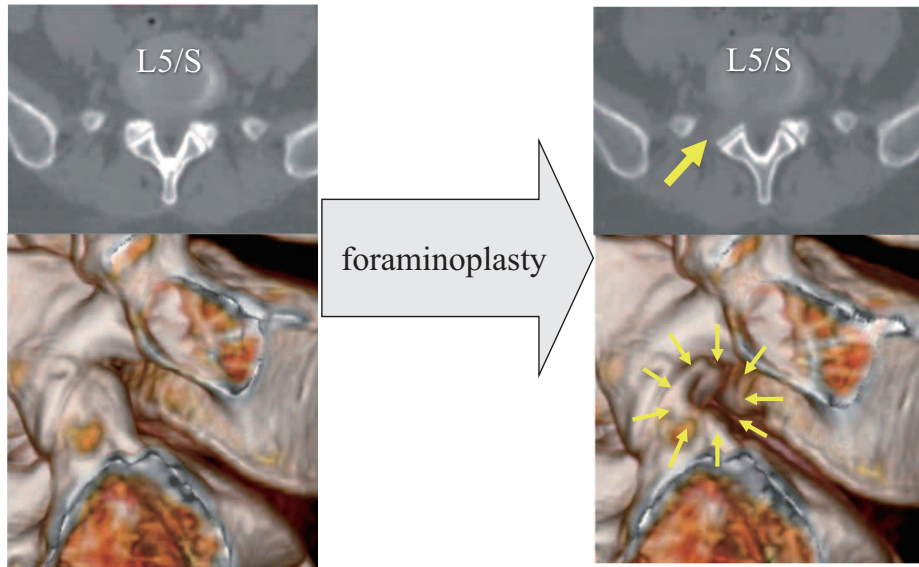


Figure 2 : Preoperative and postoperative CT images of an intracanalicular HNP at L5-S1. Due to a high iliac crest, it was difficult to access the L5-S1 disc space without foraminoplasty (left panel). However, after foraminoplasty, the HNP at L5-S1 could be removed (right panel). CT scans show the area of foraminoplasty (arrows).

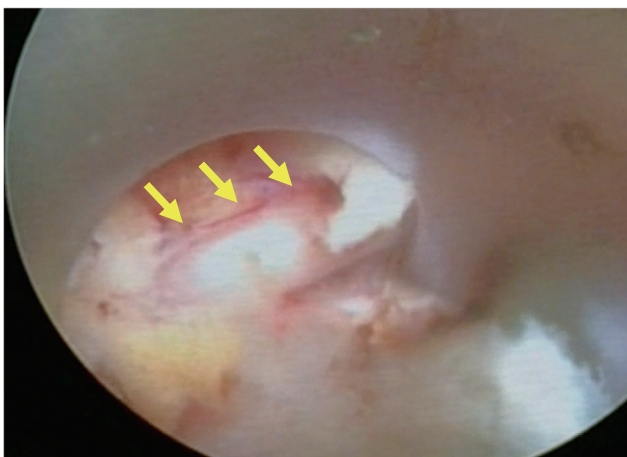


Figure 3 : Final endoscopic view after TF-PED. The right S1 nerve root is decompressed (arrow).

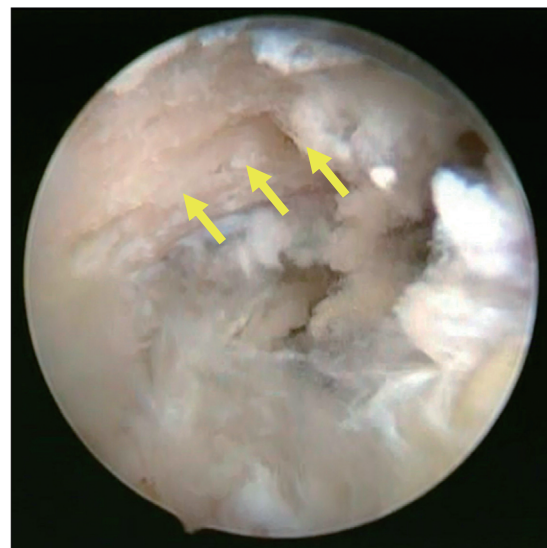

Figure 4 : Endoscopic view of the right L5 superior articular process (arrows).

position, an 8 mm skin incision was made posterolaterally on the back 9 cm away from the midline. In accordance with the inside-out procedure (8, 9, 31), the cannula was first inserted into the disc at L4-5 through the safety triangle. After the selected discectomy (8, 9), the cannula was withdrawn to just outside of the disc, where the lateral aspect of the facet joint could be seen endoscopically. Figure 4 shows an endoscopic view of the superior articular process (SAP) at L5. Note the foraminoplasty was commenced using an ultra-thin high-speed drill. The SAP was hypertrophic and occupied the intervertebral foramen, causing the foraminal stenosis seen on a three-dimensional computed tomography (CT) scan (Figure 5, left). The SAP was drilled and shaved completely, so that both foraminal and lateral recess decompression could be performed endoscopically at the same time. The completely decompressed L5 nerve root (yellow arrows) is clearly visible traveling just around

the pedicle (red arrows) in Figure 6. The lateral wall of the L5 nerve root is completely resected.

Figure 5 shows a three-dimensional CT scan before and after the ventral facetectomy. After surgery, the SAP was completely removed, such that the foraminal stenosis was resolved (Figure 5, right). Sagittal and axial CT scans through the facet joint are shown in Figure 7. After surgery, the SAP at L5 was completely removed, with enlargement of the lateral recess. These CT scans clearly demonstrate that lateral recess decompression with simultaneous foraminal decompression would be possible using the TF-PED approach.

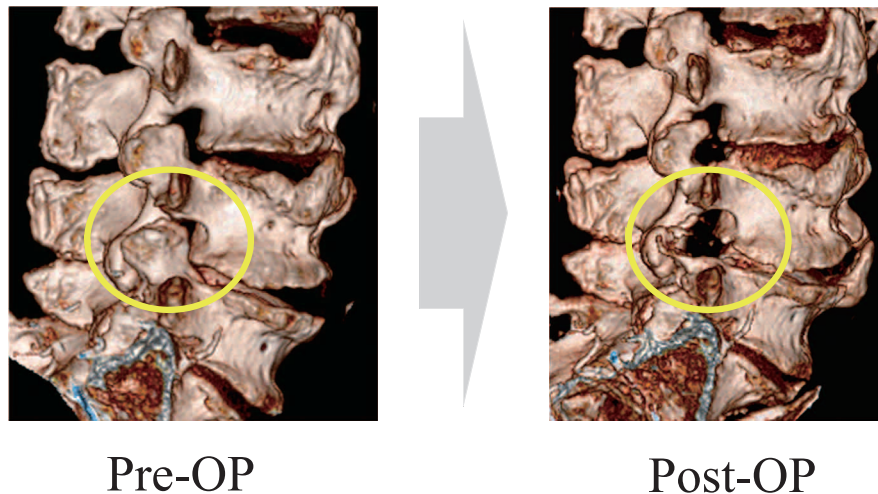


Figure 5 : Three-dimensional CT scans before (left panel) and after (right panel) ventral facetectomy in a cadaver model. Note the L5 superior articular process is completely removed.

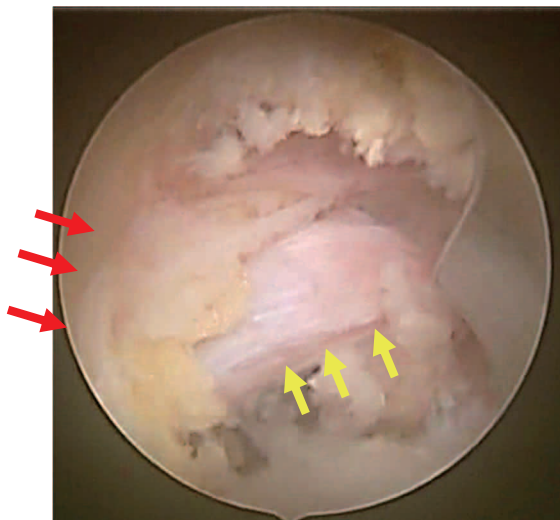


Figure 6 : Final endoscopic view after ventral facetectomy as above. The right L5 nerve root is noted (yellow arrows). The lateral wall of the L5 nerve root is resected completely.

DISCUSSION

In this report, we have reviewed state-of-the-art percutaneous full endoscopic surgery for LSS and described the main TF and IL approaches used for this procedure. The IL approach has been reported to be very useful for decompression of central and/or lateral recess stenosis (25-28). However, this approach basically requires general anesthesia (sometimes epidural anesthesia) because the nerve roots need to be handled and decompressed during surgery. The TF approach, however, can be performed for foraminal stenosis under local anesthesia (14-17), and this has been of greatest benefit in TF-percutaneous full endoscopic surgery (8, 9, 31, 32). The elderly often have comorbidities (32) rendering them at high risk for general anesthesia, so surgeries that can be done under local anesthesia are preferable in this age group. However, based on anatomic considerations, only the TF approach for

foraminal stenosis has been discussed in the literature (14-17). In practice, during foraminoplasty via the TF approach, we have sometimes noticed that the traversing nerve root is decompressed at the same time as the exiting nerve, due to wide removal of the superior facet joint on the cranial side (Figure 3). This clinical experience led us to the concept of transforaminal ventral facetectomy, which includes simultaneous decompression of both foraminal and lateral recess stenosis.

Before embarking on clinical application of this technique, we attempted a left ventral facetectomy at the L4-5 level in a fresh cadaver model. As shown in Figures 5 and 7, the superior articular process of L5 was completely removed, so that decompression of the foraminal and lateral recess stenosis could be completed. Three-dimensional CT demonstrated that the intervertebral foramen could be fully widened, allowing complete foraminal decompression as well as decompression of the exiting L4 nerve (Figure 5). Further, an axial slice through the disc showed that the lateral recess was enlarged after ventral facetectomy and the traversing L5 nerve root was successfully decompressed (Figure 7). Thus, this cadaveric study shows that ventral facetectomy is technically possible using the percutaneous endoscopic system via a TF-PED approach. The fact that it can be performed under local anesthesia makes it potentially very useful for treating elderly patients who, because of frequent comorbidities such as lung, heart, and kidney dysfunction, may not be indicated for procedures performed under general anesthesia.

We anticipate one possible shortcoming using this technique. As part of this study, we additionally performed a partial pediculotomy (see Figure 7), which decreased the facet contact area. Completely removal of this contact area by ventral facetectomy would result in segmental spinal instability, so this technique would require meticulous surgical planning with regard to the amount of facet joint to be removed.

In conclusion, we have reviewed state-of-the-art decompression surgery using the percutaneous endoscopic system for the lumbar spinal stenosis. We have also introduced the concept of transforaminal ventral facetectomy, which enables simultaneous decompression of foraminal and lateral recess stenosis. The feasibility of this surgical technique has been demonstrated in a fresh cadaver model.

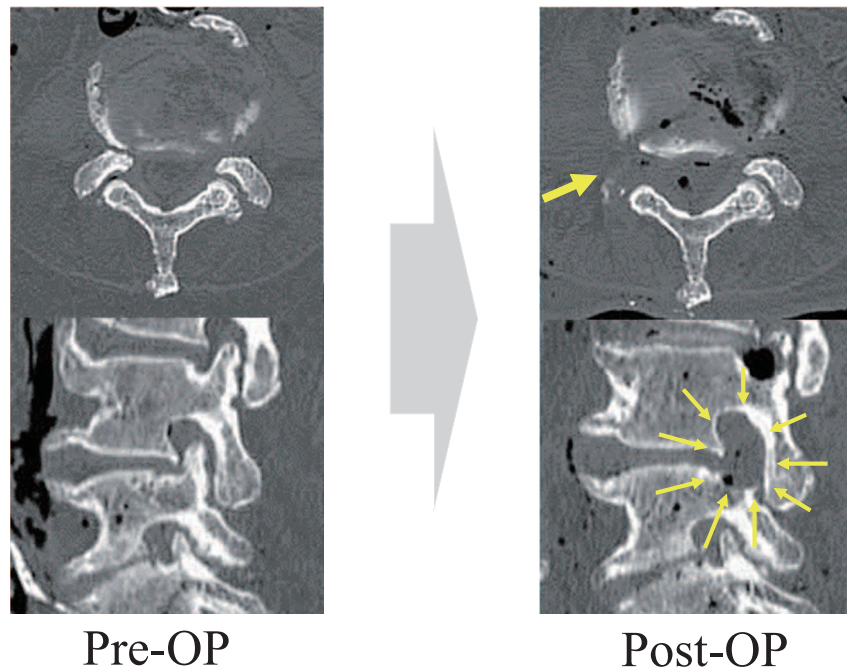


Figure 7 : Sagittal and axial CT scans through the facet joint before and after ventral facetectomy in a cadaver model. After the surgery, the SAP of L5 was completely removed, so that the lateral recess was enlarged. These CT scans clearly demonstrate that simultaneous lateral recess and foraminal decompression would be possible by the TF-PED approach.

REFERENCES

- Foley KT, Smith MM : Microendoscopic discectomy. *Tech Neurosurg* 3 : 301-307, 1997
- Destandeu J : Technical features of endoscopic surgery for lumbar disc herniation : 191 patients. *Neurochirurgie* 50(1) : 6-10, 2004
- Sairoy K, Sakai T, Higashino K, Inoue M, Yasui N, Dezawa A : Complications of endoscopic lumbar decompression surgery. *Minim Invasive Neurosurg* 53(4) : 175-8, 2010
- Minamide A, Yoshida M, Yamada H, Nakagawa Y, Hashizume H, Iwasaki H, Tsutsui S : Clinical outcomes after microendoscopic laminotomy for lumbar spinal stenosis : a 5-year follow-up study. *Eur Spine J* 24(2) : 396-403, 2015
- Hijkata S : Percutaneous nucleotomy. A new concept technique and 12 years' experience. *Clin Orthop Relat Res* 238 : 9-23, 1989
- Kambin P, Schaffer JL : Percutaneous lumbar discectomy. Review of 100 patients and current practice. *Clin Orthop Relat Res* 238 : 24-34, 1989
- Schreiber A, Leu H : Percutaneous nucleotomy : technique with discoscopy. *Orthopedics* 14(4) : 439-44, 1991
- Yeung AT : The evolution of percutaneous spinal endoscopy and discectomy : state of the art. *Mt Sinai J Med* 67 : 327-32, 2000
- Yeung AT, Tsou PM : Posterolateral endoscopic excision for lumbar disc herniation : Surgical technique, outcome, and complications in 307 consecutive cases. *Spine* 27 : 722-31, 2002
- Yeung AT, Yeung CA : Minimally invasive techniques for the management of lumbar disc herniation. *Orthop Clin North Am* 38(3) : 363-72, 2007
- Dezawa A, Sairoy K : New minimally invasive endoscopic discectomy technique through the interlaminar space using a percutaneous endoscope. *Asian J Endosc Surgery* 4(2) : 94-98, 2011
- Koga S, Sairoy K, Shibuya I, Kanamori Y, Kosugi T, Matsumoto H, Kitagawa Y, Sumita T, Dezawa A : Minimally invasive removal of a recurrent lumbar herniated nucleus pulposus by the small incised microendoscopic discectomy interlaminar approach. *Asian J Endosc Surg* 5(1) : 34-7, 2012
- Steurer J, Roner S, Gnannt R, Hodler J : Quantitative radiologic criteria for the diagnosis of lumbar spinal stenosis : a systematic literature review. *BMC Musculoskelet Disord* 12 : 175, 2011
- Yeung A, Gore S : Endoscopic foraminal decompression for failed back surgery syndrome under local anesthesia. *Int J Spine Surg*. 2014 Dec 1 ; 8. doi : 10.14444/1022. eCollection 2014
- Ahn Y, Oh HK, Kim H, Lee SH, Lee HN : Percutaneous endoscopic lumbar foraminotomy : an advanced surgical technique and clinical outcomes. *Neurosurgery* 75(2) : 124-33 ; discussion 132-3, 2014
- Ruetten S, Komp M, Merk H, Godolias G : Use of newly developed instruments and endoscopes : full-endoscopic resection of lumbar disc herniations via the interlaminar and lateral transforaminal approach. *J Neurosurg Spine* 6(6) : 521-530, 2007
- Henmi T, Terai T, Hibino N, Yoshioka S, Kondo K, Goda Y, Tezuka F, Sairoy K : Percutaneous endoscopic lumbar discectomy utilizing ventral epiduroscopic observation technique and foraminoplasty for transligamentous extruded nucleus pulposus : technical note. *J Neurosurg Spine* 13 : 1-6, 2015
- Choi I, Ahn JO, So WS, Lee SJ, Choi IJ, Kim H : Exiting root injury in transforaminal endoscopic discectomy : preoperative image considerations for safety. *Eur Spine J* 22(11) : 2481-7, 2013
- Sairoy K, Matsuura T, Higashino K, Sakai T, Takata Y, Goda Y, Suzue N, Hamada D, Goto T, Nishisho T, Sato R, Tsutsui T, Tonogai I, Mineta K : Surgery related complications in percutaneous endoscopic lumbar discectomy under local anesthesia. *J Med Invest* 61(3-4) : 264-9, 2014

20. Ruetten S, Komp M, Godolias G : An extreme lateral access for the surgery of lumbar disc herniations inside the spinal canal using the full-endoscopic uniportal transforaminal approach-technique and prospective results of 463 patients. *Spine (Phila Pa 1976)* 30(22) : 2570-2578, 2005
21. Lee SH, Kang HS, Choi G, Kong BJ, Ahn Y, Kim JS, Lee HY : Foraminoplastic ventral epidural approach for removal of extruded herniated fragment at the L5-S1 level. *Neurol Med Chir (Tokyo)* 50(12) : 1074-8, 2010
22. Li Z, Hou S, Shang W, Song K, Zhao H : New instrument for percutaneous posterolateral lumbar foraminoplasty : case series of 134 with instrument design, surgical technique and outcomes. *Int J Clin Exp Med* 8(9) : 14672-9, 2015
23. Choi KC, Park CK Percutaneous Endoscopic Lumbar Discectomy for L5-S1 Disc Herniation : Consideration of the Relation between the Iliac Crest and L5-S1 Disc. *Pain Physician* 19(2) : E301-8, 2016
24. Lee SH, Kang HS, Choi G, Kong BJ, Ahn Y, Kim JS, Lee HY : Foraminoplastic ventral epidural approach for removal of extruded herniated fragment at the L5-S1 level. *Neurol Med Chir (Tokyo)* 50(12) : 1074-1078, 2010
25. Abe M, Takata Y, Higashino K, Sakai T, Matsuura T, Suzue N, Hamada D, Goto T, Nishisho T, Goda Y, Tsutsui T, Tonogai I, Miyagi R, Morimoto M, Mineta K, Kimura T, Nitta A, Hama S, Higuchi T, C Jha S, Takahashi R, Fukuta S, Sairyo K : Foraminoplastic transforaminal percutaneous endoscopic discectomy at the lumbosacral junction under local anesthesia in an elite rugby player. *J Med Invest* 62(3-4) : 238-41, 2015
26. Ruetten S, Komp M, Merk H, Godolias G : Surgical treatment for lumbar lateral recess stenosis with the full-endoscopic interlaminar approach versus conventional microsurgical technique : a prospective, randomized, controlled study. *J Neurosurg Spine* 10(5) : 476-85, 2009
27. Komp M, Hahn P, Merk H, Godolias G, Ruetten S : Bilateral operation of lumbar degenerative central spinal stenosis in full-endoscopic interlaminar technique with unilateral approach : prospective 2-year results of 74 patients. *J Spinal Disord Tech* 24(5) : 281-7, 2011
28. Komp M, Hahn P, Oezdemir S, Giannakopoulos A, Heikenfeld R, Kasch R, Merk H, Godolias G, Ruetten S : Bilateral spinal decompression of lumbar central stenosis with the full-endoscopic interlaminar versus microsurgical laminotomy technique : a prospective, randomized, controlled study. *Pain Physician* 18(1) : 61-70, 2015
29. Dezawa A : Office-based surgery for the percutaneous endoscopic laminectomy and discectomy (In Japanese). *Orthopaedic Surgery and Traumatology* 59 : 254-259, 2016
30. Dezawa A, Mikami H, Sairyo K : Percutaneous endoscopic translaminar approach for herniated nucleus pulposus in the hidden zone of the lumbar spine. *Asian J Endosc Surgery* 5(4) : 200-203, 2011
31. Sairyo K, Egawa H, Matsuura T, Takahashi M, Higashino K, Sakai T, Suzue N, Hamada D, Goto T, Takata Y, Nishisho T, Goda Y, Sato R, Tsutsui T, Tonogai I, Kondo K, Tezuka F, Mineta K, Sugiura K, Takeuchi M, Dezawa A : State of the art : Transforaminal approach for percutaneous endoscopic lumbar discectomy under local anesthesia. *J Med Invest* 61(3-4) : 217-25, 2014
32. Kitahama Y, Sairyo K, Dezawa A : Percutaneous endoscopic transforaminal approach to decompress the lateral recess in an elderly patient with spinal canal stenosis, herniated nucleus pulposus and pulmonary comorbidities. *Asian J Endosc Surg* 6(2) : 130-3, 2013