

## ORIGINAL

# Reduction mammoplasty and mastopexy for the contralateral breast after reconstruction surgery following cancer resection : A report of 3 cases

Keisuke Kashiwagi, Yoshiro Abe, Soshi Ishida, Kazuhide Mineda, Yutaro Yamashita, Yutaka Fukunaga, Sho Yoshimoto, Ryosuke Yamato, Tatsuya Tsuda, and Ichiro Hashimoto

*Department of Plastic and Reconstructive Surgery, Institute of Biomedical Sciences, Tokushima University Graduate School, Tokushima, Japan*

**Summary : Background :** Breast reconstruction generally involves autologous tissue transplantation and placement of a mammary prosthesis. When the patient's breasts are extremely large and ptotic, breast reconstruction often results in significantly asymmetrical appearance. However, a good aesthetic outcome after reconstruction surgery following cancer resection is an important quality-of-life factor. We evaluated the efficacy of touch-up surgery, either reduction mammoplasty or mastopexy, performed on the contralateral breast for symmetrization. **Methods :** Reduction mammoplasty was performed on the contralateral breast in 2 patients and mastopexy was performed on the contralateral breast in 1 patient after reconstruction surgery following cancer resection, between 2008 and 2014. We reviewed each patient's medical record for general clinical information and for the methods of breast cancer resection and breast reconstruction used, wait time between breast cancer resection and touch-up surgery, preservation of the sensitivity of the nipple-areola complex after the touch-up surgery, and aesthetic outcome (based on visual analog scale score). **Results :** Wait times in the 3 cases were 4, 9, and 18 months. Nipple-areolar sensitivity was well preserved in all 3 cases. Aesthetic outcomes were judged "excellent" or "very good." **Conclusion :** Revision surgery on the contralateral breast 4 to 18 months after breast reconstruction substantially improves the aesthetic outcome. *J. Med. Invest.* 63 : 281-285, August, 2016

**Keywords :** reduction mammoplasty, mastopexy, touch-up surgery, breast cancer, breast reconstruction

## INTRODUCTION

The incidence of breast cancer in Japan has been gradually increasing (1, 2). Although the age at which women are most susceptible to breast cancer is lower than that for other cancers (3), the 5-year post-treatment survival rate in breast cancer is favorable in comparison to that in many other cancers. Thus, the prognosis of patients with breast cancer is relatively good. Therefore, patients' postoperative quality of life is important, and a good aesthetic outcome after reconstruction surgery following cancer resection is a major quality-of-life factor. Symmetrical appearance after breast reconstruction contributes mainly to aesthetic outcome. Some form of "touch-up" surgery is required before and/or after reconstructive surgery in order to improve breast symmetry and patient satisfaction. Touch-up surgery is normally performed on the reconstructed breast and includes repositioning the mound, augmentation with fat grafting, and reduction with liposuction. However, it is sometimes performed on the contralateral breasts and includes modifying the shape, position, and size of the contralateral breasts.

Breast reconstruction is of two general types, namely autologous tissue transplantation and placement of a mammary prosthesis, which is generally a silicone implant. Autologous tissue transplantation is limited by the volume of available tissue, which is related to the patient's body mass index (BMI). A mammary prosthesis can be adjusted to the size of the breast, but for a markedly ptotic breast, the original appearance of the breast cannot be mimicked using

a mammary prosthesis. When the patient's breasts are extremely large or ptotic, breast reconstruction can result in significantly asymmetrical appearance. When obvious asymmetry results from unilateral breast reconstruction, we apply reduction mammoplasty or mastopexy to the contralateral side as a delayed touch-up surgery. We reviewed touch-up surgeries performed at our hospital to evaluate the efficacies of reduction mammoplasty and mastopexy performed for breast symmetrization on the contralateral side.

## PATIENTS AND METHODS

We performed unilateral breast reconstruction in 14 patients treated with breast cancer resection at Tokushima University Hospital, between January 2008 and December 2014. Three of the 14 patients underwent touch-up surgery for the contralateral breast. In two of these 3 patients, reduction mammoplasty was performed using the method reported by Georgiade *et al.* (4). In the third patient, mastopexy was performed using the method reported by Weiner *et al.* (5).

We were granted access to the medical records of the 3 patients by the Department of Plastic and Reconstructive Surgery of Tokushima University Hospital. The study was approved by the ethics committee of Tokushima University Hospital (No. 2607). We collected and evaluated the following patient information : age, height and weight, methods of breast cancer resection and breast reconstruction, the wait time (months) between breast cancer resection and touch-up surgery, preservation of the sensitivity of the nipple-areolar complex after the touch-up surgery, and aesthetic outcome. The aesthetic outcome after the touch-up surgery was evaluated using the visual analog scale (Table 1) proposed by Tomita *et al.* (6).

Received for publication November 30, 2015 ; accepted July 29, 2016.

Address correspondence and reprint requests to Ichiro Hashimoto, MD, PhD, Department of Plastic and Reconstructive Surgery, Tokushima University Graduate School, 3-18-15 Kuramoto, Tokushima 770-8503, Japan and Fax : +81-88-633-7297.

Table 1. Visual analogue scale\*

	Score
Breast size	2 (symmetric) to 0 (asymmetric)
Breast shape	2 (symmetric) to 0 (asymmetric)
Breast scar	2 (barely visible) to 0 (clearly visible)
NAC size, shape	1 (symmetric) or 0 (asymmetric)
NAC color	1 (symmetric) or 0 (asymmetric)
NAC position	1 (symmetric) or 0 (asymmetric)
Most inferior point of breast	1 (symmetric) or 0 (asymmetric)
Total	10-9 : excellent, 8-7 : very good, 6-5 : good, 4-3 : fair, 2-0 : poor

NAC : nipple-areola complex.

\*as described by Tomita K *et al.* (6).

### Reduction Mammoplasty Procedure

Reduction mammoplasty is a procedure for reducing the size of large and ptotic breasts. It includes resection of excess breast parenchyma and transposition of the nipple-areola complex higher on the breast hemisphere. For reduction mammoplasty, a new, lifted-up nipple-areola complex position is determined preoperatively and marked on the contralateral breast, with the patient in a standing position. During surgery, superfluous skin is marked and resected along with fatty tissue and part of the mammary gland around the pedicle nipple-areolar flap. The blood supply for the nipple-areolar flap is from the inferior soft tissue pedicle containing perforator vessels on the pectoralis major muscle. The epidermis of the nipple-areolar flap is denuded, except for the nipple-areola complex itself. The nipple-areola complex is pulled up and sutured to the previously marked site. Ultimately, the skin envelope of the breast is sutured below the elevated nipple-areola.

### Mastopexy Procedure

Mastopexy is a procedure for lifting ptotic breasts by correcting the breast contour and elevating the nipple-areola complex. It does not include volume reduction. For mastopexy, a new nipple-areolar site is marked preoperatively on the patient's contralateral breast, as described earlier. During surgery, superfluous skin is resected, but the mammary gland around the nipple-areolar pedicle is not resected. The nipple-areolar flap is nourished from the superior soft tissue pedicle containing perforator vessels on the pectoralis major muscle. The nipple-areola complex is pulled up and sutured to the previously marked site. Ultimately, the skin envelope of the breast is sutured below the elevated nipple-areola (Figure 1).

## RESULTS

The clinical characteristics, cancer resection surgeries, and touch-up surgeries with the results in all 3 patients are shown in Table 2. The patients were 51, 54, and 61 years of age. According to body mass index (BMI), Patient 1 was of normal weight, Patient 2 was overweight, and Patient 3 was obese. Patient 1 had undergone Halstead radical mastectomy, by which the pectoralis major and pectoralis minor were removed. Patient 2 had undergone modified radical mastectomy, in which both pectoralis muscles were preserved. Patient 1 had undergone delayed reconstruction with a pedicled transverse rectus abdominis musculocutaneous (TRAM) flap; the left deep inferior epigastric vessels were anastomosed with the left thoracodorsal vessels so that the entire flap would survive and the reconstructed breast could be made as large as possible. Patient 2 had also undergone delayed reconstruction with a free deep inferior epigastric perforator flap; the flap vessels were anastomosed with the left thoracodorsal vessels so that the

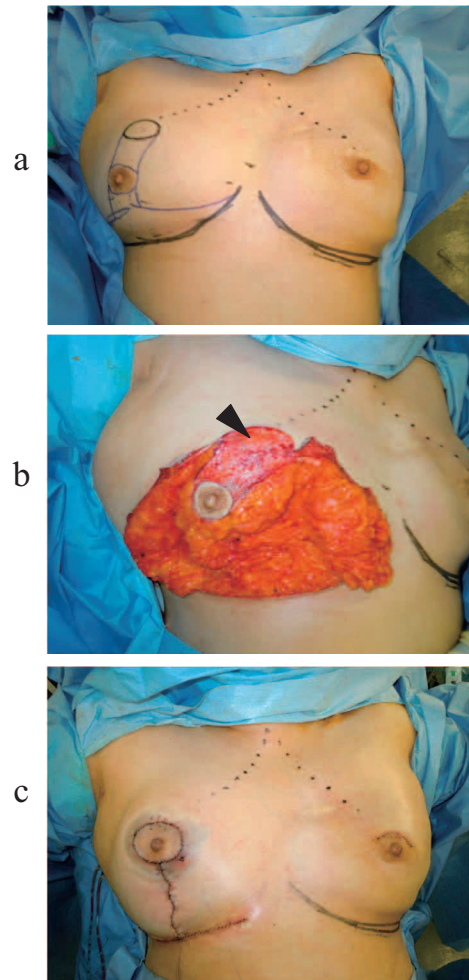


Figure 1. Schematic diagram of the mastopexy performed for patient 3. (a) Preoperative design : A new nipple-areola position and the excessive skin to be resected are marked. (b) Intraoperative findings : Superfluous skin is resected, excluding breast parenchyma. The nipple-areolar complex is nourished from the superior pedicle on which the epidermis is denuded (indicated with an arrowhead). (c) Immediate postoperative findings : The nipple-areola complex is sutured to the same position as the reconstructed breast. The skin envelope of the breast is sutured in a reversed-T shape.

reconstructed breast could be made as large as possible. However, the reconstructed breast did not match the contralateral breast in volume in either Patient 1 or Patient 2, so reduction mammoplasty was performed (Figures 2 and 3) at 4 and 9 months, respectively.

Table 2. Patients, procedures, and outcomes

	Patient 1	Patient 2	Patient 3
Age (years)	51	61	54
Height (cm)	159	151	152
Weight (kg)	60	60	71
Body mass index (kg/m <sup>2</sup> )	23.7	26.3	30.7
Method of cancer excision	Radical mastectomy	Muscle-preserving radical mastectomy	Nipple-sparing mastectomy
Immediate or delayed breast reconstruction	Delayed	Delayed	Immediate
Method of breast reconstruction	Pedicled TRAM flap+ supercharging	Free DIEP flap	Tissue expander → implant
Touch-up surgery method	Reduction mammoplasty	Reduction mammoplasty	Mastopexy
Period between reconstruction and touch-up surgery	4 months	9 months	18 months
Nipple-areola sensitivity	Preserved	Preserved	Preserved
Aesthetic outcome after touch-up surgery (VAS score)	9/10 Excellent	9/10 Excellent	8/10 Very good

TRAM : transverse rectus abdominis musculocutaneous ; DIEP : deep inferior epigastric perforator ; VAS : visual analogue scale.

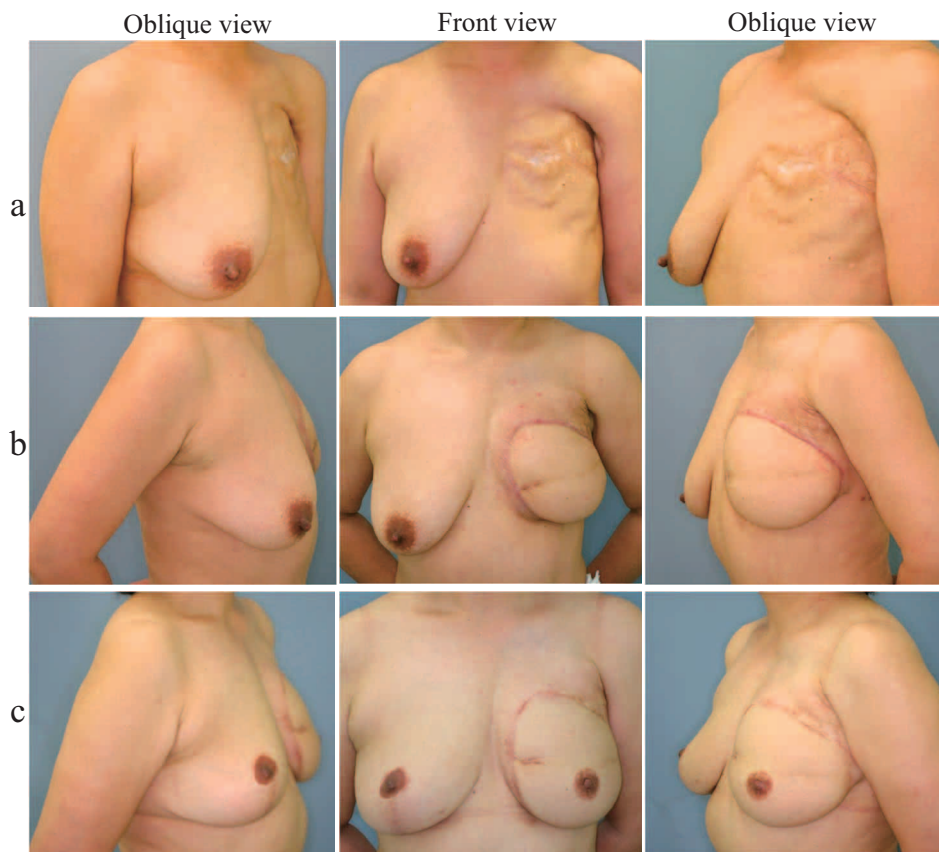
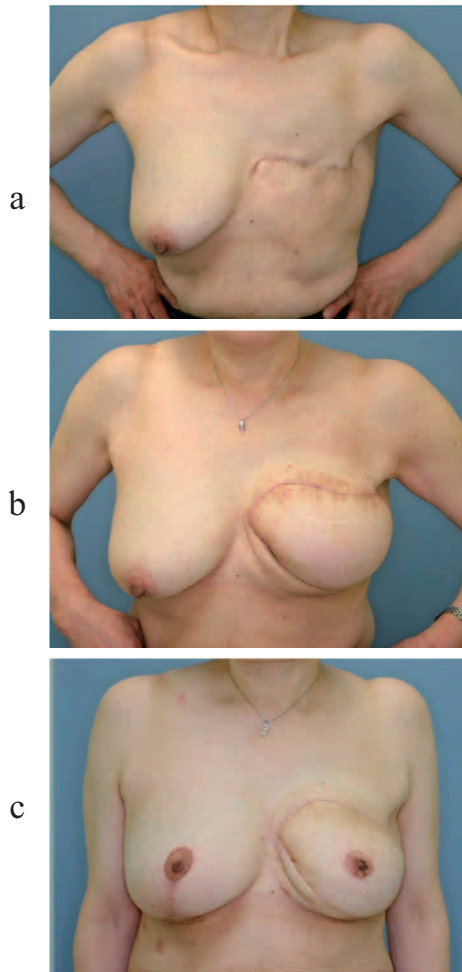


Figure 2. Patient 1 (reduction mammoplasty). (a) Before breast reconstruction. Rib bones can be seen under the thin breast skin because the pectoralis major and minor muscles were removed. (b) Three months after reconstruction of the left breast. The pedicled transverse rectus abdominis musculocutaneous flap was transplanted to the upper portion of the breast and axilla to fill the soft tissue defect. Breast on the contralateral side droops considerably in comparison to the reconstructed breast. (c) Three years after reduction mammoplasty. The nipple-areola complex on the reconstructed breast was transplanted from the contralateral side when the reduction mammoplasty was performed.

Patient 3 had undergone nipple-sparing mastectomy and immediate reconstruction with a silicone implant. Ptosis of the contralateral breast was significant, so mastopexy was performed 18 months after the mastectomy (Figure 4). The sensitivity of the

nipple-areola complex was good in all 3 patients. The aesthetic outcomes were judged “excellent” or “very good”, according to the visual analog scale.

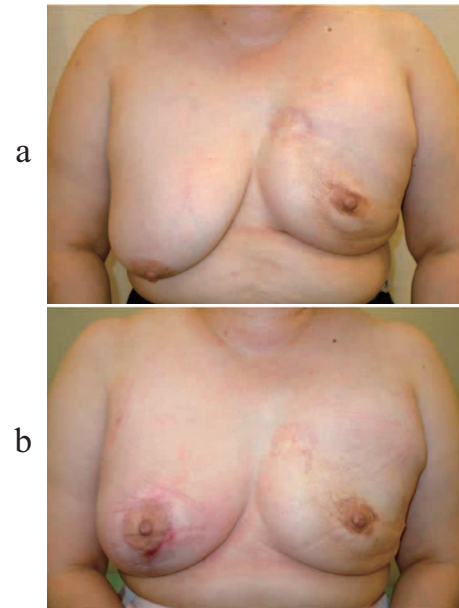


**Figure 3.** Patient 2 (reduction mammoplasty). (a) Before the breast reconstruction. (b) Five months after reconstruction of the left breast. The left breast was reconstructed with a free deep inferior epigastric perforator flap. Breast on the contralateral side droops considerably in comparison to the reconstructed breast. (c) One year after reduction mammoplasty. The nipple-areola complex on the reconstructed breast was transplanted from the contralateral side when the reduction mammoplasty was performed.

## DISCUSSION

In Western countries, reports on reduction mammoplasty and mastopexy for the contralateral breast after unilateral breast reconstruction are fairly numerous (7-14). Touch-up surgery for contralateral breasts has been rarely reported in Japan. As the breasts of Japanese women are, on average, smaller than those of Western women, the reconstructed breast is usually provided adequate volume with a latissimus dorsi or rectus abdominis musculocutaneous flap. The 3 patients described herein all had large ptotic breasts with significant asymmetry after breast reconstruction.

Reducing the mammary gland and fatty tissue while preserving both the original blood supply and sensitivity of the nipple-areola complex is key to successful reduction mammoplasty and mastopexy. Various techniques have been reported in attempts to improve these important steps. The resulting procedures are categorized according to the origin of the pedicle. Weiner *et al.* (5) described a procedure by which the nipple-areolar flap receives its blood supply from the superior pedicle. Ribeiro (15), Robbins (16), Courtiss *et al.* (17), and Georgiade *et al.* (4) described the use of the



**Figure 4.** Patient 3 (mastopexy). (a) Six months after reconstruction of the left breast. Reconstruction with a silicone implant was performed immediately after nipple-sparing mastectomy. Breast on the contralateral side droops considerably in comparison to the reconstructed breast. (b) Two months after the mastopexy.

inferior pedicle. McKissock (18) and Strömbeck (19) advocated the use of a bipedicle flap for provision of more reliable blood supply. The 2 reduction mammoplasties we performed were according to Georgiade's procedure, that is, by the inferior pedicle flap method. We chose this procedure because it allows for preservation of both nipple-areolar circulation and sensation (20) despite removal of a large amount of breast tissue. Our third patient, whose breasts were considerably ptotic, underwent mastopexy performed according to Weiner's procedure, that is, the superior pedicle flap method. We chose this procedure because it allows firm fixation of the nipple-areola complex at the elevated position, maintenance of breast projection, and preservation of fullness at the upper site of the breast (21). Weiner's procedure tends to result in loss of nipple-areolar sensitivity; therefore, we elevated the superior pedicle flap without dissecting it from the pectoralis major muscle. This way, we were able to preserve the cutaneous branches of 3 to 5 intercostal nerves and the sensitivity of the nipple-areola complex in our patient.

Touch-up surgery for the contralateral breast is sometimes performed at the time of or even before the breast reconstruction surgery (11-14). In our institute, we perform touch-up surgeries 4 to 18 months after the breast reconstruction. In our 3 patients, objective evaluation after the touch-up surgery showed excellent outcomes. We believe that symmetrical appearance can be attained easily with delayed touch-up surgery because the waiting period allows for maturation of the scar of the reconstructed breast.

## CONFLICT OF INTEREST

This study was supported by departmental resources only. The authors have no conflicts of interest to report.

## REFERENCES

1. Taira N, Arai M, Ikeda M, Iwasaki M, Okamura H, Takamatsu K, Yamamoto S, Ohsumi S, Mukai H : The Japanese Breast Cancer Society clinical practice guideline for epidemiology and prevention of breast cancer. *Breast Cancer* 22 : 16-27, 2015
2. DeSantis CE, Bray F, Ferlay J, Lortet-Tieulent J, Anderson BO, Jemal A : International variation in female breast cancer incidence and mortality rates. *Cancer Epidemiol Biomarkers Prev* 24 : 1495-506, 2015
3. Matsuda A, Matsuda T, Shibata A, Katanoda K, Sobue T, Nishimoto H : Cancer incidence and incidence rates in Japan in 2007 : a study of 21 population-based cancer registries for the Monitoring of Cancer Incidence in Japan (MCIJ) project. *Jpn J Clin Oncol* 43 : 328-336, 2013
4. Georgiade NG, Serafin D, Morris R, Georgiade G : Reduction mammoplasty utilizing an inferior pedicle nipple-areolar flap. *Ann Plast Surg* 3 : 211-218, 1979
5. Weiner DL, Aiache AE, Silver L, Tittiranonda T : A single dermal pedicle for nipple transposition in subcutaneous mastectomy, reduction mammoplasty, or mastopexy. *Plast Reconstr Surg* 51 : 115-120, 1973
6. Tomita K, Yano K, Matsuda K, Takada A, Hosokawa K : Esthetic outcome of immediate reconstruction with latissimus dorsi myocutaneous flap after breast-conservative surgery and skin-sparing mastectomy. *Ann Plast Surg* 61 : 19-23, 2008
7. Delay E, Jorquera F, Pasi P, Gratadour AC : Autologous latissimus breast reconstruction in association with the abdominal advancement flap : a new refinement in breast reconstruction. *Ann Plast Surg* 42 : 67-75, 1999
8. Losken A, Carlson GW, Bostwick J, Jones GE, Culbertson JH, Schoemann M : Trends in unilateral breast reconstruction and management of the contralateral breast : the Emory experience. *Plast Reconstr Surg* 110 : 89-97, 2002
9. Leone MS, Priano V, Franchelli S, Puggioni V, Merlo DF, Mannucci M, Santiet PL : Factors affecting symmetrization of the contralateral breast : a 7-year unilateral postmastectomy breast reconstruction experience. *Aesth Plast Surg* 35 : 446-451, 2011
10. Schneider LF, Chen CM, Stolier AJ, Shapiro RL, Allen RJ : Nipple-sparing mastectomy and immediate free-flap reconstruction in the large ptotic breast. *Ann Plast Surg* 69 : 425-428, 2012
11. Hudson DA, Skoll PJ : Complete one-stage, immediate breast reconstruction with prosthetic material in patients with large or ptotic breasts. *Plast Reconstr Surg* 110 : 487-493, 2002
12. Huang JJ, Wu CW, Lam WL, Lin CY, Nguyen DH, Cheng MH : Simultaneous contralateral breast reduction/mastopexy with unilateral breast reconstruction using free abdominal flaps. *Ann Plast Surg* 67 : 336-342, 2011
13. Chang EI, Lamaris G, Chang DW : Simultaneous contralateral breast reduction mammoplasty or mastopexy during unilateral free breast reconstruction. *Ann Plast Surg* 71 : 144-148, 2013
14. Rizki H, Nkonde C, Ching RC, Kumiponjera D, Malata CM : Plastic surgical management of the contralateral breast in post-mastectomy breast reconstruction. *Int J Surg* 11 : 767-772, 2013
15. Ribeiro L : A new technique for reduction mammoplasty. *Plast Reconstr Surg* 55 : 330-334, 1975
16. Robbins TH : A reduction mammoplasty with the areola-nipple based on an inferior dermal pedicle. *Plast Reconstr Surg* 59 : 64-67, 1977
17. Courtiss EH, Goldwyn RM : Reduction mammoplasty by the inferior pedicle technique : an alternative to free nipple and areola grafting for severe macromastia or extreme ptosis. *Plast Reconstr Surg* 59 : 500-507, 1977
18. McKissock PK : Reduction mammoplasty by the vertical bipedicle flap technique : rationale and results. *Clin Plast Surg* 3 : 309-320, 1976
19. Strömbeck JO : Mammoplasty : report of a new technique based on the two-pedicle procedure. *Br J Plast Surg* 13 : 79-90, 1960
20. Wong C, Vucovich M, Rohrich R : Mastopexy and reduction mammoplasty pedicles and skin resection patterns. *Plast Reconstr Surg Glob Open* 2 : e202, 2014
21. Chiummariello S, Angelisanti M, Arleo S : Evaluation of the sensitivity after reduction mammoplasty : our experience and review of the literature. *Ann Ital Chir* 84 : 385-388, 2013