

CASE REPORT

Efficacy of Achilles Suture Bridge Technique for Insertional Achilles Tendinosis in an Obese and Athletic Patient

Kazuaki Mineta, Naoto Suzue, Tetsuya Matsuura, and Koichi Sairyō

Department of Orthopedics, Institute of Biomedical Sciences, Tokushima University Graduate School, Tokushima, Japan

Abstract : Here, we report the efficacy of the suture bridge technique for treating insertional Achilles tendinosis in an obese and athletic patient. A 48-year-old man presented to our department with a 6-month history of left posterior heel pain. The patient was an athlete (triathlon) and appeared obese (height : 197 cm, body weight : 120 kg, body mass index : 30.9). A diagnosis of insertional Achilles tendinosis was made. Because 6 months of conservative treatments had failed, we performed open resection of the calcaneal exostosis and Haglund's deformity along with debridement of the degenerative tissue of the tendon. Wide detachment of the insertion of the Achilles tendon was necessary, and reattachment of the tendon was performed using the Arthrex SpeedBridge™ system (Arthrex, Inc., Naples, FL). Six weeks postoperatively, this patient was allowed to walk with full weight bearing. Twelve weeks after surgery, this patient started jogging with neither pain nor evidence of Achilles tendon rupture. The suture bridge technique was effective for the reconstruction of the Achilles tendon in an obese and athletic patient. *J. Med. Invest.* 63 : 310-314, August, 2016

Keywords : *Insertional Achilles tendinosis, Haglund's deformity, Suture bridge technique*

INTRODUCTION

Insertional Achilles tendinosis is characterized by degeneration of the tendon at the junction of the tendon and the calcaneus (1). The symptoms are pain and swelling along the distal insertion of the tendon (2). This disease is commonly seen in running athletes ; however, patients of all ages and activity levels can be affected (3). Further, this disease is linked to the presence of certain medical factors, such as diabetes mellitus and morbid obesity (3).

Insertional Achilles tendinosis is frequently associated with Haglund's deformity (a prominent posterior calcaneal exostosis), retrocalcaneal bursitis, and Achilles tendon calcifications (2). Surgical treatment for insertional Achilles tendinosis are warranted after a 3- to 6-month trial of conservative management, such as activity modification, nonsteroidal anti-inflammatory medications, custom orthotic devices, heel lifts, and cast or boot immobilization (3, 4). An endoscopic approach is excellent for only decompressing the retrocalcaneal region ; however, it is difficult to address the debridement of degenerative tissue or calcifications in the Achilles tendon via endoscopy (3, 4). An open approach, involving detachment from the calcaneus and splitting of the Achilles tendon, enables us to perform debridement of the degenerative region (3, 4). However, it has been reported that reattachment of the Achilles tendon is necessary to prevent rupture if greater than 50% of the tendon is detached (4, 5).

We report here a case of surgical treatment for insertional Achilles tendinosis in an obese and athletic patient. We performed debridement of the degenerative tissue of the tendon and resection of Haglund's deformity after we detached approximately 60% of the tendon. We selected the Arthrex SpeedBridge™ system (Arthrex, Inc., Naples, FL) for reattachment and achieved good clinical results.

Received for publication April 12, 2016 ; accepted June 18, 2016.

Address correspondence and reprint requests to Naoto Suzue, MD, PhD, Department of Orthopedics, Institute of Biomedical Sciences, Tokushima University Graduate School 3-18-15 Kuramoto-cho, Tokushima 770-8503, Japan and Fax : +81-88-633-0178.

While many reports have described the efficacy of this device, we consider that this is the first report of using this device for treating insertional Achilles tendinosis in an obese and athletic patient.

CASE REPORT

A 48-year-old man presented to our department with a 6-month history of left posterior heel pain. He was an athlete (triathlon), with a high level of daily activity ; however, he appeared obese (height : 197 cm, body weight : 120 kg, body mass index : 30.9). The pain was exacerbated by physical activity, and the pain had progressed to the point that it was occurring almost daily and merely wearing a shoe exacerbated this discomfort. His past medical history was unremarkable.

Physical examination revealed tenderness, swelling, and slight redness over the site of the Achilles tendon insertion. He had a normal range of motion and motor strength for the ankle but experienced pain on resisted ankle plantar flexion. The neurological and vascular examinations showed no abnormal findings.

Plain radiography and three-dimensional (3D)-computed tomography (CT) demonstrated a slight Haglund's deformity with a wide retrocalcaneal exostosis, fracture of this exostosis, and the presence of a bone fragment in the Achilles tendon (Figure 1). Plain magnetic resonance imaging (MRI) demonstrated a calcaneal exostosis and insertional Achilles tendinosis (Figure 2).

Since conservative treatment for 6 months had not been effective, this patient desired surgical management for insertional Achilles tendinosis. Under general anesthesia, the patient was placed in a prone position. A well-padded pneumatic tourniquet was placed around the thigh of the affected ipsilateral lower leg. Using a scalpel, a 3-cm midline longitudinal skin incision at the calcaneus was made and a continuous 5-cm longitudinal skin incision was made at the medial side of the Achilles tendon. The skin incision was continued deep through the subcutaneous tissue to the paratenon, maintaining full-thickness skin flaps (Figure 3). The paratenon and the Achilles tendon were sharply incised and opened at about 3

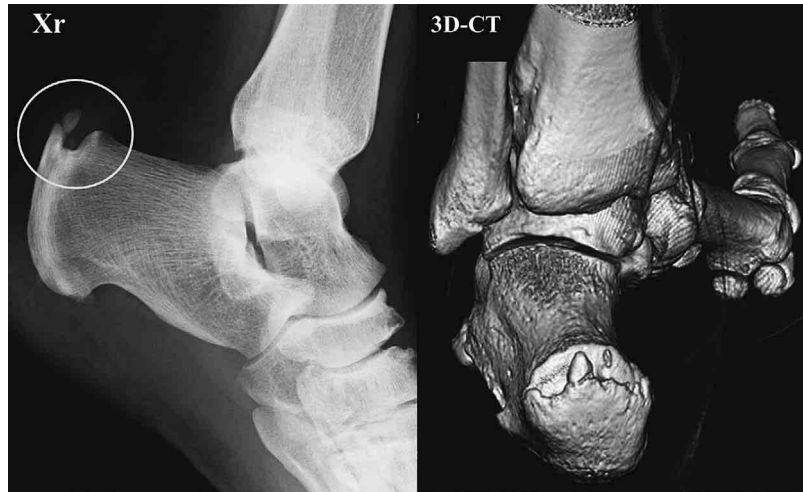

Figure 1 : Plain radiograph reveals Haglund's deformity, calcaneal exostosis, fracture of the exostosis and bone fragment in the Achilles tendon (circle). 3D-CT revealed a wide calcaneal exostosis.

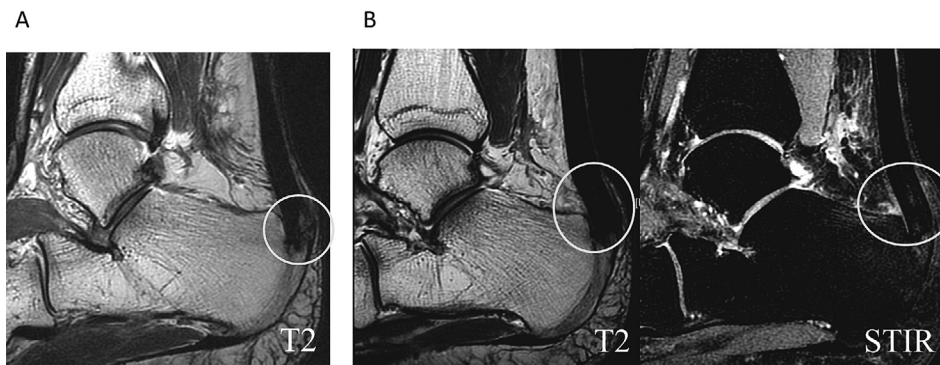


Figure 2
 A : On MRI, a sagittal T2-weighted image shows a posterosuperior calcaneal exostosis (circle).
 B : T2-weighted and STIR images show increased signal intensity in the Achilles tendon around the insertion (circle).

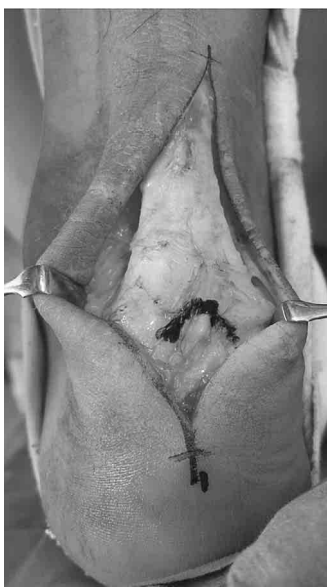

Figure 3 : We made a skin incision as shown here and exposed the paratenon and the Achilles tendon.

cm. Then, approximately 60% of the Achilles tendon was detached from the insertion at the calcaneus, and the calcaneal exostosis and the fracture region were exposed (Figure 4). The degenerative portion at the medial Achilles tendon was sharply debrided and the bone fragment was simultaneously removed (Figure 5). Using a chisel, we performed resection of the exostosis and Haglund's deformity (Figure 6). We ensured complete removal of the bone fragment and appropriate resection of the exostosis and Haglund's deformity.

The Achilles tendon was then reattached to the calcaneus using the Arthrex SpeedBridge™ system (Arthrex, Inc., Naples, FL). Two rows of drill holes were created in the prepared calcaneal surface. Proximally, medial and lateral drill holes measuring 4.5 mm in diameter were made in the calcaneus approximately 2 cm proximal to the most distal aspect of the Achilles footprint. Two additional drill holes were then placed 1.5 cm distal to the first row of drill holes. The drill holes in the proximal row were filled with an interference type screw securing strands of FiberTape™ (Arthrex, Inc., Naples, FL) that were then passed through the distal Achilles tendon on their respective sides. Medial and lateral FiberTape™ arms (one each) were secured into the distal medial drill hole using another interference screw. This was then repeated with the remaining FiberTape™ sutures, securing them into the distal lateral drill hole (Figure 7). This suturing technique of the distal Achilles

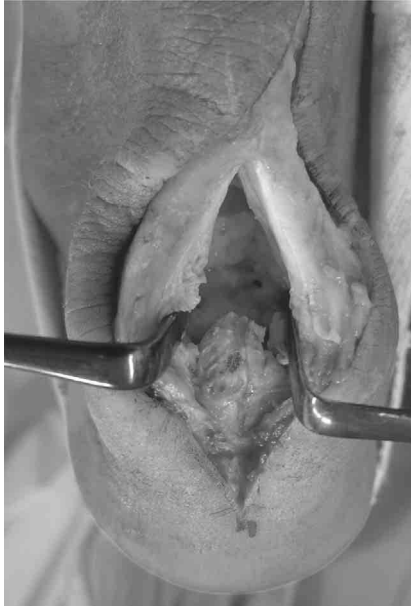

Figure 4 : We performed splitting and detachment of the Achilles tendon and exposed the calcaneal exostosis.

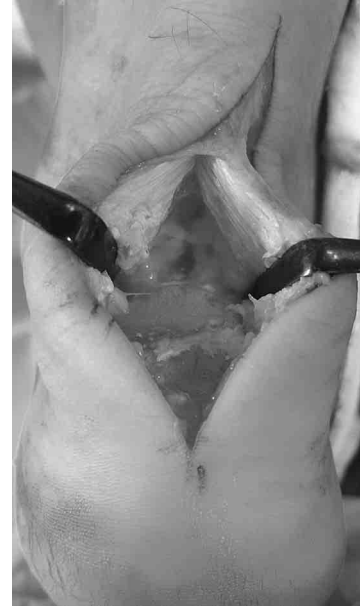

Figure 6 : We performed resection of Haglund's deformity and the calcaneal exostosis.

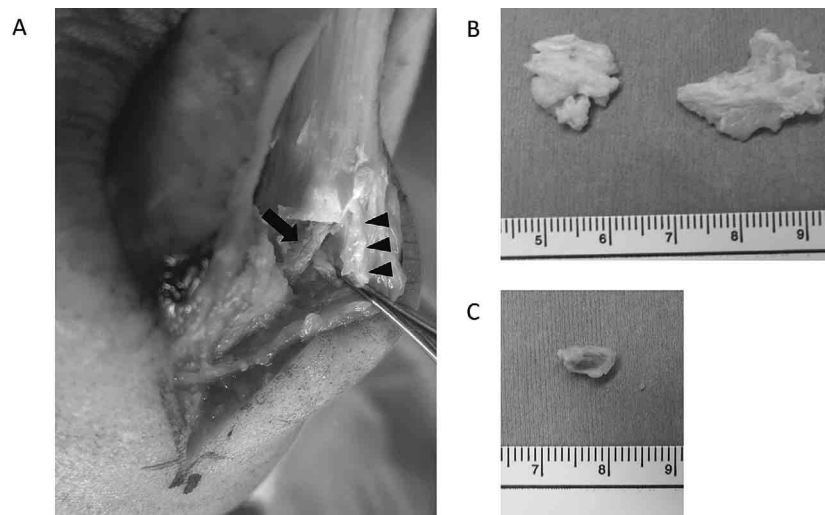


Figure 5

A : We performed removal of the degenerative tissue (arrow head) and bone fragment (arrow).

B : Resected degenerative tissue

C : Resected bone fragment

insertion securely fixed the tendon to the prepared bony surface. The interference screw fixation eliminated the need for a series of bulky knots at the repair site (6). Then, simple interrupted sutures with 4-0 PDS were used to approximate the incised area of the Achilles tendon and paratenon.

The tourniquet was deflated, and we checked for slight bleeding at the operative site. A Penrose drain tube was placed and the subcutaneous layer was approximated with 4-0 PDS in a subcuticular simple interrupted fashion. The skin was closed with 3M Steri-Strips™ and a sterile dressing was applied to the wound ; then, a well-padded, molded posterior splint was placed on the foot in neutral position.

At 2 weeks after surgery, the splint was removed and we checked the healing of the wound. The patient had no complications. The

affected extremity was placed in an Achilles walking boot, and the patient was discharged. Six weeks postoperatively, the boot was removed and the patient was allowed to walk with full weight bearing. The patient was asked to avoid all high-impact activities. Twelve weeks after surgery, the patient was allowed to start jogging. Sixteen weeks after surgery, he could jog 6 km with no pain. At the final follow-up examination at 10 months after surgery, he was able to return to a high level of daily activity, with no evidence of Achilles tendon rupture or device failure using the suture bridge technique.

Postoperative plain radiograph and 3D-CT showed appropriate resection of the exostosis and Haglund's deformity and demonstrated complete removal of the bone fragment (Figure 8).

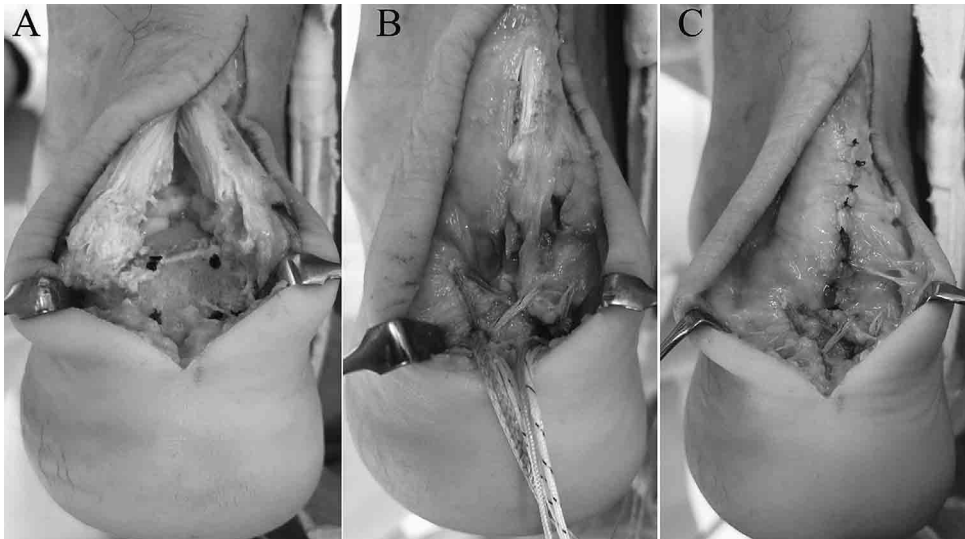


Figure 7

A : We made 2 rows of drill holes (blue marks).

B : We performed reattachment using the speed bridge technique.

C : We cut the strands and sutured the Achilles tendon and paratenon with 4-0 PDS.

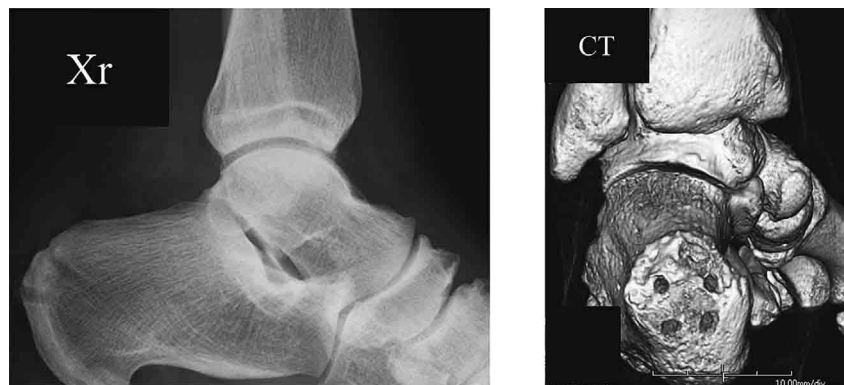

Figure 8 : Postoperative plain radiograph and 3D-CT demonstrate appropriate resection of Haglund's deformity and the calcaneal exostosis along with complete removal of the bone fragment.

DISCUSSION

We have reported a successful case of surgical treatment for insertional Achilles tendinosis in an obese and athletic patient. For this patient, based on preoperative imaging findings, we planned resection of the calcaneal exostosis and Haglund's deformity. In cases requiring only decompression of the retrocalcaneal region, arthroscopic debridement and resection might be suitable. However, in this case, MRI demonstrated degenerative tissue and bone fragment in the Achilles tendon. Therefore, we decided to perform splitting of the Achilles tendon and removal of the bone fragment and degenerative tissue. Because 3D-CT revealed a wide calcaneal exostosis, we considered that wide detachment would be necessary to resect the exostosis.

Cadaveric research performed by Kolodziej *et al.* demonstrated that the Achilles tendon remains stable and without the risk of complete rupture when up to 50% of the tendon is detached (5). Calder and Saxby performed a retrospective review of 52 patients with Achilles tendinosis (7). These patients underwent Achilles tendon debridement and decompression with reattachment of Achilles tendon with sutures if greater than 50% of the tendon was detached.

However, if less than 50% of the tendon was detached, the tendon was not repaired with sutures. At 6 months follow-up, no patients experienced rupture of the Achilles tendon. These reports supported our decision to perform reattachment of the Achilles tendon. Perioperatively, over 50% of the Achilles tendon was detached in our patient. Furthermore, this patient was obese and had a high activity level. Thus, reconstruction of the detached Achilles tendon was thought to be essential in our patient.

With respect to the methods for reattachment of the Achilles tendon, the efficacy of the conventional suture anchor technique has been reported (8-12). However, a new suture bridge technique using the Arthrex SpeedBridge™ system (Arthrex, Inc., Naples, FL) was reviewed by Ryan *et al.* in 43 patients, including 20 athletic patients, who underwent surgical treatment of insertional Achilles tendinosis with reattachment of the Achilles tendon using the suture bridge technique (13). They reported that 42 of 43 patients returned to their activities of daily living, including running in 20 athletic patients (100%). Other reports also demonstrated the efficacy of this new technique (4, 6). In a biomechanical study, Pilson *et al.* reported that they did not find a statistically significant difference in the peak load to failure between the conventional suture

anchor technique and this new suture bridge technique (14). Macias *et al.* (6) mentioned that the use of the conventional suture anchor technique typically left behind prominent knots that were frequently bothersome to patients. Further, they suggested that the suture bridge technique allowed surgeons to more precisely approximate the Achilles footprint and eliminated the need for bulky suture knots that could cause heel pain or discomfort with footwear. Their reports supported our decision to use this new technique.

With regard to postoperative therapy, some reports on the conventional suture anchor technique have advocated no weight bearing for 3-5 weeks (2, 9, 12). Ryan *et al.* advocated no weight bearing for several weeks, and they allowed patients to walk with full weight bearing at approximately 6 weeks after reattachment using the suture bridge technique (13). In our active and obese patient, the period of no weight bearing was 2 weeks, and full weight bearing was started at 6 weeks postoperatively. The patient healed well, and there was no problem in allowing this patient to start jogging after 12 weeks.

CONCLUSION

The suture bridge technique using the Arthrex SpeedBridge™ system (Arthrex, Inc., Naples, FL) was effective for treating insertional Achilles tendinosis in an obese and athletic patient.

CONFLICTS OF INTEREST

The authors declare no conflicts of interest regarding the publication of this paper.

REFERENCE

1. Courville XF, Coe MP, Hecht PJ : Current concepts review : noninsertional Achilles tendinopathy. *Foot Ankle Int* 30 : 1132-1142, 2009
2. DeOrto MJ, Easley ME : Surgical strategies : insertional Achilles tendinopathy. *Foot Ankle Int* 29 : 542-550, 2008
3. Irwin TA : Current concepts review : insertional Achilles tendinopathy. *Foot Ankle Int* 31 : 933-939, 2010
4. Witt BL, Hyer CF : Achilles tendon reattachment after surgical treatment of insertional tendinosis using the suture bridge technique : a case series. *J Foot Ankle Surg* 51 : 487-493, 2012
5. Kolodziej P, Glisson RR, Nunley JA : Risk of avulsion of the Achilles tendon after partial excision for treatment of insertional tendonitis and Haglund's deformity : a biomechanical study. *Foot Ankle Int* 20 : 433-437, 1999
6. Macias DM, Trakas A, Coughlin MJ : Reconstruction of concurrent chronic insertional Achilles tendinosis and chronic midsubstance Achilles tendinosis with Haglund deformity : a case report. *Med Chir Pied* 31 : 53-58, 2015
7. Calder JD, Saxby TS : Surgical treatment of insertional Achilles tendinosis. *Foot Ankle Int* 24 : 119-121, 2003
8. Wagner E, Gould JS, Kneidel M, Fleisig GS, Fowler R : Technique and results of Achilles tendon detachment and reconstruction for insertional Achilles tendinosis. *Foot Ankle Int* 27 : 677-685, 2006
9. DeVries JG, Summerhays B, Guehlstorf DW : Surgical correction of Haglund's triad using complete detachment and reattachment of the Achilles tendon. *J Foot Ankle Surg* 48 : 477-451, 2009
10. Nunley JA, Ruskin G, Horst F : Long-term clinical outcomes following the central incision technique for insertional Achilles tendinopathy. *Foot Ankle Int* 32 : 850-855, 2011
11. Maffulli N, Testa V, Capasso G, Sullo A : Calcific insertional Achilles tendinopathy reattachment with bone anchors. *Am J Sports Med* 32 : 174-182, 2004
12. Johnson KW, Zalavras C, Thordarson DB : Surgical management of insertional calcific Achilles tendinosis with a central tendon splitting approach. *Foot Ankle Int* 27 : 677-684, 2006
13. Rigby RB, Cottom JM, Vora A : Early weightbearing using Achilles suture bridge technique for insertional Achilles tendinosis : a review of 43 patients. *J Foot Ankle Surg* 52 : 575-579, 2013
14. Pilson H, Brown P, Stitzel J, Scott A : Single-row versus double-row repair of the distal Achilles tendon : a biomechanical comparison. *J Foot Ankle Surg* 51 : 762-766, 2012