

# **N-cadherin expression is involved in malignant behavior of head and neck cancer in relation to epithelial-mesenchymal transition**

**Phuong Thao Nguyen<sup>1</sup>, Yasusei Kudo<sup>1</sup>, Maki Yoshida<sup>1</sup>, Nobuyuki Kamata<sup>2</sup>, Ikuko Ogawa<sup>3</sup> and Takashi Takata<sup>1</sup>**

<sup>1</sup>Department of Oral and Maxillofacial Pathobiology, Division of Frontier Medical Science, Graduate School of Biomedical Sciences, Hiroshima University, Japan, <sup>2</sup>Department of Oral and Maxillofacial Surgery, Division of Cervico-Gnathostomatology, Graduate School of Biomedical Sciences, Hiroshima University, Japan and <sup>3</sup>Center of Oral Clinical Examination, Hiroshima University Hospital, Japan

**Summary.** The loss of E-cadherin and the gain of N-cadherin expression are known as “cadherin switching”. Cadherin switching is a major hallmark of epithelial-mesenchymal transition (EMT). EMT is a crucial process in cancer progression, providing cancer cells with the ability to escape from the primary focus, to invade stromal tissues and to migrate to distant regions. Although down-regulation of E-cadherin is well known in various cancers, there are a few studies on N-cadherin expression in cancer. Here, therefore, we investigated whether N-cadherin expression was associated with the progression of head and neck squamous cell carcinoma (HNSCC). First, we examined the expression of N-cadherin by immunohistochemistry and its correlation with clinico-pathological findings. High expression of N-cadherin was observed in 52 of 80 HNSCC cases and was significantly correlated with malignant behaviors. Next, we examined the correlation between N-cadherin and E-cadherin. Cadherin switching (high expression of N-cadherin and low expression of E-cadherin) was found in 30 of 80 HNSCC cases and was well correlated with histological differentiation, pattern of invasion and lymph node metastasis in HNSCC cases. Moreover, we examined the expression of N-cadherin and E-cadherin

by RT-PCR in 16 HNSCC cell lines to confirm the immunohistochemical findings. N-cadherin expression was observed in 7 of 16 HNSCC cells, and cadherin switching was observed in 2 HNSCC cells. Interestingly, HNSCC cells with cadherin switching have EMT features. In conclusion, we suggest that i) N-cadherin may play an important role in malignant behaviors of HNSCC, and ii) cadherin switching might be considered as a discrete critical event in EMT and metastatic potential of HNSCC.

**Key words:** N-cadherin, E-cadherin, EMT, Invasion, Head and neck squamous cell carcinoma

## **Introduction**

Head and neck squamous cell carcinoma (HNSCC) is one of the most common types of human cancer, with an annual incidence of more than 500,000 cases worldwide (Mao et al., 2004). The extent of lymph node metastasis is a major determinant in the prognosis of HNSCC. Like most epithelial cancers, HNSCC develops through the accumulation of multiple genetic and epigenetic alterations in a multistep process (Fidler, 1990). One of the most characteristic clinical features of HNSCC is its capacity to invade the adjacent tissues and metastasize. Therefore, attempts to identify the genes involved in the invasion and/or metastasis are pivotal for the early prediction of HNSCC behavior. During tumor progression, cancer cells undergo dramatic changes in the expression profile of adhesion molecules, resulting in detachment from original tissue and acquisition of a highly motile and invasive phenotype. A hallmark of this

*Offprint requests to:* Yasusei Kudo, D.D.S., PhD, Department of Oral and Maxillofacial Pathobiology, Division of Frontier Medical Science, Graduate School of Biomedical Sciences, Hiroshima University, Japan, 1-2-3 Kasumi, Minami-ku, Hiroshima 734-8553, Japan. e-mail: [ykudo@hiroshima-u.ac.jp](mailto:ykudo@hiroshima-u.ac.jp) and Takashi Takata, D.D.S., PhD, Department of Oral and Maxillofacial Pathobiology, Division of Frontier Medical Science, Graduate School of Biomedical Sciences, Hiroshima University, Japan, 1-2-3 Kasumi, Minami-ku, Hiroshima 734-8553, Japan. e-mail: [ttakata@hiroshima-u.ac.jp](mailto:ttakata@hiroshima-u.ac.jp)

change is referred to as EMT (Gupta and Massagué, 2006; Thiery, 2003). A key to EMT is the reduction of cell-cell adhesion by transcriptional repression of cadherin (Mariotti et al., 2007; Maeda et al., 2004).

Cadherins are a family of transmembrane proteins that mediate Ca<sup>2+</sup>-dependent cell-cell adhesion. Of the members of the cadherin family, E-cadherin is distributed widely and is the most important intercellular adhesion molecule in epithelial cells. Although E-cadherin is well documented as an invasive suppressor for cancer cells, the role of anomalously expressed N-cadherin in epithelial cells has only recently been identified more clearly (Derycke and Bracke, 2004). Unlike E-cadherin, N-cadherin is normally expressed in neuroectodermal and mesodermal-derived tissue and is involved in a lot of processes, such as cell-cell adhesion, differentiation, embryogenesis, migration, invasion and signal transduction (Derycke and Bracke, 2004). N-cadherin is also expressed in human endothelial cells, but its function in angiogenesis is not fully elucidated (Diamond et al., 2008). Aberrant expression of N-cadherin is considered to be associated with increased tumor progression in certain cancers (Derycke and Bracke, 2004). In particular, increased expression of N-cadherin and concomitant down-regulation of E-cadherin are suggested to be a feature of EMT in cancer (Yilmaz and Christofori, 2009). However, the mechanism by which increased expression of N-cadherin promotes malignancy is not completely understood. To find out the involvement of N-cadherin in the progression of HNSCC, we examined the expression of N-cadherin and compared it with E-cadherin expression and clinico-pathological parameters.

## **Materials and methods**

### *Clinical data and tissue samples*

Eighty paraffin-embedded HNSCC cases were retrieved from the pathological files of Cancer Hospital in Ho Chi Minh city, Vietnam in 2008, after approval by the Ethical Committee of our institutions. Clinical details and lymph node metastasis were gathered from surgical records of the patients. For the present analysis, only specimens without radio-chemotherapy were selected to avoid possible influences of the treatment modalities on data. For evaluation of invasion pattern of HNSCC, we used the grading of mode of invasion (Grade I has a well defined borderline, Grade II has a less-marked borderline, Grade III has groups of cells and no distinct borderline, and Grade IV has diffuse growth) as first described by Jacobsson et al. (1973). The histological grade was classified according to the WHO diagnostic criteria for histological typing of cancer and pre-cancer of the oral mucosa (Pindborg et al., 1997).

Fresh frozen tissues of HNSCC were obtained from 55 patients who underwent surgery at Cancer Hospital in Ho Chi Minh city, Vietnam. These tissue specimens were immediately frozen and stored at -80°C before

using. Informed consent was obtained from all patients for this study.

### *Immunohistochemistry*

Unstained 4.5 µm sections were cut from each paraffin block then de-paraffinized and rehydrated by routine techniques. Endogenous peroxidase activity was blocked with 0.3% H<sub>2</sub>O<sub>2</sub> in methanol for 30 minutes before doing antigen retrieval by microwave treatment in Tris-EDTA buffer pH 9.0 and in citrate phosphate buffer for N-cadherin and E-cadherin, respectively, for 20 minutes. The sections were then incubated with protein block serum-free solution in 10 minutes. N-cadherin and E-cadherin monoclonal antibodies (BD Transduction Laboratories) were diluted with PBS (1:30 and 1:150, respectively) and incubated overnight at 4°C. After washing three times by PBS, the sections were incubated with appropriate peroxidase-labeled secondary antibodies for 1 hour at room temperature. The sections were then labeled by diaminobenzidine and were counterstained with Mayer's haematoxyline, dehydrated and mounted. Evaluation of immunostaining was based on proportion of stained cancer cells and location of staining. N-cadherin and E-cadherin expression was scored on a semi-quantitative scale by evaluating the percentage of stained cells within representative areas of each tumor. For superficial carcinomas, stained sections were observed throughout the lesion. For advanced large tumors, at least ten fields including superficial, central and deep invasive areas were observed and the number of stained cells and staining intensity were evaluated. In each field, we counted more than 300 cells using an eyepiece graticule to prevent recounting. For N-cadherin, the samples were then divided into two groups; low (less than 20% of the cancer cells were stained) and high (over 20% of the cancer cells were stained). E-cadherin was defined as preserved (over 80% of cancer cells exhibited a staining pattern similar to that in normal epithelial cells) and reduced (less than 80% of the cancer cells exhibited a staining pattern similar to that in normal epithelial cells).

### *Statistical analysis*

Correlations between the expression pattern of N-cadherin and E-cadherin and the clinico-pathological features of HNSCC were examined using Chi-square test. Statistical analysis was performed using SPSS 13.0 and statistical significance was defined as P<0.05.

### *Reverse transcription-polymerase chain reaction (RT-PCR)*

Total RNA was isolated and purified from the fresh frozen HNSCC tissues and cells by using RNeasy Mini Kit (Qiagen, Hilden, Germany). Preparations were quantified and their purity was determined by standard spectrophotometric methods. cDNA was synthesized from

## N-cadherin expression in head and neck cancer

1µg total RNA according to the ReverTra Dash (Toyobo Biochemicals, Tokyo, Japan). Primer sequences included the following;

human N-cadherin	5'-GACAATGCCCTCAAGTGT-3' (forward) 5'-CCATTAAGCCGAGTGATGGT-3' (reverse)
human E-cadherin	5'-TGCCCAGAAAATGAAAAAGG-3' (forward) 5'-GGATGACAGCGTGAGAGA-3' (reverse)
human vimentin	5'-CCCTCACCTGTGAAGTGGAT-3' (forward) 5'-TCCAGCAGCTTCTGTAGGT-3' (reverse)
human β-catenin	5'-CCCCTAATGTCCAGCGTTT-3' (forward) 5'-AACGCATGATAGCGTGTCTG-3' (reverse)
human fibronectin	5'-TCCACAAGCGTCATGAAGAG-3' (forward) 5'-ATACCACACCAGGCTTCAGG-3' (reverse)
human vitronectin	5'-TCAACGTGGACAAGAAGTGC-3' (forward) 5'-TGAGGTCTCCCTGGATGAAG-3' (reverse)
human alpha-smooth muscle actin	5'-CCGGGAGAAAATGACTCAAA-3' (forward) 5'-GAAGGAATAGCCACGCTCAG-3' (reverse);
human GAPDH	5'-ACAGTCAGCCGCATCTTCTT-3 (forward) 5'-TTGATTTTGGAGGGATCTCG-3' (reverse)

Aliquots of total cDNA were amplified with 1.25 U of rTaq-DNA polymerase (Qiagen), and amplifications were performed in a PC701 thermal cycler (Astec, Fukuoka, Japan) for 25-35 cycles after an initial 30 sec denaturation at 94°C, annealed for 30 sec at 60°C, and extended for 1 min at 72°C in all primers. The amplification reaction products were resolved on 1.2 % agarose/TAE gels, electrophoresed at 135 mV, and visualized by ethidium-bromide staining.

### Cell lines and cell culture

A total of 16 HNSCC cell lines were used for the study. HSC2, HSC3, HSC4, Ca9-22, Ho-1-N-1 and Ho-1-U-1 cells were provided by Japanese Collection of

Research Bioresources Cell Bank. HOC119, HOC313, HOC621, HOC719-PE, HOC719-NE, TSU, OM-1 and ZA cells have been described previously (Yokoyama et al., 2001). KOSCC11 and KOSCC25B were obtained from Dr. S.P. Hong (Seoul National University). All these cells were maintained in RPMI-1640 or DMEM (Nissui Pharmaceutical Co., Tokyo, Japan) supplemented with 10% heat-inactivated FBS (Invitrogen) and 100 U/ml penicillin-streptomycin (Gibco) under conditions of 5% CO<sub>2</sub> in air at 37°C.

## Results

### N-cadherin expression and its correlation with clinico-pathological findings

To discover the role of N-cadherin in the progression of HNSCC, we examined the immunohistochemical expression of N-cadherin and its correlation with clinico-pathological findings in 80 HNSCC cases. The relationship between N-cadherin and clinico-pathological findings including pattern of invasion, histological differentiation, stage grouping and lymph node metastasis in HNSCC is summarized in Table 1. For pattern of invasion, we classified as low grade (grade I & II) and high grade (grade III & IV), according to the classification described by Jacobsson et al. (1973). High expression of N-cadherin was observed in 52 (65%) of 80 HNSCC cases (Fig. 1A and Table 1). N-cadherin expression was found in the membrane and cytoplasm of cancer cells (Fig. 1A). On the other hand, N-cadherin expression was not observed in normal epithelia. Interestingly, N-cadherin expression was significantly correlated with pattern of invasion (Fig. 1B), histological differentiation (Fig. 1C) and stage grouping (Fig. 1D).

**Table 1.** Relationship of N-cadherin with E-cadherin expression and clinico-pathological findings.

HNSCC	N-cadherin expression*		P	E-cadherin expression**		P
	Low	High		Preserved	Reduced	
Total	28	52		38	42	
Pattern of invasion			0.002			0.014
Low grade	20	19		24	15	
High grade	8	33		14	27	
Histological differentiation			0.002			0.219
Well & Moderate	26	32		30	28	
Poorly	2	20		8	14	
Stage			0.039			0.541
I & II	14	14		12	16	
III & IV	14	38		26	26	
Lymph node metastasis			0.45			0.16
Negative	16	22		24	20	
Positive	12	30		14	22	

\*For N-cadherin, the samples were then divided into two groups; low (less than 20% of the cancer cells were stained) and positive (over 20% of the cancer cells were stained). \*\*E-cadherin was defined as preserved (over 80% of cancer cells exhibited a staining pattern similar to that in normal pitheial cells) and reduced (less than 80% of the cancer cells exhibited a staining pattern similar to that in normal epithelial cells).

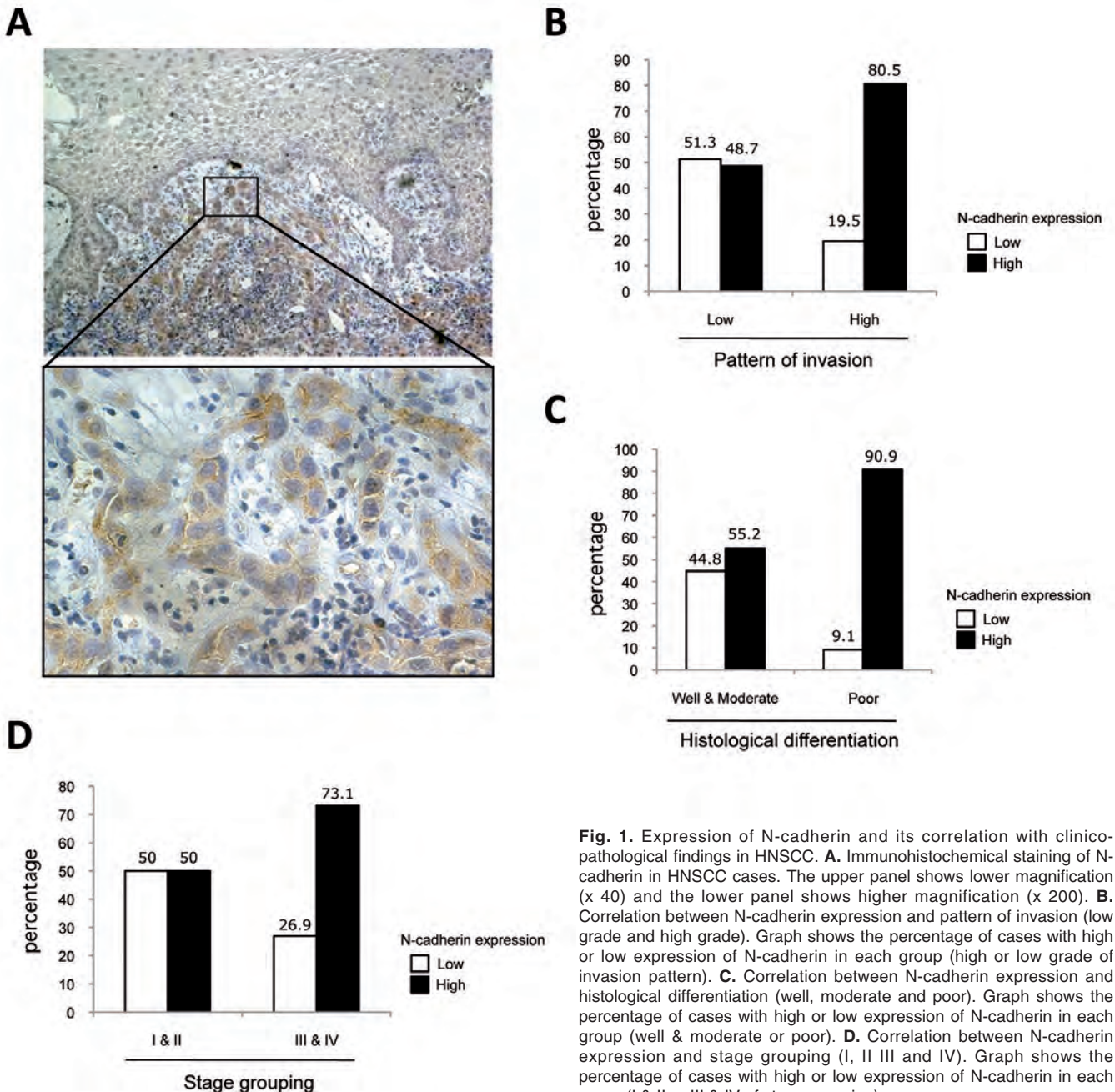


*N-cadherin expression and its correlation with E-cadherin expression*

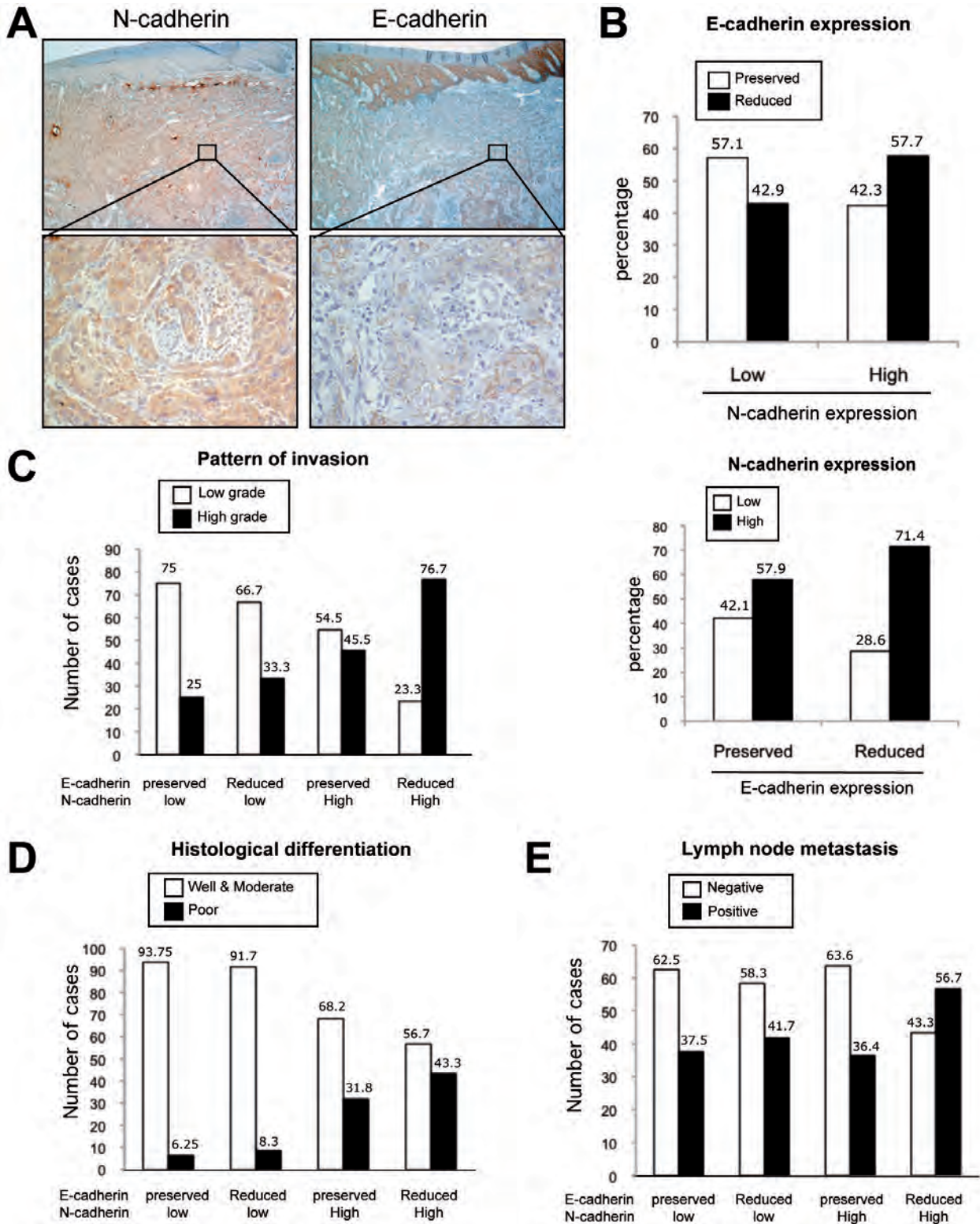
Next, we examined E-cadherin expression in HNSCC cases to compare it with N-cadherin expression. E-cadherin expression was preserved in the non-cancerous epithelial cells but reduced in the cancer cells (Fig. 2A). Reduced expression of E-cadherin was significantly correlated with pattern of invasion (Table

1). Reduced expression of E-cadherin was shown in 57.7% of HNSCC cases with high expression of N-cadherin and high expression of N-cadherin was shown in 71.4% of HNSCC cases with reduced expression of E-cadherin (Fig. 2B).

The loss of E-cadherin and the gain of N-cadherin expression are known as “cadherin switching”. Therefore, to find out the correlation between cadherin switching and clinico-pathological findings, HNSCC



**Fig. 1.** Expression of N-cadherin and its correlation with clinico-pathological findings in HNSCC. **A.** Immunohistochemical staining of N-cadherin in HNSCC cases. The upper panel shows lower magnification (x 40) and the lower panel shows higher magnification (x 200). **B.** Correlation between N-cadherin expression and pattern of invasion (low grade and high grade). Graph shows the percentage of cases with high or low expression of N-cadherin in each group (high or low grade of invasion pattern). **C.** Correlation between N-cadherin expression and histological differentiation (well, moderate and poor). Graph shows the percentage of cases with high or low expression of N-cadherin in each group (well & moderate or poor). **D.** Correlation between N-cadherin expression and stage grouping (I, II III and IV). Graph shows the percentage of cases with high or low expression of N-cadherin in each group (I & II or III & IV of stage grouping).



**Fig. 2.** Cadherin switching and its correlation with clinico-pathological findings in HNSCC. **A.** Immunohistochemical staining of N-cadherin (left panel) and E-cadherin (right panel) in HNSCC cases. The upper panel shows lower magnification (x40) and the lower panel shows higher magnification (x100). **B.** Correlation between N-cadherin expression and E-cadherin expression (preserved and reduced). In the upper panel, the graph shows the percentage of cases with preserved or reduced expression of E-cadherin in each group (low or high expression of N-cadherin). In the lower panel, the graph shows the percentage of cases with high or low expression of N-cadherin in each group (preserved or reduced expression of E-cadherin). **C.** Correlation between cadherin switching and pattern of invasion (low grade and high grade). HNSCC cases were classified into 4 groups, depending on the status of N-cadherin and E-cadherin expression; i) high expression of N-cadherin and reduced expression of E-cadherin, ii) high expression of N-cadherin and preserved expression of E-cadherin, iii) low expression of N-cadherin and preserved expression of E-cadherin, and iv) low expression of N-cadherin and reduced expression of E-cadherin. The graph shows the percentage of cases with low or high grade of invasion pattern in each of the 4 groups. **D.** Correlation between cadherin switching and histological differentiation (well, moderate and poor). Graph shows the percentage of cases with well and moderate or poor differentiation in each of the 4 groups. **E.** Correlation between cadherin switching and lymph node metastasis (negative and positive). The graph shows the percentage of cases with negative or positive of lymph node metastasis in each of the 4 groups.




*N-cadherin expression in head and neck cancer*

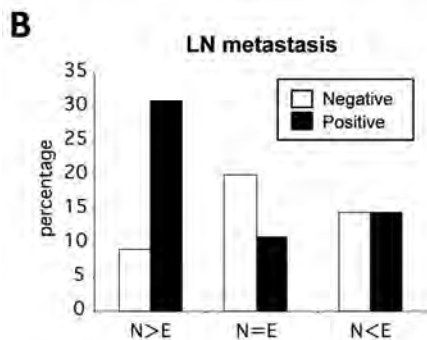
cases were classified into 4 groups, depending on the status of N-cadherin and E-cadherin expression; i) high expression of N-cadherin and reduced expression of E-cadherin, ii) high expression of N-cadherin and preserved expression of E-cadherin, iii) low expression of N-cadherin and preserved expression of E-cadherin, and iv) low expression of N-cadherin and reduced expression of E-cadherin, as shown in Table 2. HNSCC cases with high expression of N-cadherin and reduced expression of E-cadherin were defined as a Cadherin switching group. HNSCC cases with cadherin switching significantly showed malignant behaviors, including

high grade of invasion pattern (Fig. 2C) and poor differentiation (Fig. 2D). HNSCC cases with cadherin switching also showed high frequency of lymph node metastasis, but there was no significant difference (Fig. 2E). In addition, HNSCC cases with high expression of N-cadherin and preserved expression of E-cadherin also showed a high grade of invasion pattern and poor differentiation.

We also examined the mRNA expression of N-cadherin and E-cadherin in 55 fresh frozen HNSCC tissues by RT-PCR and densitometric analysis of N-cadherin and E-cadherin expression (Fig. 3A). The ratio



**Fig. 3.** Cadherin switching in HNSCC tissues. **A.** N-cadherin and E-cadherin mRNA expression in HNSCC tissues. N-cadherin and E-cadherin mRNA expression was examined by RT-PCR in 55 HNSCC tissues. GAPDH expression was used as a positive control. Densitometric analysis of N-cadherin and E-cadherin expression was performed. N-cadherin/GAPDH ratio and E-cadherin/GAPDH ratio are shown. The status of lymph node (LN) metastasis is shown as positive (+) and negative (-) and the results of immunohistochemical (IHC) analysis are shown as L (low), H (high), R (reduced), P (preserved) and ND (not determined). **B.** Correlation between the status of E-cadherin and N-cadherin and LN metastasis. HNSCC cases were classified into 3 groups, depending on the status of N-cadherin and E-cadherin expression; i) N>E; N-cadherin/GAPDH ratio is 2-fold higher than E-cadherin/GAPDH ratio. ii) N=E; N-cadherin/GAPDH ratio is over 0.5-fold and less than 2-fold higher than E-cadherin/GAPDH ratio. iii) N<E; N-cadherin/GAPDH ratio is less than 0.5-fold higher than E-cadherin/GAPDH ratio. The graph shows percentage of cases with negative or positive lymph node metastasis in each of the 3 groups.



	N>E	N=E	N<E
LN metastasis			
Negative	5 (9.1%)	11 (20.0%)	8 (14.5%)
Positive	17 (30.9%)	6 (10.9%)	8 (14.5%)

## N-cadherin expression in head and neck cancer

of N-cadherin/GAPDH and E-cadherin/GAPDH are shown in Fig. 3A. Then, HNSCC cases were classified into 3 groups (N>E, N=E and N<E), depending on the status of N-cadherin and E-cadherin expression. Among 55 HNSCC tissues, 22 (40%) cases showed higher expression of N-cadherin than E-cadherin (N>E). Interestingly, HNSCC tissues with cadherin switching (N>E group) significantly showed lymph node metastasis (Fig. 3B). Among 55 cases, 32 cases were

available for immunohistochemical analysis to examine the expression of N-cadherin and E-cadherin. We compared the relationship between the results of RT-PCR and immunohistochemistry, but we could not find a possible relationship. This discrepancy may be accounted for by translational regulation of N-cadherin and E-cadherin expression.


### Correlation between cadherin switching and EMT

Cadherin switching is a major hallmark of EMT. To discover the correlation between cadherin switching and EMT, we examined the expression of N-cadherin, E-cadherin,  $\beta$ -catenin and mesenchymal markers including vimentin,  $\alpha$ -SMA, fibronectin and vitronectin in 16 HNSCC cell lines. Among these cell lines, HOC313, HOC719-NE, TSU and KOSCC25B cells showed loss of E-cadherin expression and prominent expression of vimentin (Fig. 4). HOC719-PE (positive E-cadherin) and HOC719-NE (negative E-cadherin) cells were isolated from HOC719 cells, which express E-cadherin heterogeneously (Yokoyama et al., 2001). Moreover, it has been shown previously that HOC719-NE, TSU and HOC313 cells showed spindle morphology without E-cadherin expression, high invasive activity and elevated expression of Snail (Yokoyama et al., 2001, 2003; Taki et al., 2003). KOSCC25B cells also showed spindle morphology without E-cadherin expression (Hong et al., 2009). Therefore, HOC313, HOC719-NE, TSU and KOSCC25B are considered as EMT induced cells. In these EMT induced cells, loss of E-cadherin expression and expression of vimentin,  $\alpha$ -SMA, fibronectin and vitronectin were observed. Expression of vitronectin, vimentin and E-cadherin was well correlated with EMT induction. All HNSCC cells showed  $\beta$ -catenin mRNA expression. In 7 of 16 HNSCC cell lines (Ca9-22, Ho-1-

**Table 2.** Correlation between cadherin switching and clinico-pathological findings in HNSCC cases.

	Total	Other group	Cadherin switching group	P
Total	80	50	30	
Pattern of invasion				0.0004
Low grade	39	32	7	
High grade	41	18	23	
Histological differentiation				0.014
Well & Moderate	58	41	17	
Poorly	22	9	13	
Stage				0.467
I & II	28	19	9	
III & IV	52	31	21	
Lymph node metastasis				0.036
Negative	44	31	13	
Positive	36	19	17	

Cadherin switching group shows high expression of N-cadherin and reduced expression of E-cadherin. The other 3 groups are i) high expression of N-cadherin and preserved expression of E-cadherin, ii) low expression of N-cadherin and preserved expression of E-cadherin, and iii) low expression of N-cadherin and reduced expression of E-cadherin.



**Fig. 4.** Correlation between cadherin switching and EMT in HNSCC cell lines. N-cadherin, E-cadherin,  $\beta$ -catenin, vimentin,  $\alpha$ -SMA, fibronectin and vitronectin mRNA expression were examined by RT-PCR in HNSCC cell lines. GAPDH expression was used as a positive control. The arrow indicates specific expression of vitronectin and the asterisk shows non-specific bands. The EMT feature is also shown.

N-1, HOC119, HOC313, HOC719-NE, ZA and KOSCC11), N-cadherin expression was observed (Fig. 4). Among 4 HNSCC cell lines with EMT features, HOC313 and HOC719-NE cells showed N-cadherin expression (Fig. 4).

## Discussion

It is known that cellular changes resulting in a more mesenchymal-like state driven by EMT in cancer are thought to play a major role in tumor progression. The loss of E-cadherin and the gain of N-cadherin expression are known as “cadherin switching” (Yilmaz and Christofori, 2009). Cadherin switching is thought to reflect an EMT, whereby tumor cells are released from E-cadherin-dependent cell-cell interactions and acquire a motile phenotype through the induction of N-cadherin. In fact, here we found that cadherin switching was observed in HOC313 and HOC719-NE cell lines with EMT features such as spindle morphology, loss of E-cadherin expression, high invasive ability and elevated expression of Snail (Yokoyama et al., 2001, 2003; Taki et al., 2003) (Fig. 4). Interestingly, the gain of N-cadherin was concomitant to the loss of E-cadherin expression in HNSCC cases (Fig. 2B). Thus, cadherin switching was well correlated with EMT. Importantly, we found that HNSCC cases with cadherin switching showed malignant behaviors, including high grade of invasion, poor differentiation and lymph node metastasis (Fig. 2C-E and Table 2). We also found that cadherin switching was found in spindle cell carcinoma (unpublished data). As spindle cell carcinoma expresses both epithelial and mesenchymal markers by immunohistochemical analysis (Kudo et al., 2006; Zidar et al., 2008), EMT may be involved in the pathogenesis of spindle cell carcinoma (Zidar et al., 2008; Kojc et al., 2009). It is worth examining the role of cadherin switching for EMT induction in spindle cell carcinoma. Interestingly, it has been shown that cadherin switching is necessary for increased motility but is not required for the morphological changes that accompany EMT (Maeda et al., 2005). In addition to N-cadherin and E-cadherin, other types of cadherins, including P-cadherin and VE-cadherin are involved in EMT induction of cancer. P-cadherin was shown as one major component in reconfiguring mesenchymal cells with epithelial features by triggering GSK-3 $\beta$ -mediated inactivation and cytoplasmic translocation of Snail in oral squamous cell carcinoma (Bauer et al., 2009). VE-cadherin was induced during EMT in mammary tumor cells and was aberrantly expressed in invasive human breast carcinomas (Labelle et al., 2008). However, the mechanism of EMT induction in cancer is still unknown (Kalluri and Weinberg, 2009; Zeisberg and Neilson 2009). To understand EMT induction in cancer, other EMT markers, including several types of cadherin, should be examined.

It is well known that loss of E-cadherin expression is frequently found during tumor progression in most

epithelial cancers (Cavallaro and Christofori, 2004). We also previously demonstrated that methylation of E-cadherin is involved in invasion and metastasis in HNSCC (Kudo et al., 2004). On the other hand, aberrant de novo expression of N-cadherin has been noted in breast, prostate, and bladder cancers, where it parallels a down-regulation of E-cadherin and a decrease in tumor differentiation (Giroldi et al., 1999; Han et al., 1999; Tomita et al., 2000). Up to now, there are few studies on N-cadherin expression in HNSCC (Pyo et al., 2007; Diamond et al., 2008; Li et al., 2009), and the clinical benefit of N-cadherin expression is not clarified. Therefore, here we investigated whether N-cadherin expression was associated with the progression of HNSCC. As previously shown in various cancers (Mariotti et al., 2007), N-cadherin expression was found in membrane and cytoplasm of HNSCC cells. In 65% of HNSCC cases, high expression of N-cadherin was observed by immunohistochemistry (Fig. 1B and Table 1). Moreover, aberrant expression of N-cadherin was significantly correlated with pattern of invasion, histological differentiation and stage grouping in HNSCC. It has been shown previously that aberrant expression of N-cadherin in cancer cells can contribute to invasiveness and metastasis by making the cells more motile (Hazan et al., 1997; Nieman et al., 1999; Van Aken et al., 2003). These findings suggest that the aberrant expression of N-cadherin can be a marker for prediction of malignant behaviors of HNSCC. Moreover, it has been shown that ectopic expression of N-cadherin in epithelial cells induced down-regulation of both E-cadherin and a scattered fibroblastic phenotype (Islam et al., 1996). This phenotype is independent of cell-cell adhesion, depends on the presence of two discrete N-cadherin protein domains that suppress or modulate movement, and also depends on the expression of other proteins interacting with these domains (Islam et al., 1996; Hazan et al., 1997; Fedor-Chaiken et al., 2003; Kashima et al., 2003; Kim et al., 2000). Notably, N-cadherin is able to stimulate tumor cell invasion and metastasis even in the presence of E-cadherin (Hazan et al., 1997; Nieman et al., 1999). In this study, high expression of N-cadherin was observed in 71.4 % of HNSCC cases with reduced expression of E-cadherin, and 57.9% of HNSCC cases with preserved expression of E-cadherin. Moreover, we found that HNSCC cases with high expression of N-cadherin and preserved expression of E-cadherin showed a high grade of invasion pattern and poor differentiation (Fig. 2C, D). N-cadherin expression tended to be correlated with lymph node metastasis, but there is no significant difference (Table 1). Metastasis was not observed in patients at the resection of tumor, but there is a possibility that a tumor with high expression of N-cadherin or reduced expression of E-cadherin may metastasize in the future. With these results, we suggest that N-cadherin itself may promote invasion and metastasis of HNSCC cells. As we found that some HNSCC cell lines with E-cadherin expression showed N-cadherin expression, we will



examine whether N-cadherin knockdown affects their ability to invade and differentiate. N-cadherin interacts with a number of signal transduction molecules and contributes to various signaling pathways, such as PDGF receptor and FGF receptors (Yilmaz and Christofori, 2009). It is interesting to examine the detailed mechanism of N-cadherin mediated invasion and metastasis in HNSCC. Overall we suggest that i) N-cadherin may play an important role in malignant behaviors of HNSCC, and ii) cadherin switching might be considered as a discrete critical event in EMT and metastatic potential of HNSCC.

*Acknowledgements.* This study was supported by in part by grants-in-aid from the Ministry of Education, Science and Culture of Japan to YK, IO and TT.

## References

- Bauer K., Doweiko A., Bosserhoff A.K., Reichert T.E. and Bauer R.J. (2009). P-cadherin induces an epithelial-like phenotype in oral squamous cell carcinoma by GSK-3beta-mediated Snail phosphorylation. *Carcinogenesis* 30, 1781-1788.
- Cavallaro U. and Christofori G. (2004). Cell adhesion and signaling by cadherins and Ig-CAMs in cancer. *Nat. Rev. Cancer* 4, 118-132.
- Derycke L.D.M. and Bracke M.E. (2004). N-cadherin in the spotlight of cell-cell adhesion, differentiation, embryogenesis, invasion and signaling. *Int. J. Dev. Biol.* 48, 463-476.
- Diamond M.E., Sun L., Ottaviano A.J., Joseph M.J. and Munshi H.G. (2008). Differential growth factor regulation of N-cadherin expression and motility in normal and malignant oral epithelium. *J. Cell. Sci.* 121, 2197-2207.
- Fedor-Chaiken M., Meigs T.E., Kaplan D.D. and Brackenbury R. (2003). Two regions of cadherin cytoplasmic domains are involved in suppressing motility of a mammary carcinoma cell line. *J. Biol. Chem.* 278, 52371-52378.
- Fidler I.J. (1990). Critical factors in the biology of human cancer metastasis: Twenty-eighth GHA Clowes Memorial Award Lecture. *Cancer Res.* 50, 6130-6138.
- Giroldi L.A., Bringuier P-P., Shimazu T., Janssen K. and Schalken J.A. (1999). Changes in cadherin-catenin complexes in the progression of human bladder carcinoma. *Int. J. Cancer* 82, 70-76.
- Gupta A. and Massagué J. (2006). Cancer metastasis: building a framework. *Cell* 127, 679-695.
- Han A.C., Soler A.P., Knudsen K.A., Wheelock M.J., Johnson K.R. and Salazar H. (1999). Distinct cadherin profiles in special variant carcinomas and other tumors of the breast. *Hum. Pathol.* 30, 1035-1039.
- Hazan R.B., Kang L., Whooley B.P. and Borgen P.I. (1997). N-cadherin promotes adhesion between invasive breast cancer cells and the stroma. *Cell Adhes. Commun.* 4, 399-411.
- Hong K.O., Kim J.H., Hong J.S., Yoon H.J., Lee J.I., Hong S.P. and Hong S.D. (2009). Inhibition of Akt activity induces the mesenchymal-to-epithelial reverting transition with restoring E-cadherin expression in KB and KOSCC-25B oral squamous cell carcinoma cells. *J. Exp. Clin. Cancer Res.* 28, 28.
- Islam S., Cary T.E., Wolf G.T., Wheelock M.J. and Johnson K.R. (1996). Expression of N-cadherin by human squamous carcinoma cells induces a scattered fibroblastic phenotype with disrupted cell-cell adhesion. *J. Cell. Biol.* 135, 1643-1654.
- Jacobsson P.A., Eneroth G.M., Killander D., Moberger G. and Martensson B. (1973). Histologic classification and grading of malignancy in carcinoma of the larynx. *Acta. Radiol.* 12, 1-7.
- Kalluri R. and Weinberg R.A. (2009). The basics of epithelial-mesenchymal transition. *J. Clin. Invest.* 119, 1420-1428.
- Kashima T., Nakamura K., Kawaguchi J., Takanashi M., Ishida T., Aburatani H., Kudo A., Fukayama M. and Grigoriadis A.E. (2003). Overexpression of cadherins suppresses pulmonary metastasis of osteosarcoma in vivo. *Int. J. Cancer* 104, 147-154.
- Kim J.B., Islam S., Kim Y.J., Prudoff R.S., Sass K.M., Wheelock M.J., and Johnson K.R. (2000). N-Cadherin extracellular repeat 4 mediates epithelial to mesenchymal transition and increased motility. *J. Cell Biol.* 151, 1193-1206.
- Kojc N., Zidar N., Gale N., Poljak M., Fujs Komlos K., Cardesa A., Höfler H. and Becker K.F. (2009). Transcription factors Snail, Slug, Twist, and SIP1 in spindle cell carcinoma of the head and neck. *Virchows Arch.* 454, 549-555.
- Kudo Y., Kitajima S., Ogawa I., Hiraoka M., Sargolzaei S., Keikhaee M.R., Sato S., Miyauchi M. and Takata T. (2004). Invasion and metastasis of oral cancer cells require methylation of E-cadherin and/or degradation of membranous beta-catenin. *Clin. Cancer Res.* 10, 5455-5463.
- Labelle M., Schnittler H.J., Aust D.E., Friedrich K., Baretton G., Vestweber D. and Breier G. (2008). Vascular endothelial cadherin promotes breast cancer progression via transforming growth factor  $\beta$  signaling. *Cancer Res.* 68, 1388-1397.
- Li S., Jiao J., Lu Z. and Zhang M. (2009). An essential role for N-cadherin and beta-catenin for progression in tongue squamous cell carcinoma and their effect on invasion and metastasis of Tca8113 tongue cancer cells. *Oncol. Rep.* 21, 1223-1233.
- Maeda M., Johnson K.R. and Wheelock M.J. (2004). Cadherin switching: essential for behavioral but not morphological changes during epithelium-to-mesenchyme transition. *J. Cell. Sci.* 118, 873-887.
- Mao L., Hong W.K. and Papadimitrakopoulou V.A. (2004). Focus on head and neck cancer. *Cancer Cell* 5, 311-316.
- Mariotti A., Perotti A., Sessa C. and Ruegg C. (2007). N-cadherin as a therapeutic target in cancer. *Expert. Opin. Investig. Drugs.* 16, 451-465.
- Nieman M.T., Prudoff R.S., Johnson K.R. and Wheelock M.J. (1999). N-Cadherin Promotes Motility in Human Breast Cancer Cells Regardless of their E-Cadherin Expression. *J. Cell Biol.* 147, 631-644.
- Pindborg J.J., Reichart P.A., Smith C.J. and van der Waal I. (1997). World Health Organization: histological typing of cancer and precancer of the oral mucosa. Berlin. Springer.
- Pyo S.W., Hashimoto M., Kim Y.S., Kim C.H., Lee S.H., Johnson K.R., Wheelock M.J. and Park J.U. (2007). Expression of E-cadherin, P-cadherin and N-cadherin in oral squamous cell carcinoma: correlation with the clinicopathologic features and patient outcome. *J. Craniomaxillofac. Surg.* 35, 1-9.
- Taki M., Kamata N., Yokoyama K., Fujimoto R., Tsutsumi S. and Nagayama M. (2003). Down-regulation of Wnt-4 and up-regulation of Wnt-5a expression by epithelial-mesenchymal transition in human squamous carcinoma cells. *Cancer Sci.* 94, 593-597.
- Thiery J. (2003). Epithelial-mesenchymal transitions in development and pathologies. *Curr. Opin. Cell Biol.* 15, 740-746.
- Tomita K., van Bokhoven A., van Leenders G.J., Ruijter E.T., Jansen

*Paradoxes in nuclear structure and function*

- C.F., Bussemakers M.J. and Schalken J.A. (2000). Cadherin switching in human prostate cancer progression. *Cancer Res.* 60, 3650-3654.
- Van Aken E.H., De Wever O., Van Hoorde L., Bruyneel E., De Laey J.J. and Mareel M.M. (2003). Invasion of retinal pigment epithelial cells: N-cadherin, hepatocyte growth factor, and focal adhesion kinase. *Invest. Ophthalmol. Vis. Sci.* 44, 463-442.
- Yilmaz M. and Christofori G. (2009). EMT, the cytoskeleton, and cancer cell invasion. *Cancer Metastasis Rev.* 28, 15-33.
- Yokoyama K., Kamata N., Hayashi E., Hoteiya T., Ueda N., Fujimoto R. Nagayama M. (2001). Reverse correlation of E-cadherin and snail expression in oral squamous cell carcinoma cells in vitro. *Oral Oncol.* 37, 65-71.
- Yokoyama K., Kamata N., Fujimoto R., Tsutsumi S., Tomonari M., Taki M., Hosokawa H. and Nagayama M. (2003). Increased invasion and matrix metalloproteinase-2 expression by Snail-induced mesenchymal transition in squamous cell carcinomas. *Int. J. Oncol.* 22, 891-898.
- Zeisberg M. and Neilson E.G. (2009). Biomarkers for epithelial-mesenchymal transitions. *J. Clin. Invest.* 119, 1429-1437.
- Zidar N., Gale N., Kojc N., Volavsek M., Cardesa A., Alos L., Höfler H., Blechschmidt K and Becker K.F. (2008). Cadherin-catenin complex and transcription factor Snail-1 in spindle cell carcinoma of the head and neck. *Virchows Arch.* 453, 267-274.

Accepted July 17, 2010