

Correlation between Skp2 expression and down-regulation of p27 protein in Salivary Adenoid Cystic Carcinoma

Mohammad Reza Keikhaee¹, Yasusei Kudo^{1,*}, Samadarani Siriwardena B.S.M.¹, Lanyan Wu³, Ikuko Ogawa², Takashi Takata^{1,*}

¹Department of Oral and Maxillofacial Pathobiology, Division of Frontier Medical Science, Graduate School of Biomedical Sciences, Hiroshima University, Hiroshima, Japan;

²Center of Oral Clinical Examination, Hiroshima University Hospital, Hiroshima, Japan;

³Department of Oral Pathology, HuaXi Stomatology Hospital, Sichuan University, Chengdu, Sichuan 610041, P.R.China

***Correspondence:** Y. Kudo and T. Takata, Department of Oral and Maxillofacial Pathobiology, Graduate School of Biomedical Sciences, Hiroshima University, 1-2-3 Kasumi, Minami-ku, Hiroshima 734-8553, Japan. TEL: +81-82-257-5634, Fax: +81-82-257-5619. E-mail: ykudo@hiroshima-u.ac.jp and ttakata@hiroshima-u.ac.jp

Acknowledgments: This work is supported in part by grants-in-aid from the Ministry of Education, Science and Culture of Japan to YK, IO and TT.

Abstract

Adenoid cystic carcinoma (ACC) is a malignant salivary gland tumor, which shows frequent recurrence and metastasis, ultimately with a poor outcome. We previously demonstrated that p27 down-regulation is frequently found and is due to an enhancement of its degradation in ACC. Here we transfected non-degradable p27 mutant (T187A) and wild type gene into ACC cell line. Transfection of T187A mutant gene was more effective on inhibition of cell growth of ACC cells, suggesting that aberration of p27 degradation may be present in ACC. As F-box protein Skp2, which is necessary for ubiquitin-mediated degradation of p27, is involved in p27 down-regulation in various cancers, we examined the Skp2 expression and its correlation with p27 expression in 50 ACC cases. We found Skp2 expression in 36% of ACC cases and inverse correlation between the expression of Skp2 and p27. Moreover, Skp2 siRNA transfection decreased Skp2 protein and accumulation of p27 protein and inhibited the cell growth of ACC cells *in vitro*. These findings overall suggest that Skp2 may play an important role in ACC development through the down-regulation of p27, and that Skp2 siRNA can be a novel modality of cancer gene therapy for suppression of p27 down-regulation in ACC.

Key words: Adenoid cystic carcinoma; Skp2; p27; proliferation; salivary gland

Abbreviations: ACC, adenoid cystic carcinoma; Skp2, S-phase kinase-associated protein 2; TGF- β , transforming growth factor-beta; siRNA, small interfering RNA; Cul1, cullin1; PCNA, Proliferating Cell Nuclear Antigen; Jab1, Jun activation domain-binding protein-1; KPC, Kip1 ubiquitination-promoting complex.

Introduction

Adenoid cystic carcinoma (ACC) is one of the most common malignant tumors of major and minor salivary glands [4,23,31,33,36]. Although ACC tends to grow slowly, this neoplasm has a poor prognosis in comparison with the majority of other malignant salivary gland tumors [23,31]. ACC shows various histological patterns such as cribriform, tubular and solid. It is generally regarded that tubular or cribriform pattern dominant subtypes have much better prognosis than those with predominantly solid patterns [5-7]. However, it is often difficult to predict the prognosis of ACC by histological findings alone, especially when dealing with inadequate biopsy material [23,41]. Thus, there is a need to explore additional parameters for predicting the prognosis of ACC. Previous our study demonstrated that cyclin-dependent kinase inhibitor, p27 was frequently down-regulated and well correlated with its malignant behavior in ACC [34]. p27 mediates G1 arrest induced by TGF- β , contact inhibition, or serum deprivation in epithelial cell lines [25,38]. The increase in the cellular abundance of p27 upon induction of cell quiescence is primarily due to a decrease in the rate of its degradation [22]. p27 is poly-ubiquitinated both *in vivo* and *in vitro* and a lower amount of p27 ubiquitinating activity is present in proliferating cells compared to quiescent cells [22]. Furthermore, p27 ubiquitination requires its phosphorylation on threonine 187 (T187) [19]. Down-regulation of p27 was frequently found in various cancers, and the lack of p27 is suggested to be due to an enhancement of its degradation [30]. Aggressive human cancers express low levels of p27 because of its decreased stability [30]. Importantly, reduced p27 levels represent a powerful prognostic marker for poor survival in cancer patients.

Skp2 was originally identified as a protein that interacts with cyclin A [43]. It has been reported that p27 is specifically recognized and targeted for ubiquitination by Skp2 [1.32.39]. Skp2 is required for the ubiquitination and consequent degradation of p27 both *in vivo* and *in vitro* [1.32.39]. Skp2 is a rate-limiting component of the machinery that ubiquitinates and

degrades phosphorylated p27 [1]. Skp2 is frequently overexpressed in tumor cell lines, and forced expression of Skp2 in quiescent fibroblasts induces DNA synthesis [32,43]. Recently, it has been revealed that Skp2 overexpression is frequently found and is well correlated with down-regulation of p27 protein in various types of cancer [15,39].

In the present study, we transfected non-degradable mutant and wild type p27 into ACC cell line. Moreover, we examined the immunohistochemical expression of Skp2 and its correlation with p27 expression. Finally, we examined if siRNA-mediated gene silencing of Skp2 can be employed in order to inhibit p27 down-regulation in ACC.

Materials and methods

All procedures of the present studies were performed in compliance with regulations administered by the Hiroshima University.

Cell culture

We used ACCh cell line that was established in the Department of Oral Maxillofacial Surgery, Hiroshima University School of Dentistry (kindly provided by T. Okamoto), and was maintained in 5 % CO₂, 95 % air at 37 °C. ACCh cells were maintained in serum-free RD153 medium (RPMI1640:DMEM:MCDB153;1:1:2, v/v/v) containing 10 mg/ml insulin, 10 mM 2-mercaptoethanol, 10 mM 2-aminoethanol and 10 nM selenite [20,26,28]. For experiments, these cells were grown to sub-confluence in each medium.

Generation of stable clones expressing inducible p27

For stably expressing p27 wild type and mutant in an inducible way, we used an ecdysone-inducible mammalian expression system (Invitrogen, Carlsbad, CA) as we described previously [14]. To construct pIND-p27 (wild type; WT) or pIND-p27 (threonine-to-alanine p27 mutant; T187A), a *Bam* HI/*Eco* RI fragment was isolated

from pcDNA3-p27 WT or pcDNA3-p27 T187A (kindly provided by M. Pagano), and cloned into pIND ecdysone-inducible expression vector (Invitrogen) digested with *Bam* HI/*Eco* RI. Transfection was performed in 60 mm plates using 2 µg of expression vector by using Fugene 6 (Roche). ACCCh cells stably expressing ecdysone receptor (EcR) were first isolated with Zeocin (Invitrogen) as a selective marker. The EcR cells were then used to generate clones that incorporated ecdysone response elements followed by wild type and T187A mutant p27 with G418 (Life Technologies, Inc.) as a selective marker. Cells were treated with ponasterone A (5 µM) for 24, 48 and 72 hour for induction of p27 expression.

Western blot analysis

We examined the expression of p27, Skp2 and Cul1 proteins in ACC cell lines by Western blot analysis. Western blotting was carried out as we described previously [13]. We used an anti-p27 mouse monoclonal antibody (Transduction Laboratories), anti-Skp2 monoclonal antibody (Zymed laboratories Inc.) and an anti-Cul1 polyclonal antibody (Zymed laboratories Inc.). Thirty µg of protein was subjected to 10 % polyacrylamide gel electrophoresis followed by electroblotting onto a nitrocellulose filter. For detection of the immunocomplex, the ECL western blotting detection system (Amersham, Aylesbury, UK) was used.

Tissue samples

Fifty ACCs including 7 cases with metastasis were retrieved from the pathological files of Hiroshima University Hospital (Japan), Peradeniya University (Sri Lanka) and Sichuan University (China). Clinical data of the patients are summarized in Table 1. Among the 50 ACC patients, 20 were males and 30 were females. At the time of diagnosis their age ranged from 30 to 84 years (average; 59.7 ± 15.1). The tumors were subclassified according to the histological grading of Szanto et al. as follows: Grade I, tumors with

cribriform and/or tubular structures without a solid component; Grade II, tumors composed of cribriform and/or tubular structures with less than 30% of solid areas; and Grade III, tumors with more than 30% of solid areas [33].

Immunohistochemistry

Immunohistochemical detection of Skp2, p27 and PCNA was performed using a streptavidin-biotin peroxidase technique as described previously [13,34]. An anti-human Skp2 mouse monoclonal antibody (dilution 1:100, Zymed laboratories Inc., San Francisco, CA), an anti-human p27 mouse monoclonal antibody (dilution 1:100, Transduction Laboratories, Lexington, KY) and an anti-human PCNA antibody were used. Nuclear staining of Skp2, p27 and PCNA was scored on a semi-quantitative scale (see below) by evaluating the percentage of stained nuclei within representative areas of each tumor. For small or superficial carcinomas, stained sections were observed throughout the lesion. For advanced large tumors, at least ten fields (including superficial, central and deep invasive areas) were observed and the number of stained cells and staining intensity were evaluated. The expression of Skp2 was graded as + (over 5 % of tumor cells showed strong or diffuse immunopositivity) and - (less than 5 % of the tumor cells showed weak or focal immunopositivity or no staining). The expression of p27 was graded as described previously [34]. A labeling index, percentage of nuclear stained cells, of PCNA was determined by the examination of at least 500 cells in three representative and intensely stained areas. PCNA labeling index was graded as I (less than 25 % of cells are positive), II (25-50% of cells are positive) and III (over 50% of cells are positive). Three observers (I. O., Y. K. and S. S.) made independent assessments of the immunohistochemical grading of Skp2, p27 and PCNA and where the gradings were divergent an agreement was reached following discussion.

Statistical Analysis

Possible correlation between variables of the analyzed tumor samples was confirmed by the Fisher's exact test. A P value < 0.05 was required for significance.

Plasmids and synthetic siRNA

Vector pSuppressorNeo generates biologically active siRNAs from the U6 promoter (Imgenex, San Diego, CA). Synthetic two oligonucleotides primers(5'-tcgaGGGAGUG ACAAAGACUUUGgaguacugCAAAGUCUUUGUCACUCCCUUUUU-3'and 5'-ctagAAA AAGGGAGUGACAAAGACUUUGcaguacucCAAAGUCUUUGUCACUCCC-3') containing *Xho* I and *Xba* I overhangs were annealed and then were introduced into pSuppressorNeo vector. Oligonucleotide sequences correspond to a 19-nt sequence from Skp2 (nucleotide 114-133), which are separated by an 8-nt linker (lower case letters) from the reverse complement of the same 19-nt sequence. We also added transcriptional termination (UUUUU) to the end of oligonucleotide. We used circular control plasmid, which contains a scrambled sequence that does not show significant homology to rat, mouse or human gene sequences, as a control. Transfection was performed in 60 mm plates using 2 μ g of vector and 10 μ l of Fugene 6 reagent (Roche). After 48 hours of transfection, cells were treated G418 (Gibco) for 2 weeks as a selective marker. After G418 treatment, we obtained stably transfectant cells.

Results

Non-degradable p27 mutant more effectively inhibit cell growth of ACC cells in comparison with wild type

In our previous study, frequent reduced expression of p27 was observed and well correlated with its malignant behavior in ACC [34]. We also found a high p27 degradation activity in ACC cells, which did not express p27 protein [34]. Therefore, in

the present study, we transfected ACCh cells with p27 T187A mutant gene, which is not influenced by ubiquitin-mediated degradation, and p27 WT gene in an inducible way. These cells were first transfected with a *Drosophila* EcR, then with the p27 WT or T187A mutant gene that was placed under the control of the ecdysone-inducible promoter element such that expression of the p27 transgenes could be regulated with the ecdysone analog ponasterone A. Ponasterone A induced overexpression p27 WT and T187A mutant proteins at 72 and 24 h, respectively (Fig. 1A and B). We next determined the effects of p27 transfection on cell growth. The induction of T187A mutant protein by ponasterone A inhibited cell growth in ACCh cells (Fig. 1A and B). The growth-inhibitory effect in WT induction was lower than that in T187A mutant. Our previous study showed that WT p27 was more stable than T187A mutant [14]. Therefore, we think that exogenous WT was induced later than T187A. Similarly to other types of cancer, aberrant regulation of p27 protein degradation may play an important role for down-regulation of p27 protein in ACC.

Immunohistochemical expression of Skp2 and p27 in ACC

p27 is specifically recognized and targeted for ubiquitination by Skp2 [1,32,39]. It has been reported that Skp2 overexpression is found and is well correlated with p27 down-regulation in various types of malignant tumors [3,8,9,13,16,18,29,42]. Here, therefore, we examined the expression of Skp2 and its correlation with p27 expression in 50 ACC cases. Table 1 summarizes the clinical and immunohistochemical results of 50 patients. In brief, there were 30 females and 20 male patients and the age ranges from 30-84 years. Palate was the commonest site. Out of 50 cases, Skp2 expression was found in 18 (36%) cases. Then, Skp2 expression was compared with p27 expression, PCNA labeling index and clinico-pathological parameters including histology and metastasis as summarized in Table 2. Reduced expression of p27 was found in 38 (76%) cases in

similar to our previous report [34]. Interestingly, Skp2 expression was inversely correlated with p27 expression ($P=0.00519$) (Fig 2A-D and Table 2). Furthermore, Skp2 expression was statistically correlated with high proliferative activity (PCNA index) ($P=0.000311$) (Table 2). However, Skp2 expression was not correlated with histological grading and lymph node metastasis (Table 2).

Skp2 siRNA induced p27 accumulation and inhibited the cell proliferation in ACC cells

Next, to suppress the ubiquitin-mediated degradation of p27 which frequently shown in ACC, we inhibited Skp2 expression by siRNA in ACCh cells. ACCh cells showed high expression of Skp2 and down-regulation of p27 (Fig. 3A). In order to block Skp2 expression selectively by siRNA, 19-nt target sequence, separated by an 8-nt spacer from its reverse complement sequence, was introduced into the siRNA generating pSuppressorNeo vector system. Skp2 siRNA was transfected into ACCh cells. After selection using G418, we could get stable clones of Skp2 siRNA. Skp2 siRNA transfection induced the down-regulation of Skp2 protein (Fig. 3A). As we expected, accumulation of p27 protein was observed in Skp2 siRNA transfectant cells. Next, we examined the effect of Skp2 siRNA transfection on cell proliferation. Skp2 siRNA transfectant cells grew *in vitro* slower than control siRNA transfectant cells (Fig. 3B).

Discussion

ACC, which is one of the most common malignant tumors of major and minor salivary glands, typically presents an indolent and slow growth associated to frequent late distant metastases, which are together with local recurrences, the reasons for the low long-term survival rate [4,23,31,33,36,40]. Standard treatment has not yet been established, although many series of ACC have been described. Several studies showed that advanced clinical stage and solid histological subtype are relevant prognostic factors

associated with survival of the patients [12,21]. However, it is often difficult to predict the prognosis of ACC by histological findings alone, especially when dealing with inadequate biopsy material [23,41]. Thus, there is a need to explore additional parameters for predicting the prognosis of ACC.

The proliferation and progression of cancer cells may be caused by abnormalities of various positive and negative cell cycle regulators [10,27]. Recently, reduced expression of p27 was found in various cancers, and was correlated to their malignancy and poor prognosis [13]. Our previous study showed that reduced expression of p27 was observed in 83 % of ACCs and was well correlated with metastasis [34]. These findings suggest that the reduction of p27 protein may be involved in the development of ACC and might be a prognostic marker for ACC patients. Moreover, we found that p27 protein was accumulated by proteasome inhibitor treatment in ACC cell line, ACCh cells which showed reduced expression of p27 protein [34]. In addition, here we demonstrated that exogenous non-degradable p27 mutant was more rapidly induced and more effective for inhibition of cell growth in comparison with wild type p27 by using inducible way in ACC cells (Fig. 1). Therefore, we strongly suggest that p27 down-regulation found in ACC might be caused by increased degradation of p27 protein. This hypothesis is supported by previous findings that aggressive human cancers such as colon cancers, lymphomas and astrocytic brain tumors express low levels of p27 because of its decreased stability [2,17,24,35].

Recently, SCF^{Skp2} was identified as the E3 ubiquitin ligase that targets p27 for ubiquitination [1,32,39]. Importantly, Skp2 is frequently overexpressed in tumor cell lines, and forced expression of Skp2 in quiescent fibroblasts induces DNA synthesis [43]. In fact, here we found that Skp2 expression was inversely correlated with p27 expression in ACC cases. This is the first report on Skp2 expression in salivary gland tumor. It has been reported that Skp2 overexpression is found in other types of malignant tumor

including lymphomas, oral cancers, breast cancers, colon cancers, lung cancers and gastric cancers [3,8,9,13,16,18,29,42]. Therefore, we suggest that p27 down-regulation mediated by Skp2 overexpression may be a common event in various cancers. Previously, we reported that reduced expression of p27 was well correlated with metastasis in ACC [34]. In the present study, we also found similar relationship; 5 of 7 (71%) cases with metastasis showed reduced expression of p27, while 22 of 43 (51%) cases without metastasis showed reduced expression of p27 (data not shown). However, we could not find possible correlation between Skp2 expression and metastasis. This discrepancy may be accounted for by other pathway of p27 degradation such as Jab1, KPC and so on [11,37]. To clarify the detailed mechanism of p27 degradation in cancer, further studies are required. Although it is generally regarded that tubular or cribriform pattern dominant subtypes have much better prognosis than those with predominantly solid patterns [5-7], we could not find the correlation between Skp2 expression and histological grading. Interestingly, Skp2 expression was well correlated with PCNA. This data was confirmed by the finding that Skp2 knockdown by using siRNA transfection inhibited cell growth through accumulation of p27 protein in ACC cells (Fig. 2). We suggest that Skp2 overexpression may be involved in growth of ACC cells through p27 protein degradation, and that Skp2 siRNA can be a therapeutic target for ACC patients.

In conclusion, we showed that Skp2 expression is strongly correlated with p27 down-regulation and cell proliferation in ACC. Our findings are in agreement with those reported previously and provide evidence for the p27-degradative function of Skp2 in ACC.

References

1. Carrano AC, Eytan E, Hershko A, Pagano M. (1999) SKP2 is required for ubiquitin-mediated degradation of the CDK inhibitor p27. *Nat Cell Biol* 1: 193-199
2. Chiarle R, Budel LM, Skolnik J, Frizzera G, Chilosi M, Corato A, Pizzolo G, Magidson J, Montagnoli A, Pagano M, Maes B, De Wolf-Peeters C, Inghirami G. (2000) Increased proteasome degradation of cyclin-dependent kinase inhibitor p27 is associated with a decreased overall survival in mantle cell lymphoma. *Blood* 95: 619–626
3. Chiarle R, Fan Y, Piva R, Boggino H, Skolnik J, Novero D, Palestro G, De Wolf-Peeters C, Chilosi M, Pagano M, Inghirami G. (2002) S-phase kinase-associated protein 2 expression in non-Hodgkin's lymphoma inversely correlates with p27 expression and defines cells in S phase. *Am J Pathol* 160: 1457–1466
4. Chilla R, Schroth R, Eysholdt V, Droese M. (1980) Adenoid cystic carcinoma of the head and neck: Controllable and uncontrollable factors in treatment and prognosis. *ORL J Otorhinolaryngol Relat Spec* 42: 346-367
5. Chomette G, Auriol M, Tranbaloc P, Vaillant JM. (1982) Adenoid cystic carcinoma of minor salivary glands: Analysis of 86 cases. Clinico-pathological, histoenzymological and ultrastructural studies. *Virchows Arch* 395: 289-301
6. Gates GA. (1982) Malignant neoplasm of the minor salivary glands. *N Engl J Med* 306: 718-722
7. Goepfert H, Luna MA, Lindberg RD, White AK. (1983) Malignant salivary gland tumors of the paranasal sinuses and nasal cavity. *Arch Otolaryngol* 109: 662-668
8. Gstaiger M, Jordan R, Lim M, Catzavelos C, Mestan J, Slingerland J, Krek W. (2001) Skp2 is oncogenic and overexpressed in human cancers. *Proc Natl Acad Sci USA* 98: 5043-5048

9. Hershko D, Bornstein G, Ben-Izhak O, Carrano A, Pagano M, Krausz MM, Hershko A. (2001) Inverse relation between levels of p27^{Kip1} and of its ubiquitin ligase subunit Skp2 in colorectal carcinomas. *Cancer* 91: 1745–1751
10. Hunter T, Pines J. (1994) Cyclins and cancer II: cyclin D and CDK inhibitors come of age. *Cell* 79: 573-582
11. Kamura T, Hara T, Matsumoto M, Ishida N, Okumura F, Hatakeyama S, Yoshida M, Nakayama K, Nakayama KI. (2004) Cytoplasmic ubiquitin ligase KPC regulates proteolysis of p27^{Kip1} at G1 phase. *Nat Cell Biol* 6: 1229-1235
12. Khan AJ, DiGiovanna MP, Ross DA, Sasaki CT, Carter D, Son YH, Haffty BG. (2001) Adenoid cystic carcinoma: a retrospective clinical review. *Int J Cancer* 96: 149–158
13. Kudo Y, Kitajima S, Ogawa I, Sato S, Miyauchi M, Takata T. (2001) High expression of Skp2, human F-box protein, correlates with poor prognosis in oral squamous cell carcinomas. *Cancer Res* 61: 7044-7047
14. Kudo Y, Kitajima S, Sato S, Ogawa I, Miyauchi M, Takata T. (2002) Transfection of p27^{Kip1} threonine residue 187 mutant type gene, which is not influenced by ubiquitin-mediated degradation, induces cell cycle arrest in oral squamous cell carcinoma cells. *Oncology* 63: 398-404
15. Kudo Y, Kitajima S, Ogawa I, Miyauchi M, Takata T. (2005) Down-regulation of Cdk inhibitor p27 in oral squamous cell carcinoma. *Oral Oncol* 41: 105-116
16. Latres E, Chiarle R, Schulman BA, Pavletich NP, Pellicer A, Inghirami G, Pagano M. (2001) Role of the F-box protein Skp2 in lymphomagenesis. *Proc Natl Acad Sci USA* 98: 2515-2520
17. Loda M, Cukor B, Tam S, Lavin P, Fiorentino M, Draetta GF, Jessup JM, Pagano M. (1997) Increased proteasome-dependent degradation of the cyclin-dependent kinase inhibitor p27 in aggressive colorectal carcinomas. *Nature Med* 3: 231–234

18. Masuda TA, Inoue H, Sonoda H, Mine S, Yoshikawa Y, Nakayama K, Nakayama K, Mori M. (2000) Clinical and biological significance of S-phase kinase-associated protein 2 (Skp2) gene expression in gastric carcinoma: modulation of malignant phenotype by Skp2 overexpression, possibly via p27 proteolysis. *Cancer Res* 62: 3819–3825
19. Montagnoli A, Fiore F, Eytan E, Carrano AC, Draetta GF, Hershko A, Pagano M. (1999) Ubiquitination of p27 is regulated by Cdk-dependent phosphorylation and trimeric complex formation. *Genes Dev* 13: 1181-1189
20. Moore GE, Gerner RE, Franklin HA. (1967) Culture of normal human leukocytes. *JAMA* 199: 519-524
21. Nascimento AG, Amaral AL, Prado LA, Kligerman J, Silveira TR. (1986) Adenoid cystic carcinoma of the salivary glands. A study of 61 cases with clinicopathologic correlation, *Cancer* 57: 312–319
22. Pagano M, Tam SW, Theodoras AM, Beer-Romero P, Del Sal G, Chau V, Yew PR, Draetta GF, Rolfe M. (1995) Role of the ubiquitin proteasome pathway in regulating abundance of the cyclin-dependent kinase inhibitor p27. *Science* 269: 682-685
23. Peel RL, Gnepp DR. (1985) Disease of the salivary glands, in Barnes L (ed) *Surgical Pathology of the Head and Neck*. Dekker, New York, pp 533-545
24. Piva R, Cancelli I, Cavalla P, Bortolotto S, Dominguez J, Draetta GF, Schiffer D. (1999) Proteasome-dependent degradation of p27/kip1 in gliomas. *J Neuropathol Exp Neurol* 58: 691–696
25. Polyak K, Lee MH, Erdjument-Bromage H, Koff A, Roberts JM, Tempst P, Massague J. (1994) Cloning of p27^{Kip1}, a cyclin-dependent kinase inhibitor and a potential mediator of extracellular antimitogenic signals. *Cell* 78: 59-66
26. Sato JD, Kawamoto T, Okamoto T. (1987) Cholesterol requirement of P3-X63-Ag8 and X63-Ag8.653 mouse myeloma cells for growth in vitro. *J Exp Med* 165: 1761-1766.
27. Sherr CJ. (1994) G1 phase progression: cycling on cue. *Cell* 79: 515-555

28. Shipley GD, Pittelkow MR. (1987) Control of growth and differentiation in vitro of human prokeratinocytes cultured in serum-free medium. *Arch Dermatol* 123: 1541-1544
29. Signoretti S, Di Marcotullio L, Richardson A, Ramaswamy S, Isaac B, Rue M, Monti F, Loda M, Pagano M. (2002) Oncogenic role of the ubiquitin ligase subunit Skp2 in human breast cancer. *J Clin Invest* 110: 633–641
30. Slingerland JM, Pagano M. (2000) Regulation of the cdk inhibitor p27 and its deregulation in cancer. *J Cell Physiol* 183: 10-17
31. Spiro RH, Huvos AG, Strong EW. (1974) Adenoid cystic carcinoma of salivary origin: A clinicopathologic study of 242 cases. *Am J Surg* 128: 512-520
32. Sutterluty H, Chatelain E, Marti A, Wirbelauer C, Senften M, Muller U, Krek W. (1999) p45SKP2 promotes p27^{Kip1} degradation and induces S phase in quiescent cells. *Nat Cell Biol* 1: 207-214
33. Szanto PA, Luna MA, Tortoledo E, White RA. (1984) Histologic grading of adenoid cystic carcinoma of the salivary glands. *Cancer* 54: 1062-1069
34. Takata T, Kudo Y, Zhao M, Ogawa I, Miyauchi M, Sato S, Cheng J, Nikai H. (1999) Reduced expression of p27^{Kip1} protein in relation to metastasis in salivary adenoid cystic carcinoma. *Cancer* 86, 928-35.
35. Tan P, Cady B, Wanner M, Worland P, Cukor B, Magi-Galluzzi C, Lavin P, Draetta G, Pagano M, Loda M. (1997) The cell cycle inhibitor p27 is an independent prognostic marker in small (T1a, b) invasive breast carcinomas. *Cancer Res* 57: 1259–1263
36. Tomich CE. (1991) Adenoid cystic carcinoma, in Ellis GE, Auclair PL, Gnepp DR (ed) *Surgical Pathology of the Salivary Glands*. Saunders, Philadelphia, pp 333-349
37. Tomoda K, Kubota Y, Kato JY. (1999) Deregulation of the cyclin-dependent-kinase inhibitor p27^{Kip1} is instigated by Jab1. *Nature* 398:160–165
38. Toyoshima H, Hunter T. (1994) p27, a novel inhibitor of G1 cyclin-Cdk protein kinase activity, is related to p21. *Cell* 78: 67-74

39. Tsvetkov LM, Yeh KH, Lee S, Sun H, Zhang H. (1999) p27^{Kip1} ubiquitination and degradation is regulated by the SCFSkp2 complex through phosphorylated Thr187 in p27. *Curr Biol* 9: 661-664
40. van der Wal JE, Becking AG, Snow GB, van der Waal I. (2002) Distant metastases of adenoid cystic carcinoma of the salivary glands and the value of diagnostic examinations during follow-up. *Head Neck* 24: 779–783
41. Vuhahula EA, Nikai H, Ogawa I, Miyauchi M, Takata T, Ito H, Ito R. (1995) Correlation between argyrophilic nucleolar organizer region (AgNOR) counts and histologic grades with respect to biologic behavior of salivary adenoid cystic carcinoma. *J Oral Pathol Med* 24: 437-442
42. Yokoi S, Yasui K, Saito-Ohara F, Koshikawa K, Iizasa T, Fujisawa T, Terasaki T, Horii A, Takahashi T, Hirohashi S, Inazawa J. (2002) A novel target gene, SKP2, within the 5p13 amplicon that is frequently detected in small cell lung cancers. *Am J Pathol* 161: 207–216
43. Zhang H, Kobayashi R, Galaktionov K, Beach D. (1995) p19Skp-1 and p45Skp-2 are essential elements of the cyclin A-Cdk2 S phase kinase. *Cell* 82: 915-925

Figure legend

Fig. 1. Transfection of p27 WT gene and T187A mutant gene into ACCh cells. For stably expressing p27 WT and mutant in an inducible way, we used ecdysone-inducible mammalian expression system by the provided protocol (Invitrogen). ACCh cells stably expressing EcR were first isolated with Zeocin. The EcR cells were then used to generate clones that incorporated ecdysone response elements followed by WT and mutant p27 with G418. Expression of WT and mutant p27 was induced by ponasterone A (5 μ M) for 24, 48 and 72 hour followed by Western blot analysis. (A) Induction of p27 WT protein was observed at 72 h in ACCh cells (upper panel). Cell growth in wild type p27 transfectant ACCh cells with or without ponasterone A (lower panel). Each cells were cultured in the medium containing ponasterone A (5 μ M), and then trypsinized cells were counted by Cell Counter at 0, 2, 4 and 6 day. Bars, SD. (B) Induction of p27 T187A mutant protein was observed at 24 h in ACCh cells (upper panel). Cell growth in T187A mutant p27 transfectant ACCh cells with or without ponasterone A (lower panel). Each cells were cultured in the medium containing ponasterone A (5 μ M), and then trypsinized cells were counted by Cell Counter at 0, 2, 4 and 6 day. Bars, SD.

Fig. 2. Immunohistochemical expression of Skp2 and p27 in ACC. Representative case with high p27 expression (A) and low Skp2 expression (B) and case with low p27 expression (C) and high Skp2 expression (D) are shown.

Fig. 3. Skp2 knockdown inhibits cell growth in ACC cells. A. Expression of p27 and Skp2 protein in control ACCh cells and Skp2 siRNA transfectant ACCh cells. Cul1 expression is used as a loading control. B. Cell proliferation of control ACCh cells and Skp2 siRNA transfectant ACCh cells. 5×10^3 cells were plated in 24 well plates and cells were counted at 0, 2, 4 and 6 day by using cell counter.

Table 1. Clinical data of ACC patients and immunohistochemical results

Case No.	Age	Sex	Site	Grading	Metastasis	Skp2 expression	p27 expression	PCNA score
1	40	M	PALATE	II	-	-	-	I
2	76	M	LOWER LIP	II	-	-	-	II
3	60	F	SM	I	-	-	-	II
4	55	F	SM	I	-	-	+	I
5	78	F	FOM	I	-	-	+	I
6	65	F	FOM	I	-	-	+	I
7	81	F	FOM	I	-	-	+	I
8	74	F	PALATE	III	+	-	+	I
9	64	F	SLG	I	+	-	+	I
10	75	M	PALATE	I	-	-	+	I
11	57	F	PAROTID	II	-	-	+	II
12	49	F	MAXILLA	III	-	-	+	II
13	48	F	RETROMORAL	II	+	-	+	II
14	37	F	FOM	III	+	-	+	III
15	77	F	TONGUE	II	-	-	++	I
16	79	M	PALATE	II	-	-	++	I
17	76	M	PALATE	I	-	-	++	I
18	84	F	FOM	II	-	-	++	I
19	74	F	SM	I	-	-	++	I
20	49	F	SM	I	-	-	++	I
21	79	F	SM	II	-	-	++	I
22	74	M	FOM	I	-	-	++	I
23	46	F	FOM	I	-	-	++	II
24	79	M	PALATE	III	-	-	++	II
25	40	M	PALATE	II	-	-	++	II
26	78	M	TONGUE	I	-	-	++	II
27	65	M	SM	III	-	-	++	II
28	55	M	PALATE	III	-	-	++	II
29	30	M	PAROTID	I	-	-	++	II
30	63	F	FOM	II	+	-	++	II
31	61	M	MAXILLA	III	-	-	++	III
32	54	M	MAXILLA	III	-	-	++	III
33	45	F	PALATE	I	-	+	-	I
34	37	F	FOM	I	-	+	-	II
35	45	F	REGION 7	I	-	+	-	II
36	48	M	PALATE	III	-	+	-	II
37	64	F	PALATE	II	-	+	-	II
38	52	F	PALATE	I	-	+	-	II
39	65	F	MAXILLA	II	-	+	-	III
40	39	M	PAROTID	I	-	+	-	III
41	30	F	MAXILLA	III	+	+	-	III
42	48	F	SLG	III	-	+	+	II
43	58	M	PAROTID	II	-	+	+	III
44	48	F	TONGUE	II	-	+	+	III
45	50	F	PALATE	III	-	+	+	III
46	73	M	PALATE	I	-	+	++	II
47	75	F	FOM	III	-	+	++	III
48	73	M	MAXILLA	III	-	+	++	III
49	43	M	MAXILLA	III	-	+	++	III
50	70	F	SM	III	+	+	++	III

Table 2. Summary of Skp2 expression in ACC

		Total	Skp2 expression		<i>P</i> value
			-	+	
p27 expression	-	23	18	5	0.00519
	+	15	11	4	
	++	12	3	9	
PCNA grading	I	17	16	1	0.000311
	II	20	13	7	
	III	13	3	10	
Histological grading	I	20	14	6	0.36624
	II	14	10	4	
	III	16	8	8	
Lymph node metastasis	-	43	27	16	0.6588
	+	7	5	2	
Total		50	32	18	

Figure 1

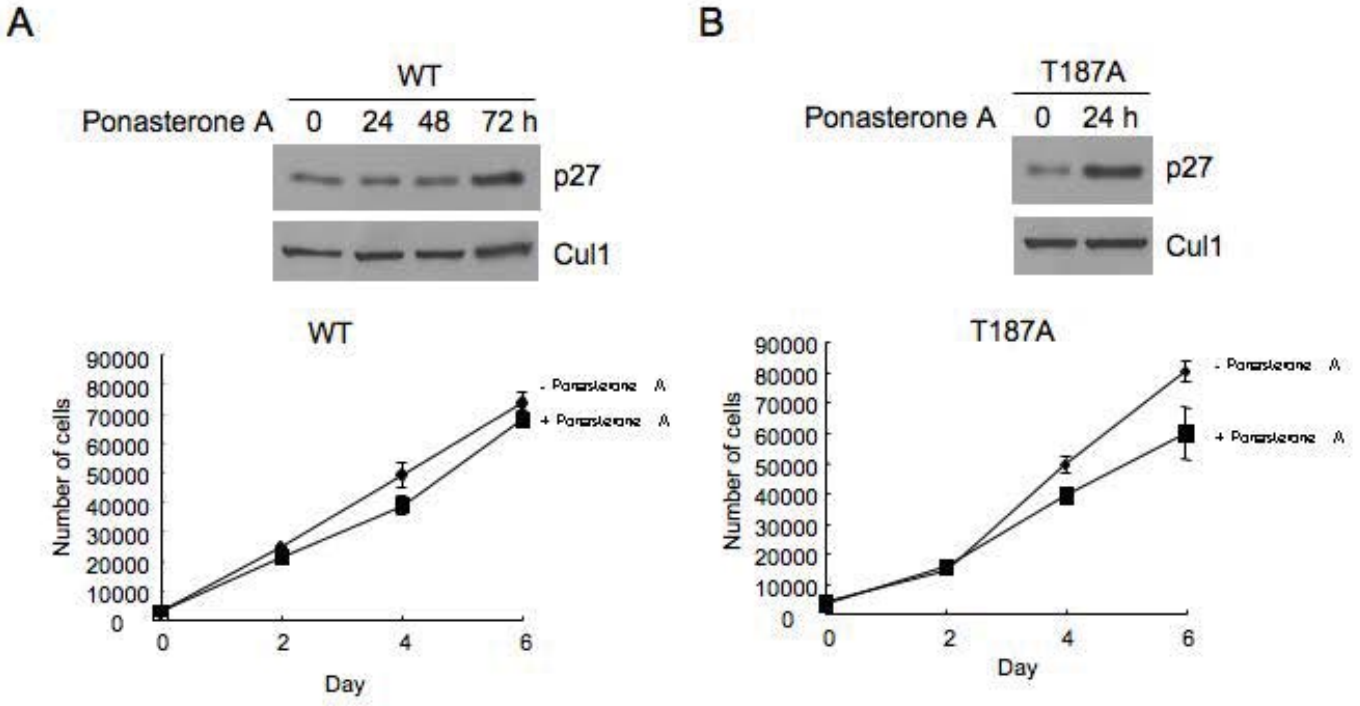


Figure 2

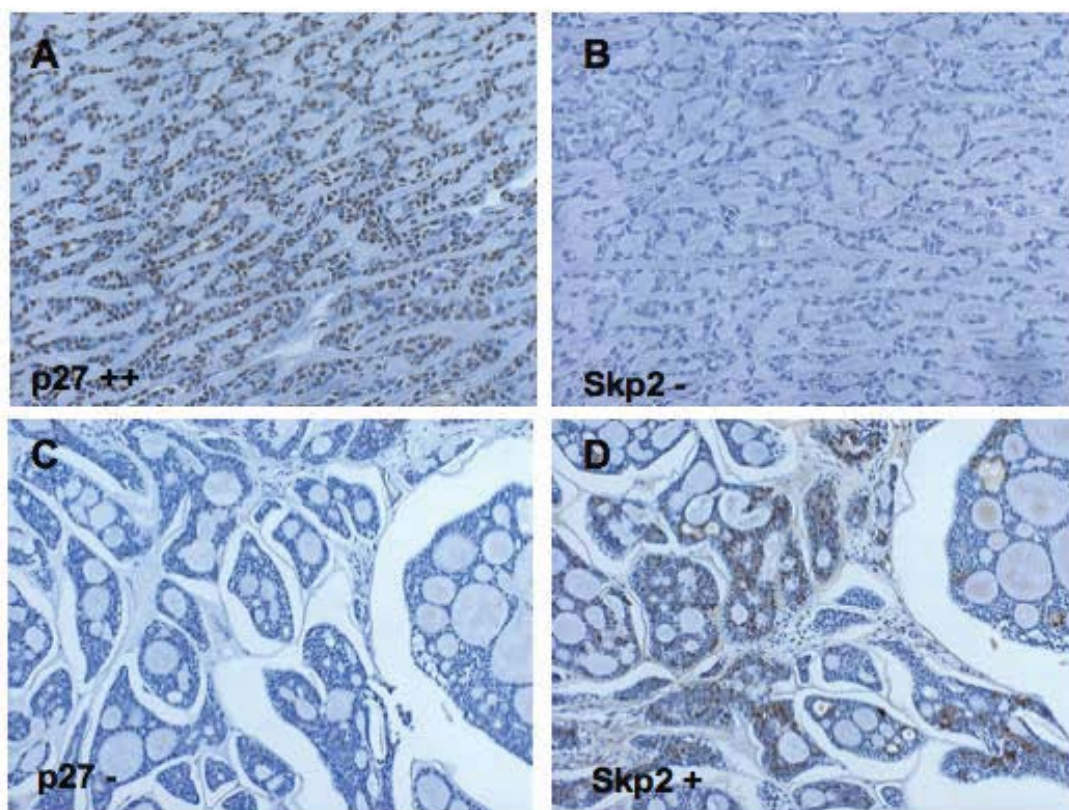
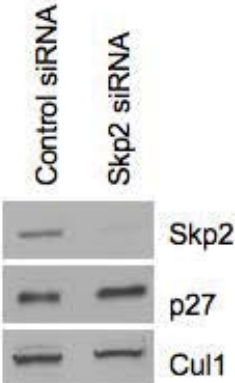

Figure 3

A



B

