

# BMJ Case Reports

## Full clinical cases submission template

<b>TITLE OF CASE</b> <i>Do not include "a case report"</i>
Recurrent venous thromboembolism after discontinuation of rivaroxaban therapy in a patient with antiphospholipid syndrome
<b>SUMMARY</b> <i>Up to 150 words summarising the case presentation and outcome (this will be freely available online)</i>
<p>A Antiphospholipid syndrome (APS) is a systemic autoimmune disease characterized by thrombotic events including thromboembolism (VTE) in association with the presence of antiphospholipid antibodies. The standard treatment of VTE historically consists of anticoagulation therapy with warfarin, a vitamin K antagonist. Recently, direct oral anticoagulants, including rivaroxaban have become available for the treatment of VTE. However, the choice of anticoagulant, and the duration of anticoagulation in patients with APS has not been determined yet due to lack of evidence.</p> <p>Here, we report a case of recurrent venous thrombosis after discontinuation of rivaroxaban therapy and avoiding sedentary life style in a patient with APS. We suggest that indefinite anticoagulation therapy might be needed even in low risk APS cases.</p>
<b>BACKGROUND</b> <i>Why you think this case is important – why did you write it up?</i>
<p>Antiphospholipid syndrome (APS) is a systemic autoimmune disease characterized by thrombotic events or pregnancy morbidity in association with the presence of antiphospholipid antibodies. The standard treatment of venous thromboembolism (VTE) historically consists of anticoagulation therapy with warfarin, a vitamin K antagonist [1]. Recently, direct oral anticoagulants (DOACs), including rivaroxaban have become available for the treatment of VTE [2].</p> <p>However, the choice of anticoagulant, and the duration of anticoagulation in patients with APS has not been determined yet due to lack of evidence. Life-long anticoagulation for secondary prevention of VTE is recommended in high risk APS patients, but duration of anticoagulation therapy should be determined based on patient-specific risk-benefit ratio. Discontinuation of anticoagulation might be considered in low risk patients with provoked VTE.</p> <p>Here, we report a case of recurrent venous thrombosis after discontinuation of rivaroxaban therapy and avoiding sedentary life style in a patient with APS. We suggest that indefinite anticoagulation therapy might be needed even in low risk APS cases.</p>
<b>CASE PRESENTATION</b> <i>Presenting features, medical/social/family history</i>
<p>A 61-year-old man presented at our hospital with a swelling and pain in his left leg and a history of being sedentary for more than 8 hours in a day. He had a history of chronic gastritis, smoking since 40 years, and no family history of thrombosis. The enhanced computed tomography (CT) showed thrombosis extending from the left proximal femoral vein to the popliteal vein with bilateral PE (Figure 1A). The left iliac vein was not compressed by the right iliac vein, which excluded May-thurner syndrome or iliac vein compression syndrome. Blood examination demonstrated elevation of D-dimer to 3.2 µg/mL, positive lupus anticoagulant, and negative anti-cardiolipin antibodies. Protein C, protein S, and antithrombin levels were within the normal range. APS was suspected as a cause of the VTE owing to the presence of thrombosis and positive lupus anticoagulant. He was administered a regular dose of 15 mg rivaroxaban and implantation of an inferior vena cava (IVC) filter, followed by a high dose of rivaroxaban (30 mg) for 21 days for acute VTE, with no heparin bridging.</p> <p>Venous echography revealed that the acute thrombus extending from the left femoral vein to</p>

# BMJ Case Reports

the popliteal vein was almost resolved in 14 days (Figure 2). The IVC filter was retrieved following the 14 days of dwell time. He was advised to avoid prolonged sitting and received 15 mg of rivaroxaban. In 6 months, administration of rivaroxaban was discontinued because venous echography showed no recurrence of VTE and D-dimer was not elevated (0.3 µg/mL). However, 5 months later, he complained of the same symptoms in his left leg and presented to our hospital again. The enhanced CT showed thrombosis extending from the left proximal femoral vein to the popliteal vein, with bilateral PE, although the thrombi were smaller than the previous thrombi (Figure 1B). Blood examination showed elevated D-dimer (2.5 µg/mL) and positive lupus anticoagulant. He was diagnosed with recurrent VTE complicated with APS. He was administered the same treatment with rivaroxaban after the temporary implantation of IVC filter and the thrombus was resolved.

## **INVESTIGATIONS** *If relevant*

## **DIFFERENTIAL DIAGNOSIS** *If relevant*

## **TREATMENT** *If relevant*

## **OUTCOME AND FOLLOW-UP**

He is still visiting the hospital without symptoms. It was suggested that he continue to receive rivaroxaban therapy for life, as long as he did not experience major bleeding.

## **DISCUSSION** *Include a very brief review of similar published cases*

In this case report, rivaroxaban was found to be effective for the treatment of VTE in a patient with APS, and that despite controlling a potential high risk trigger factor, recurrence of VTE was noted.

APS is relatively rare, compared with other inherited thrombophilia conditions, such as protein S deficiency. It is known that antiphospholipid antibodies are present in 10% of patients with deep vein thrombosis [1]. Thus, we suggest testing of antiphospholipid antibodies in all patients with VTE to avoid misdiagnosis of APS.

A small subset of patients with thrombophilic disorders (5–7%) was included in the EINSTEIN rivaroxaban trial; however, no specific information was recorded to identify the type of hypercoagulable disorder, and the antiphospholipid antibody status was also not systematically documented in the trial [2]. The guideline from the American College of Chest Physicians does not describe the treatment of VTE in patients with thrombophilia including APS, but describes thrombophilic disorders as a risk factor for recurrent VTE [3]. Thus, presence of APS could be suggested to have a role in the recurrence of VTE; however, the efficacy and safety of DOACs in preventing VTE in patients with APS has not been determined yet due to lack of evidence.

A report on a case series showed that there was no recurrence of thrombosis during the mean follow-up period of data collection in 8 patients with APS after warfarin was switched to DOACs due to recurring thrombosis and bleeding in patients [4]. Another case series report showed that 4 out of 13 patients with APS had recurrent thrombosis during rivaroxaban treatment [5]. A retrospective study showed that 2 of 24 patients with APS had thrombosis recurrence during treatment with DOACs, the median duration of which was 31 months [6]. The Rivaroxaban in Antiphospholipid Syndrome (RAPS) randomized controlled trial (RCT) showed that the percentage change in endogenous thrombin potential was higher in the rivaroxaban than in the warfarin group, indicating that rivaroxaban was inferior to warfarin in patients with APS. However, peak thrombin generation was lower with rivaroxaban; therefore, the overall thrombogram indicated no difference in thrombotic

# BMJ Case Reports

risk in patients with APS [7]. This suggested that rivaroxaban is a potentially effective and convenient alternative to warfarin in thrombotic APS patients. A meta-analysis showed that 16% of APS patients experienced a recurrent thrombosis while on DOACs with a mean duration of 12.5 months, indicating increased risk of thrombosis in APS patients treated with DOACs [8]. A systematic review of studies in patients with APS and recurrent thrombosis while on DOACs reported 19 cases of recurrent arterial or venous thrombosis out of 122 patients (15.6%) during a mean observation time of 12.6 months [9]. Thus, DOACs are not effective in all APS patients and should not be used routinely. Anticoagulant therapy with warfarin rather than a direct oral anticoagulant might be beneficial based on the lack of data regarding efficacy and safety of the DOACs in APS patients. Further clinical studies are needed to confirm the effectiveness of DOACs for VTE in patients with APS. The following RCTs are underway and results are awaited. Rivaroxaban in Thrombotic Antiphospholipid Syndrome (TRAPS), which is a randomized, controlled, open-label, noninferiority study, is investigating rivaroxaban 20 mg once daily compared to warfarin in patients with APS with a history of thrombosis [10]. The ASTRO-APS RCT also compares the effectiveness and safety of apixaban with those of warfarin in secondary prevention of thromboembolism among patients with a history of APS and thrombosis (<https://clinicaltrials.gov/>).

In patients with APS with a history of an unprovoked thrombotic event, lifelong anticoagulant therapy is based on the high likelihood of recurrence [11]. The benefit of prolonged anticoagulation is less certain in patients who are positive for antiphospholipid antibodies and in whom thrombosis was provoked [11]. However, discontinuation of anticoagulation in low-risk APS patients with a clearly provoked thrombosis, especially in the setting of low-titre antiphospholipid antibodies, can be considered after discussing the risks and benefits with the patient. We discontinued anticoagulation therapy 6 months after the first onset of VTE, because we thought he had low risk of recurrence of VTE due to the negative antiphospholipid antibody and lifestyle modification. However, he experienced recurrence of VTE, which was successfully treated.

In conclusion, VTE could recur after discontinuation of anticoagulants in patients with APS complicated with provoked VTE; thus, life-long anticoagulation should be discussed with patients based on their risks and benefits. Additional evaluation of DOAC use in patients with APS is necessary to provide further evidence.

## **LEARNING POINTS/TAKE HOME MESSAGES 3 to 5 bullet points – this is a required field**

- Prevalence of recurrent VTE is high in patients with APS.
- Duration of anticoagulation therapy should be determined based on patient-specific risk-benefit ratio in patients with APS.
- Life-long anticoagulation for secondary prevention of VTE should be discussed with APS patients based on their risk and benefit.

## **REFERENCES Vancouver style (Was the patient involved in a clinical trial? Please reference related articles)**

- [1] Andreoli L, Chighizola CB, Banzato A, Pons-Estel GJ, Ramire de Jesus G, Erkan D. Estimated frequency of antiphospholipid antibodies in patients with pregnancy morbidity, stroke, myocardial infarction, and deep vein thrombosis: a critical review of the literature. *Arthritis Care Res (Hoboken)*. 2013;65:1869-73.
- [2] Investigators E, Bauersachs R, Berkowitz SD, Brenner B, Buller HR, Decousus H, et al. Oral rivaroxaban for symptomatic venous thromboembolism. *N Engl J Med*. 2010;363:2499-510.
- [3] Kearon C, Akl EA, Ornelas J, Blaivas A, Jimenez D, Bounameaux H, et al. Antithrombotic Therapy for VTE Disease: CHEST Guideline and Expert Panel Report. *Chest*. 2016;149:315-52.
- [4] Betancur JF, Bonilla-Abadia F, Hormaza AA, Jaramillo FJ, Canas CA, Tobon GJ. Direct oral

# BMJ Case Reports

anticoagulants in antiphospholipid syndrome: a real life case series. *Lupus*. 2016;25:658-62.

[5] Martinelli I, Abbattista M, Bucciarelli P, Tripodi A, Artoni A, Gianniello F, et al. Recurrent thrombosis in patients with antiphospholipid antibodies treated with vitamin K antagonists or rivaroxaban. *Haematologica*. 2018;103:e315-e7.

[6] Gundabolu K, Bhatt V, Lunning M, Baljevic M. Efficacy of Direct Oral Anticoagulants (DOAC) in Patients with vdrome (APS). *Blood*. 2017; 130:4917

[7] Cohen H, Hunt BJ, Efthymiou M, Arachchillage DR, Mackie IJ, Clawson S, et al. Rivaroxaban versus warfarin to treat patients with thrombotic antiphospholipid syndrome, with or without systemic lupus erythematosus (RAPS): a randomised, controlled, open-label, phase 2/3, non-inferiority trial. *Lancet Haematol*. 2016;3:e426-36.

[8] Dufrost V, Risse J, Reshetnyak T, Satybaldyeva M, Du Y, Yan XX, et al. Increased risk of thrombosis in antiphospholipid syndrome patients treated with direct oral anticoagulants. Results from an international patient-level data meta-analysis. *Autoimmun Rev*. 2018.

[9] Dufrost V, Risse J, Zuily S, Wahl D. Direct Oral Anticoagulants Use in Antiphospholipid Syndrome: Are These Drugs an Effective and Safe Alternative to Warfarin? A Systematic Review of the Literature. *Curr Rheumatol Rep*. 2016;18(12):74

[10] Pengo V, Banzato A, Bison E, Zoppellaro G, Padayattil Jose S, Denas G. Efficacy and safety of rivaroxaban vs warfarin in high-risk patients with antiphospholipid syndrome: Rationale and design of the Trial on Rivaroxaban in AntiPhospholipid Syndrome (TRAPS) trial. *Lupus*. 2016;25:301-6.

[11] Garcia D, Erkan D. Diagnosis and Management of the Antiphospholipid Syndrome. *N Engl J Med*. 2018;378:2010-21.

## **FIGURE/VIDEO CAPTIONS** *figures should NOT be embedded in this document*

Figure 1. Enhanced CT imaging shows thrombi in the pulmonary arteries and thrombus in the left femoral vein (arrow)

Figure 2. Venous echographic imaging treatment showing thrombus in the left femoral vein before rivaroxaban (A blue arrow) and thrombus resolved after rivaroxaban treatment (B blue arrow). Red arrow indicates superficial femoral artery.

## **PATIENT'S PERSPECTIVE** *Optional but strongly encouraged – this has to be written by the patient or next of kin*

N/A

## **Copyright Statement**

I, [*ShusukeHUSUKE Yagi*], The Corresponding Author, has the right to assign on behalf of all authors and does assign on behalf of all authors, a full assignment of all intellectual property rights for all content within the submitted case report (other than as agreed with the BMJ Publishing Group Ltd ("BMJ")) in any media known now or created in the future, and permits this case report (if accepted) to be published on BMJ Case Reports and to be fully exploited within the remit of the assignment as set out in the assignment which has been read. <http://casereports.bmj.com/site/misc/copyright.pdf>.

**Date: September14, 2018**

**PLEASE SAVE YOUR TEMPLATE WITH THE FOLLOWING FORMAT:**

# BMJ Case Reports

Corresponding author's last name and date of submission, eg,

Smith\_September\_2017.doc

Figure 1

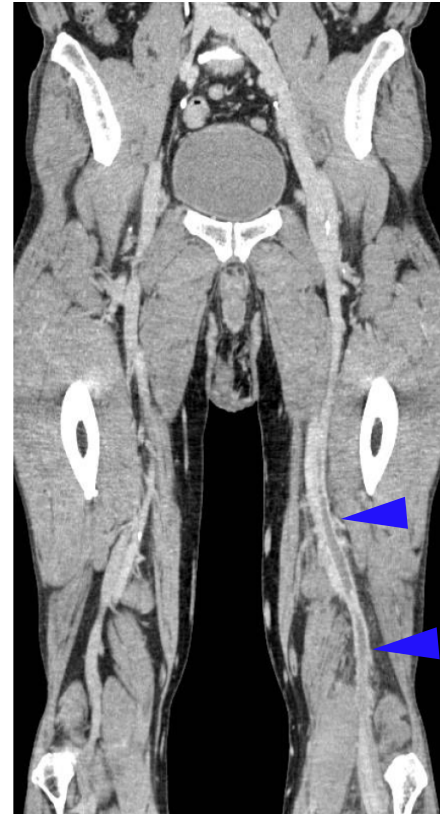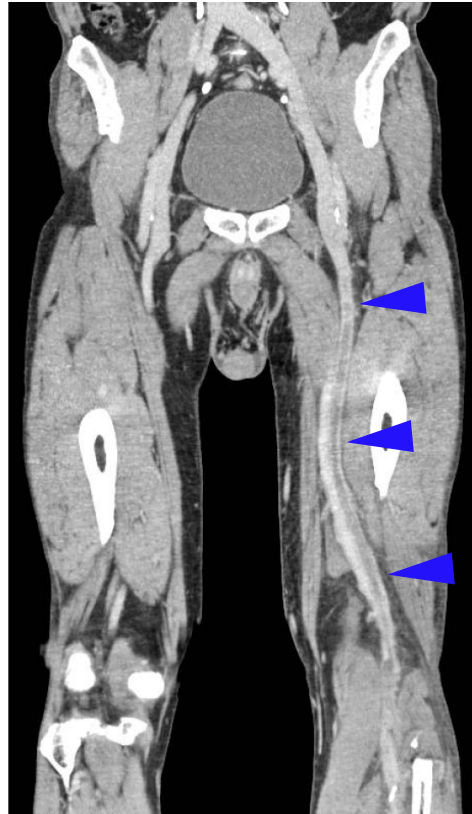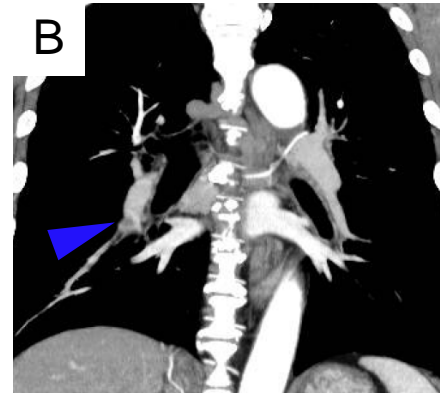
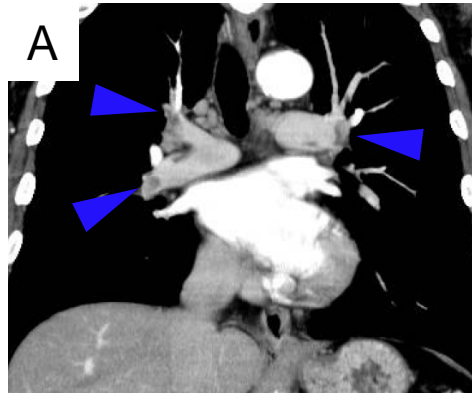


Figure 2

