

CASE REPORT: A case of unilateral mandibular condylar osteochondroma treated with ipsilateral condylectomy and contralateral ramus osteotomy

Authors: Eiji Tanaka, DDS, PhD^a; Chieko Shiota, DDS^b; Minami Sato, DDS^b; Shinji Fujihara, DDS, PhD^c; Toshiro Kondoh, DDS, PhD^d; and Shingo Kuroda, DDS, PhD^e

Authors' affiliations and positions

A Professor and Chair, Department of Orthodontics and Dentofacial Orthopedics, Institute of Biomedical Sciences, Tokushima University Graduate School, Tokushima, Japan; Distinguished Professor, Faculty of Dentistry, King Abdulaziz University, Jeddah, Saudi Arabia.

b, c and e from Department of Orthodontics and Dentofacial Orthopedics, Institute of Biomedical Sciences, Tokushima University Graduate School, Tokushima, Japan.

b: Graduate Student, c: Assistant Professor, and e: Associate Professor

d Professor and Chair, Department of Maxillofacial Surgery, Nihon University School of Dentistry at Matsudo, Chiba, Japan.

Running title: Treatment of mandibular condylar osteochondroma

Key word: Osteochondroma, Condylectomy, Orthognathic surgery

Correspondence to: Eiji Tanaka, DDS, PhD

Department of Orthodontics and Dentofacial Orthopedics, Institute of Biomedical Sciences, Tokushima University Graduate School, 3-18-15 Kuramoto-Cho, Tokushima 770-8504, Japan.

Tel: +81 88 6337356 / Fax:+81 88 6339138

E-mail: etanaka@tokushima-u.ac.jp

Highlights

- ▶ We successfully treated a case of unilateral mandibular condylar osteochondroma with mandibular condylectomy.
- ▶ After 38 months of active treatment with orthognathic surgery, an ideal occlusion with an adequate interincisal relationship was achieved.
- ▶ Facial asymmetry and mandibular protrusion were dramatically improved.
- ▶ The differences between the deviation and non-deviation sides were decreased to less than 1.11 mm.
- ▶ The acceptable occlusion and symmetric face were maintained throughout 1-year retention period.

CASE REPORT: A case of unilateral mandibular condylar osteochondroma treated with ipsilateral condylectomy and contralateral ramus osteotomy

ABSTRACT

We successfully treated a case of facial asymmetry involved in unilateral mandibular condylar osteochondroma with ipsilateral mandibular condylectomy and contralateral ramus osteotomy. A female, 32-year 11-month of age, had a chief complaint of facial asymmetry which initiated about 10 years ago. A mirror image analysis using a non-contact 3D image scanner revealed that the soft tissue on the deviated side was protruded more than 5.50 mm compared with the non-deviated side. The patient was diagnosed as facial asymmetry with a skeletal Class III jaw-base relationship caused by unilateral mandibular condylar osteochondroma. After 18 months of preoperative orthodontic treatment, ipsilateral condylectomy and contralateral sagittal split ramus osteotomy were performed. As the results of postoperative orthodontic treatment for 20 months, an ideal occlusion having a Class I molar relationship with an adequate interincisal relationship was achieved. Facial asymmetry and mandibular protrusion were dramatically improved, and the differences between the deviation and non-deviation sides were decreased to less than 1.11 mm. The acceptable occlusion and symmetric face were maintained throughout 1-year retention period. Conclusively, our results indicated the stability after condylectomy without condylar reconstruction in a patient with unilateral condylar osteochondroma.

INTRODUCTION

Facial asymmetry, commonly observed in orthodontic patients, causes both functional and esthetic problems. It has been still difficult to determine the etiology in most cases of facial asymmetry, the etiology includes congenital disorders, acquired diseases, and traumatic and developmental deformities are suggested.^{1,2} In particular, condylar hyperplasia or hypoplasia, ankylosis of the temporomandibular joint (TMJ), displaced condylar fractures, and hemifacial microsomia could be enumerated as cause of facial asymmetry.

Osteochondroma, one of the most common benign tumors of bone, is rare in the craniofacial region, and the most common sites of occurrence in the craniofacial region are the coronoid process and mandibular condyle.³⁻⁶ The growth of osteochondroma in the craniofacial region usually will be slow,⁴ causing morphologic and functional disturbances, leading TMJ dysfunction, malocclusion and facial deformities.^{7,8} The secondary condylar hypertrophy enlarges the mandibular condyle, resulting in the worsening of a dentofacial deformity such as mandibular prognathism if the condylar hypertrophy occurs bilaterally and facial asymmetry if unilaterally.

The mandibular condylar osteochondroma has been traditionally treated with condylectomy with or without condylar reconstruction.^{3,5,6,9,10} Recently, several comprehensive protocols have been developed and published to establish harmony and balance among function, esthetics, and occlusion,^{9,10}: however, little study is available to quantify facial asymmetry in patient with unilateral osteochondroma through orthodontic-orthognathic treatment.

The purpose of this article is to present an adult case of facial asymmetry

involved in unilateral mandibular condylar osteochondroma treated with ipsilateral condylectomy and contralateral ramus osteotomy.

DIAGNOSIS AND ETIOLOGY

A 32-year and 1-month-old female had a chief complaint of facial asymmetry. She presented mandibular deviation to the right (Fig. 1), with onset around the age of 22 years. During the meantime, she had no pain and discomfort at the left TMJ and was conscious of slow but progressive worsening facial asymmetry. She was diagnosed as mandibular condylar osteochondroma at Nihon University Hospital at Matsudo. Her facial profile was straight with a slight protrusion of lower lip. In smiling, the position of the right mouth corner was lower than that of the left one.

Surface images of the facial soft-tissue were recorded using a non-contact 3D image scanner (Danae200, NEC Engineering, Tokyo, Japan). The images were taken with the patient in a natural head posture, eye open and relaxed facial musculature. A mirror-image analysis was performed to objectively quantify the degree of facial asymmetry. The method for the mirror image of the face was as follows: the left side was mirrored along the midsagittal plane. The mirror image was then superimposed over the right side. The differences of the mirror image and the original surface model were calculated and expressed with a customized color scale (in millimeters). As the result, the marked differences of more than 5.50 mm were localized at the right lower third face from the right mouth corner to chin (Fig. 2A).

Anterior crossbite of -2.0 mm was observed, and the molar relationships were Angle Class I on the right side and Class III on the left side (Fig. 3). The

mandibular midline shifted to the right by 7.0 mm, although the maxillary midline was almost coincident to the facial one. The panoramic radiograph and computed tomography (CT) showed exophytic tumor extensions from the left condyle forward. Furthermore, maxillary sinusitis was found on the right side (Fig. 4).

Cephalometric analysis, when compared with the Japanese adult female norms,¹¹ showed a skeletal Class III jaw-base relationship (ANB, $+0.2^\circ$) (Fig. 4). The mandibular plane angle was within the normal range (FMA, 32.6°). The inclinations of the maxillary and mandibular incisors were also within the normal range. In the frontal cephalogram, Menton shifted 3.5 mm to the right.

To examine masticatory muscle function, electromyographic (EMG) and mandibular kinesiographic (MKG) recordings were conducted simultaneously. Activities of both the anterior temporal and masseter muscles were measured using bipolar surface electrodes, which were 6-mm-diameter silver-silver chloride electrodes. The patient was instructed to clench with maximum effort three times with an intervening interval of 10 seconds. The activities of both anterior temporal and masseter muscles were normally balanced during clenching. For MKG recording, movement of the incisal point was recorded during 50-second unilateral gum chewing. As the result, a ratio of the number of strokes showing abnormal chewing trajectory (especially reverse type) to the total chewing strokes was higher during right-side gum chewing. Furthermore, the midline of mandibular central incisors shifted 4.0 mm to the left during maximum mouth opening.

TREATMENT OBJECTIVES

The patient was diagnosed as facial asymmetry with a skeletal Class III jaw-base relationship caused by unilateral mandibular condylar osteochondroma. The treatment objectives were to (1) correct the facial asymmetry, (2) correct the anterior crossbite and establish ideal overjet and overbite, and (3) achieve an acceptable occlusion with a good functional Class I occlusion. Since the cause of the anterior crossbite and the asymmetric profile was suggested to have been condylar hypertrophy, we planned to perform low condylectomy on the left side and a sagittal split ramus osteotomy on the right side.

TREATMENT ALTERNATIVES

Although mandibular condylar osteochondroma is commonly a benign tumor of bone, the growth of tumor results in masticatory disturbance due to malocclusion, facial deformity, morphological collapse, and TMJ dysfunction. Therefore, osteochondroma of the mandibular condyle has to be managed by condylectomy. High condylectomy with conservative resection of the tumor may preserve some or all of the condylar head; however, the more recurrence of tumor may be detected compared to the total condylectomy. In the present case, low condylectomy with complete resection of the tumor was performed.

Recently several cases of mandibular condylar osteochondroma treated with low condylectomy and condylar reconstruction have been reported. The condylectomy and condylar reconstruction, with simultaneous correction of the secondary dentofacial deformities using orthognathic procedures, might be a better approach to manage osteochondroma accompanied by dentofacial

deformities. However, no information has been available about improvement of masticatory function after these surgical procedures. Because the lateral pterygoid muscles are not active after low condylectomy, changes in masticatory function are subjected to occur irrespective of condylar reconstruction. As a consequence, we decided to treat her without condylar reconstruction which causes less pain and discomfort for patients.

TREATMENT PROGRESS

Prior to orthodontic treatment, the patient had a sinus surgery to improve the sinusitis. At the age of 32 years and 3 months, 0.018-in slot preadjusted edgewise appliances were placed on both arches. After 18 months of preoperative orthodontic treatment, ipsilateral condylectomy and contralateral sagittal split ramus osteotomy were performed. Histologic examination of the resected condylar specimen revealed a thickened cartilaginous cap over the head of the condyle and islands of cartilage within the condylar bone, confirming the diagnosis of osteochondroma (Fig. 5).

Intermaxillary fixation was performed for 7 days, and mouth opening training was initiated thereafter. After 20 months of postoperative orthodontic treatment, an acceptable and stable occlusion was achieved. Immediately after the removal of edgewise appliances, lingually bonded retainers were placed on both dentitions. A tooth positioner was also used for retention but only wore at night. The total active treatment period was 38 months.

TREATMENT RESULTS

At the end of active orthodontic treatment, an ideal occlusion having a Class I molar relationship with an adequate interincisal relationship was achieved (Figs. 6 and 7). Facial asymmetry and mandibular protrusion were dramatically improved, and the difference of the heights of the right and left mouth corners was reduced (Fig. 6).

With regard to the facial asymmetry, a mirror-image analysis showed the differences of the mirror image and the original right surface model were less than 1.11 mm in her whole face (Fig. 2B).

In panoramic radiograph and CT images, left condyle with tumor was removed at the condylar neck (Fig. 8). Cephalometric evaluation showed mandibular setback of 3.0 mm at Point B to the reference line, which was defined as a perpendicular line to the Sella-Nasion plane through Sella (Fig. 9A-C; Table). A skeletal Class I jaw relationship was achieved (ANB 3.7°). Because the mandible was moved in a backward and downward direction, the mandibular plane angle was increased by 1.4° as expected before surgery. From the frontal cephalogram, the mandibular deviation to the right was improved (Figs. 8 and 9D).

The movement of incisal point shifted to the left, and the midline of mandibular central incisors shifted 6.0 mm to the left during maximum mouth opening. The activities of both anterior temporal and masseter muscles during clenching were almost similar to those recorded before treatment.

After 1 year retention, an acceptable occlusion was maintained (Fig. 10). The skeletal Class I jaw relationship was maintained (ANB 3.6°), and the facial profile and occlusion were acceptable (Fig. 11; Table). In the frontal cephalogram, no

relapse of the mandibular deviation was found (Figs. 9D and 11). The patient had no masticatory disturbance, although the mandibular shift to the left during chewing was remained. Overall facial balance was maintained well, and the bilateral mouth corners were symmetrically positioned in smiling.

From the surface images of the facial soft-tissue, the differences of the mirror image and the original left surface model were maintained less than 1.11 mm in her whole face, resulting in the almost symmetric face (Fig. 2C).

DISCUSSION

Regarding the etiology of osteochondroma, various theories have been reported.^{3, 12, 13} Among them, Lichtenstein's theory which proposed that osteochondroma develops due to metaplastic change in the periosteum has been widely accepted.¹⁴ The periosteum characterized by multipotent membrane has the potential to develop osteoblasts and chondroblasts. Excessive and/or abnormal mechanical load to the condyle may be one of the triggers to differentiate osteochondroma from condylar hypertrophy. It is reported that most of the cases with condylar osteochondroma had a positive history of trauma to the condyle.^{15,16} Furthermore, it is believed that stress in the regions of tendinous insertion, where focal accumulations of cells with cartilaginous potential exist, leads to formation of these tumors.¹⁷ This may explain the fact that, in the mandible, these lesions often arise at the coronoid process (temporalis muscle insertion) and anteromedial condylar region (lateral pterygoid muscle insertion). The present patient had no obvious history of macrotrauma at condyle, and then the etiopathology of osteochondroma still remains unknown; however, the

responsible factor may be also involved in abnormal and/or excessive microtrauma and impact to condylar region.

Osteochondroma of the mandibular condyle is traditionally managed by total condylectomy or conservative resection of the tumor. The former may be associated with a loss of vertical dimension, occlusal interference, and deviation on mouth opening, but has been shown to be definitely curative with no recurrence.¹⁸ The latter approach that preserves some or all of the condylar head has been more frequently reported in recent period; however, the more recurrence of tumor may be detected compared to the total condylectomy. In the present case, the total condylectomy was performed without condylar reconstruction. At 32 months after the surgery, an acceptable occlusion was maintained without recurrence of facial asymmetry. The patient had no masticatory disturbance, although the mandible shifted to the left during chewing. Our results indicated the availability of long-term stability after condylectomy without condylar reconstruction in a patient with unilateral condylar osteochondroma.

In the present case, facial asymmetry was quantified through the whole treatment period by using a non-contact 3D image scanner. Before treatment, soft-tissue asymmetry was localized at the right lower third face from mouth corner to chin, and the differences between the deviation and non-deviation sides were more than 5.50 mm. After the orthognathic surgery, the differences were less than 1.11 mm. Furthermore, the acquired facial symmetry was well maintained after 1 year retention (33 months after surgery). The goals of orthognathic surgery are to improve the facial aesthetics, as well as to correct

the stomatognathic dysfunction associated with occlusal and skeletal discrepancies.^{19,20} In this line, accurate prediction of postsurgical facial appearance is of great importance for orthognathic treatment²¹; however, it is still very difficult to predict the postoperative facial profile and frontal view, and frontal view in particular. In the present case, correction of skeletal discrepancy led to improve soft-tissue asymmetry. In quantitative aspect, the unilateral mandibular setback of 3 mm with rotation resulted in the correction of more than 3.33 mm in soft-tissue asymmetry. According to Claes et al.,²² objective facial assessments at different time points and under varying expressions are required to improve future treatment. Therefore, database of the relationship between the hard and soft tissues in both the vertical and transverse directions are available to predict the postoperative facial profile.

CONCLUSIONS

We reported the successful treatment of a patient with facial asymmetry involved in unilateral mandibular condylar osteochondroma treated with ipsilateral condylectomy and contralateral ramus osteotomy. After the treatment, acceptable occlusion was obtained and no relapse of the facial asymmetry was recognized for 32 months. Our results indicated the availability of long-term stability after condylectomy without condylar reconstruction in a patient with unilateral condylar osteochondroma.

REFERENCES

1. Cohen MM Jr: Perspectives of craniofacial asymmetry. Part III. Common and/or well known causes of asymmetry. *Int J Oral Maxillofac Surg* 1995;24:127-33.
2. Reyneke JP, Tsakiris P, Kienle FA. A simple classification for surgical planning of maxillomandibular asymmetry. *Br J Oral Maxillofac Surg* 1997;35:349-51.
3. Karras SC, Wolford LM, Cattrell DA. Concurrent osteochondroma of the mandibular condyle and ipsilateral cranial base resulting in temporomandibular joint ankylosis: report of a case and review of the literature. *J Oral Maxillofac Surg* 1996;54:640-6.
4. Meng Q, Chen S, Long X, Cheng Y, Deng M, Cai H. The clinical and radiographic characteristics of condylar osteochondroma. *Oral Surg Oral Med Oral Pathol Oral Radiol* 2010;114:e66-74.
5. Wolford LM, Movahed R, Dhameja A, Allen WR. Low condylectomy and orthognathic surgery to treat mandibular condylar osteochondroma: A retrospective review of 37 cases. *J Oral Maxillofac Surg* 2014;72:1704-28.
6. Roychoudhury A, Bhatt K, Yadav R, Bhutia O, Roychoudhury S. Review of steochondroma of mandibular condyle and report of a case series. *J Oral Maxillofac Surg* 2011;69:2815-23.
7. Graziano P, Spinzia A, Abbate V, Romano A. Intra-articular loose osteochondroma of the temporomandibular joint. *Int J Oral Maxillofac Surg* 2009;41:1505-8.

8. Li H, Hu J, Luo E, Zhu S, Li J. Treatment of osteochondroma in the mandibular condyle and secondary dentofacial deformities using surgery combined with orthodontics in adults. *J Oral Maxillofac Surg* DOI: 10.1016/j.joms.2014.03.021.
9. Ramos-Murguialday M, Morey-Mas MÁ, Janeiro-Barrera S, García-Sánchez A, Molina-Barraguer I, Iriarte-Ortabe JI. Osteochondroma of the temporomandibular joint: report of 2 cases emphasizing the importance of personalizing the surgical treatment. *Oral Surg Oral Med Oral Pathol Oral Radiol* 2012;113:e41-7.
10. Song D, Zhu S, Hu J, Li J, Luo E. Use of ramus osteotomy for the treatment of osteochondroma in the mandibular condyle. *J Oral Maxillofac Surg* 2009;67:676-80.
11. Wada K, Matsushita K, Shimazaki S, Miwa Y, Hasuike Y, Susami R. An evaluation of a new case analysis of a lateral cephalometric roentgenogram. *J Kanazawa Med Univ* 1981;6:60–70.
12. Ribas M, De O, Martins WD, de Sousa MH, Zanferrari FL, Lanzoni T. Osteochondroma of the mandibular condyle: literature review and report of a case. *J Contemp Dent Pract* 2007;8:52-9.
13. Vezeau PJ, Fridrich KL, Vincent SD. Osteochondroma of the mandibular condyle: literature review and report of two atypical cases. *J Oral Maxillofac Surg* 1995;53:954-63.
14. Lichtenstein L. *Bone Tumors* (ed 5). St Louis, MO, CV Mosby, 1977.

15. Ortakoglu K, Akcam T, Sencimen M, Karakoc O, Ozyigit HA, Bengi O. Osteochondroma of the mandible causing severe facial asymmetry: A case report. *Oral Surg Oral Med Oral Pathol Oral Radiol Endod* 2007;103:e21-8.
16. Cimino R, Steenks MH, Michelotti A, Farella M, PierFrancesco N. Mandibular condyle osteochondroma. Review of the literature and report of a misdiagnosed case. *J Orofac Pain* 2003;17:254-61.
17. Wolford LM, Mehra P, Franco P. Use of conservative condylectomy for treatment of osteochondroma of the mandibular condyle. *J Oral Maxillofac Surg* 2002;60:262-8.
18. Iizuka T, Schroth G, Laeng RH, Ladrach K. Osteochondroma of the mandibular condyle: report of a case. *J Oral Maxillofac Surg* 1996;54:495-501.
19. Jacobson A. Psychological aspects of dentofacial esthetics and orthognathic surgery. *Angle Orthod* 1984;54:18-35.
20. Bell R, Kiyak HA, Joondeph DR, McNeill RW, Wallen TR. Perceptions of facial profile and their influence on the decision to undergo orthognathic surgery. *Am J Orthod* 1985;88:323-32.
21. Abe N, Kuroda S, Furutani M, Tanaka E. Data-based prediction of soft tissue changes after orthognathic surgery: clinical assessment of new simulation software. *Int J Oral Maxillofac Surg* 2015;44:90-6.
22. Claes P, Walters M, Clement J. Improved facial outcome assessment using a 3D anthropometric mask. *Int J Oral Maxillofac Surg* 2012;41:324-30.

FIGURE LEGENDS

Figure 1 Pretreatment facial and oral photographs.

Figure 2 Evaluation of facial soft-tissue by the mirror imaging method.

(A) Pretreatment, (B) Posttreatment, (C) At 1-year retention

Figure 3 Pretreatment dental casts.

Figure 4 Pretreatment cephalograms, panoramic radiograph and images of computed tomography.

Figure 5 Haematoxylin & Eosin stain showing endochondral ossification progressing beneath the cartilaginous cap.

Figure 6 Posttreatment facial and intraoral photographs.

Figure 7 Posttreatment dental casts.

Figure 8 Posttreatment cephalograms, panoramic radiograph, and images of computed tomography.

Figure 9 Cephalometric tracings before treatment (black line), posttreatment (red line), and one-year retention (blue line) superimposed on A, Sella-Nasion plane at Sella; B, the anterior palatal contour; C, the

mandibular plane at Menton; and D, Latero-orbitale line at Crista galli.

Figure 10 One-year retention facial and intraoral photographs.

Figure 11 Cephalograms and panoramic radiograph at one-year retention.

Figure 1
[Click here to download high resolution image](#)

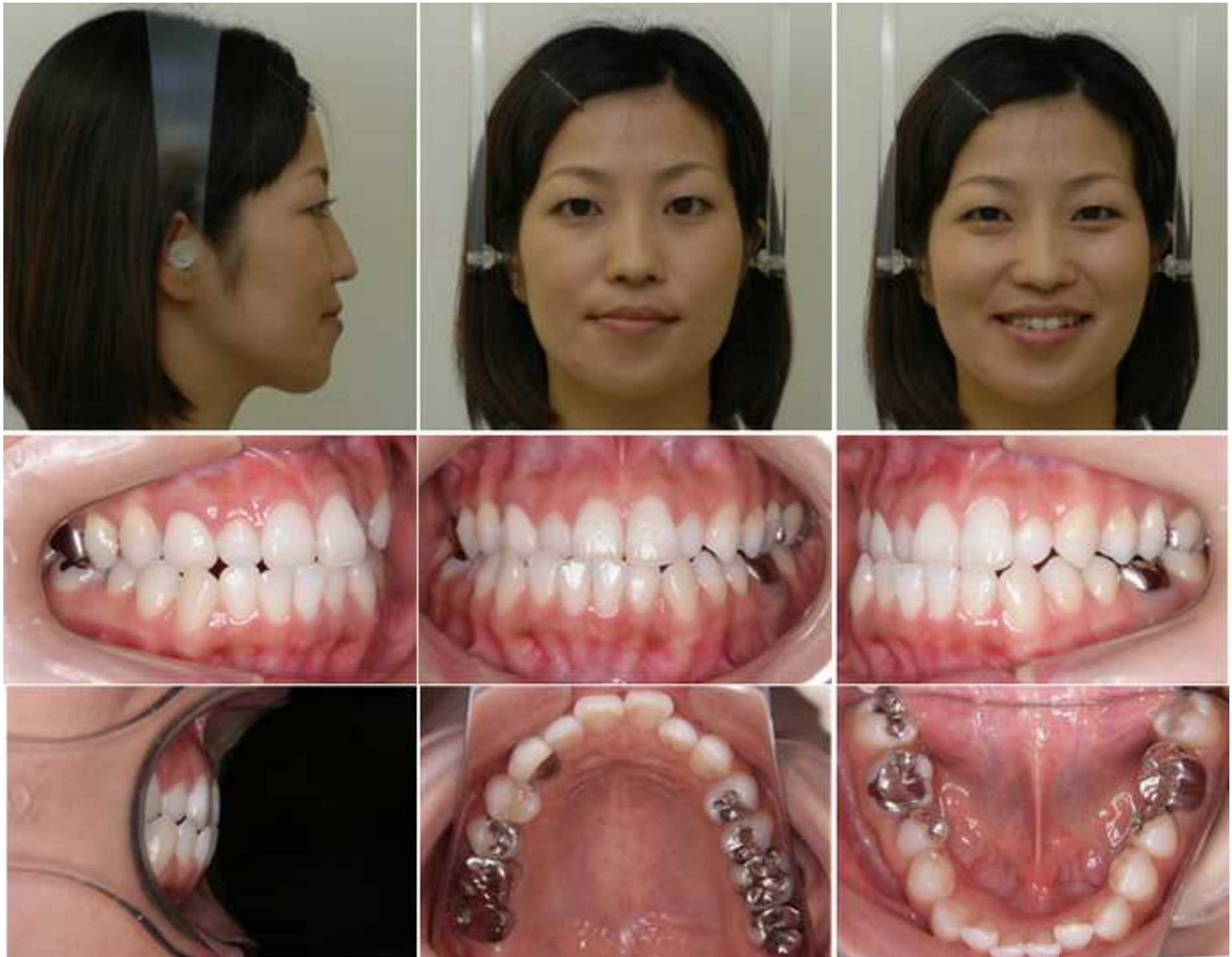

Figure 2
[Click here to download high resolution image](#)

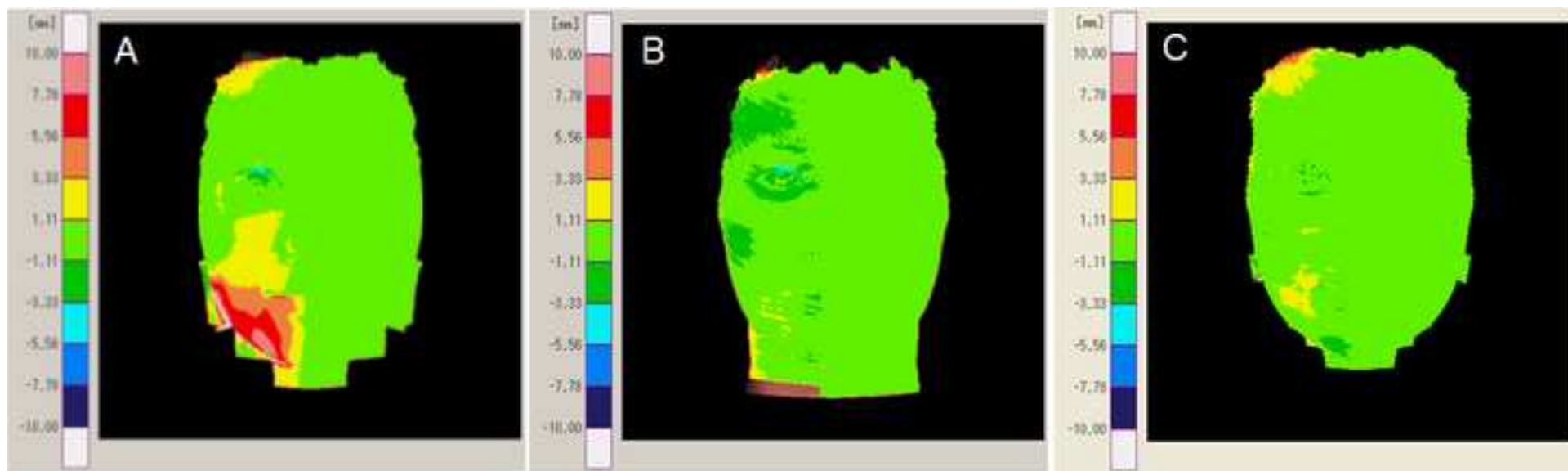


Figure 3
[Click here to download high resolution image](#)

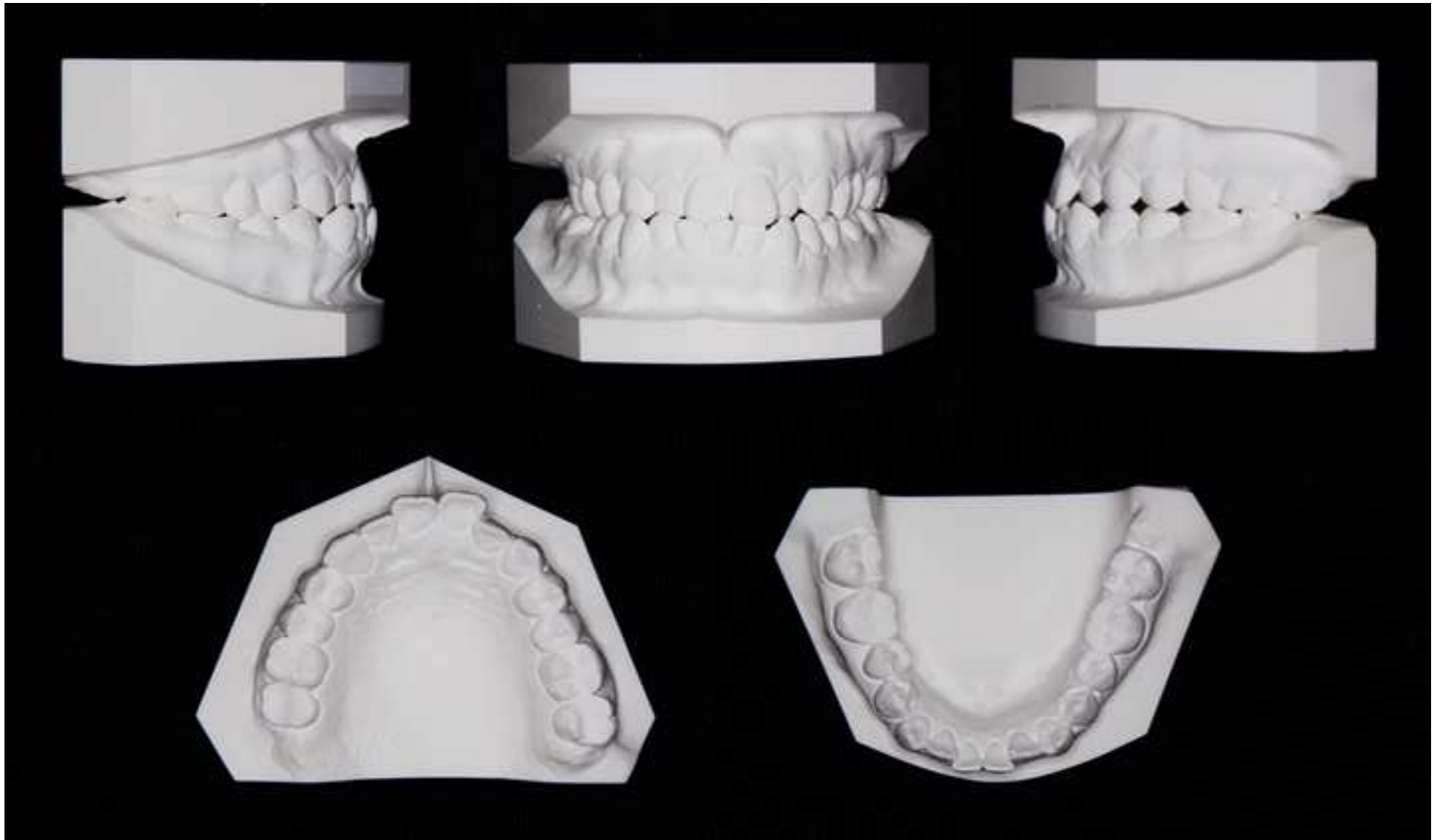


Figure 4
[Click here to download high resolution image](#)

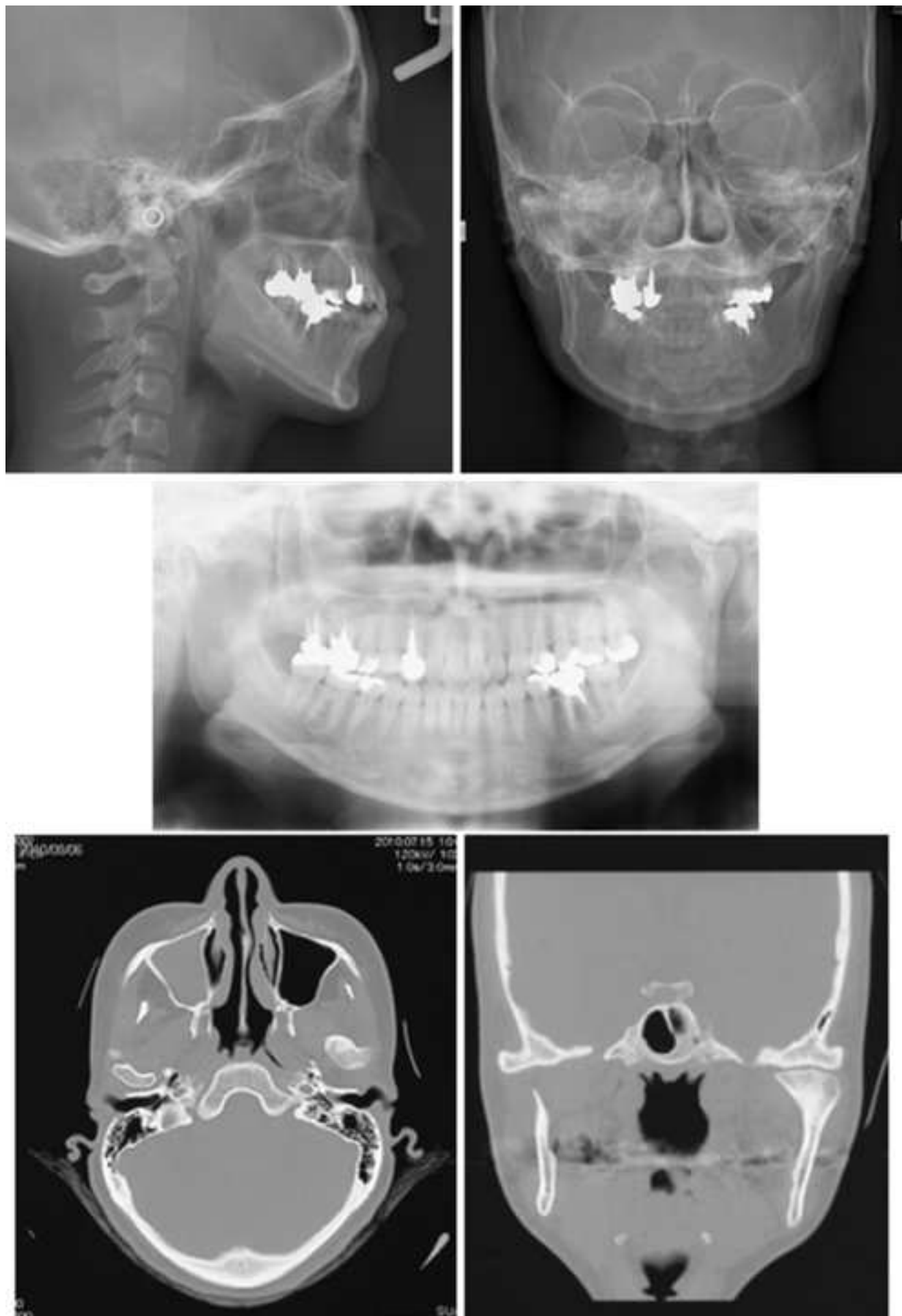


Figure 5
[Click here to download high resolution image](#)

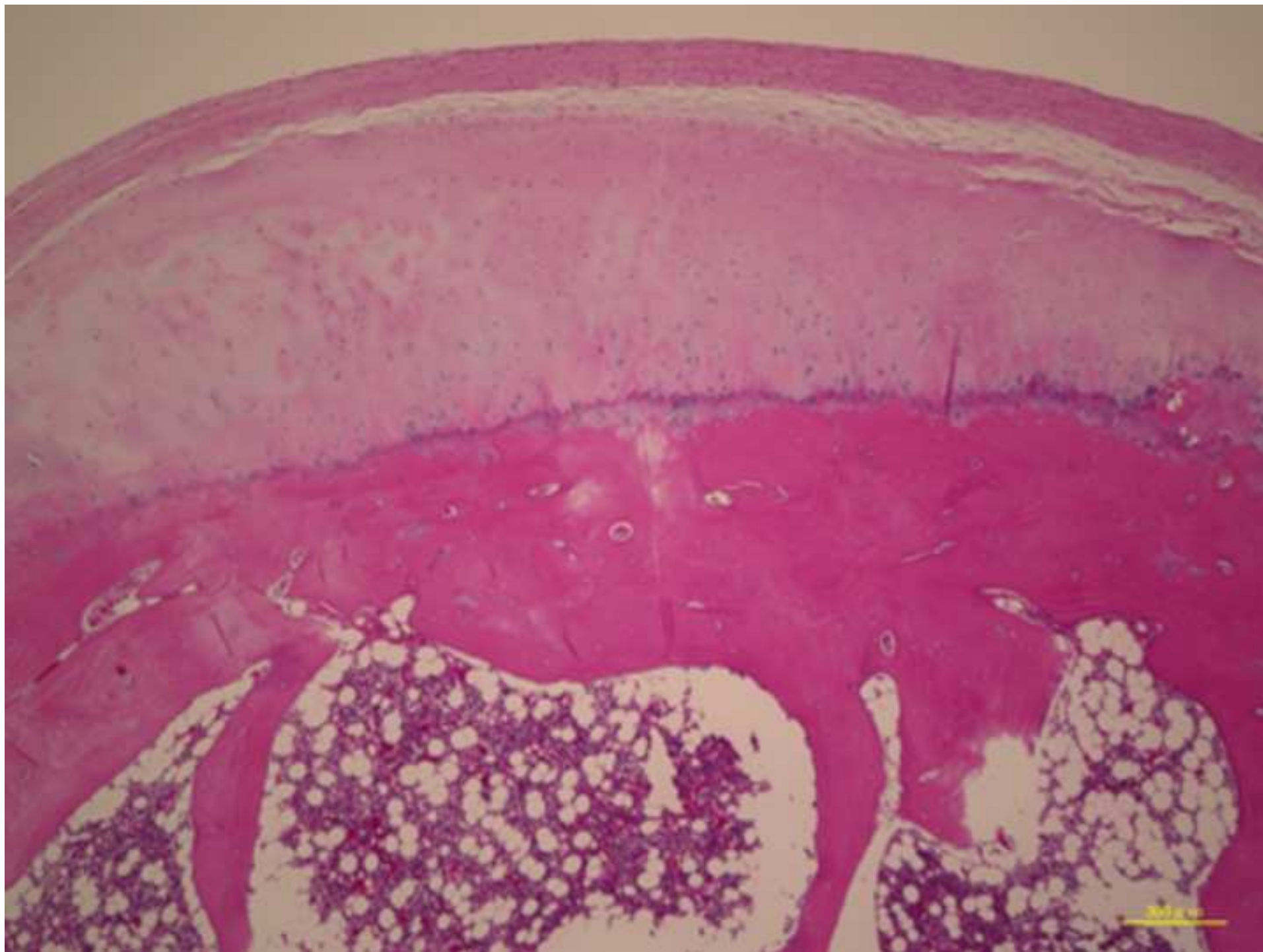


Figure 5
[Click here to download high resolution image](#)

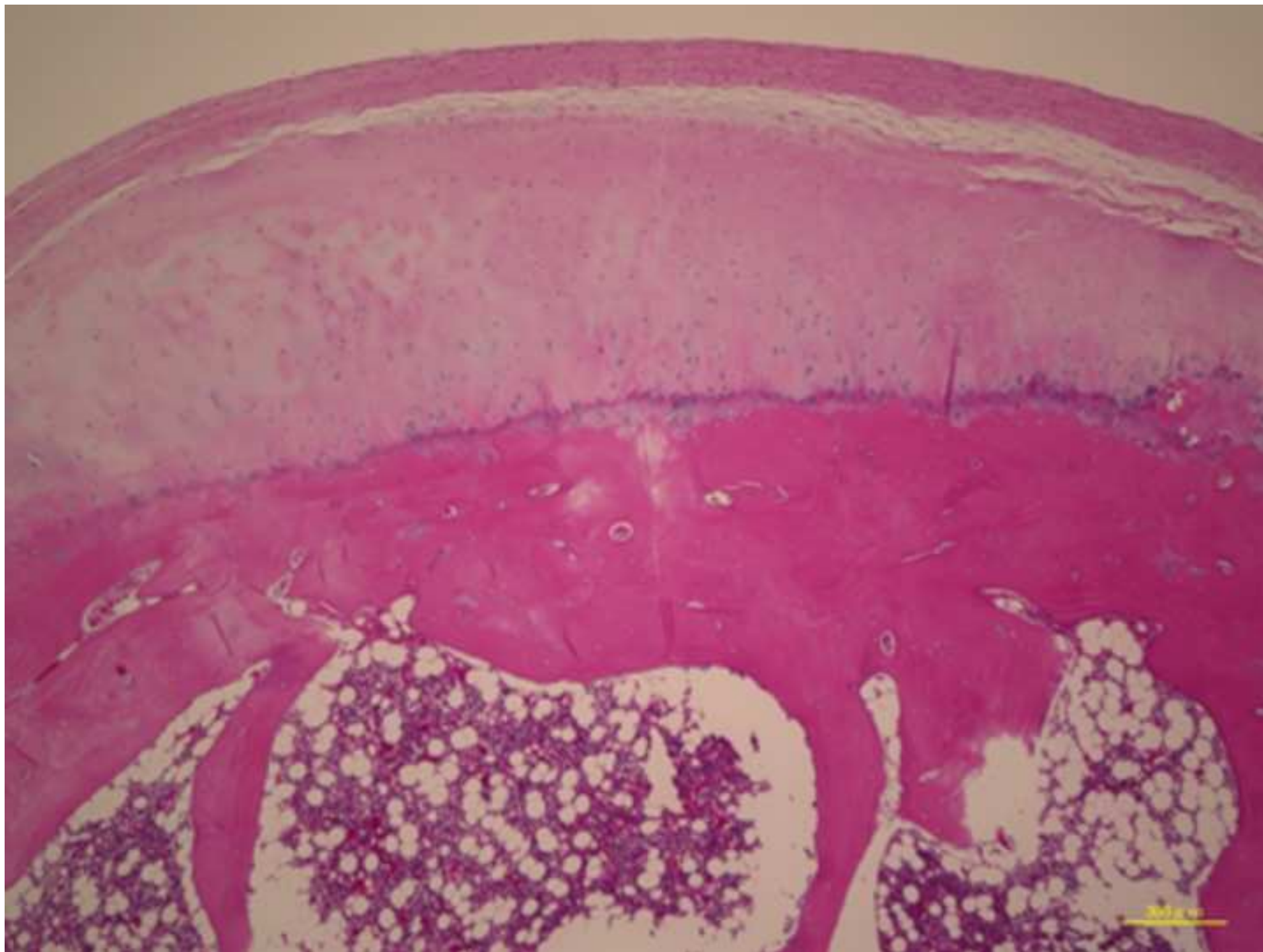


Figure 6
[Click here to download high resolution image](#)

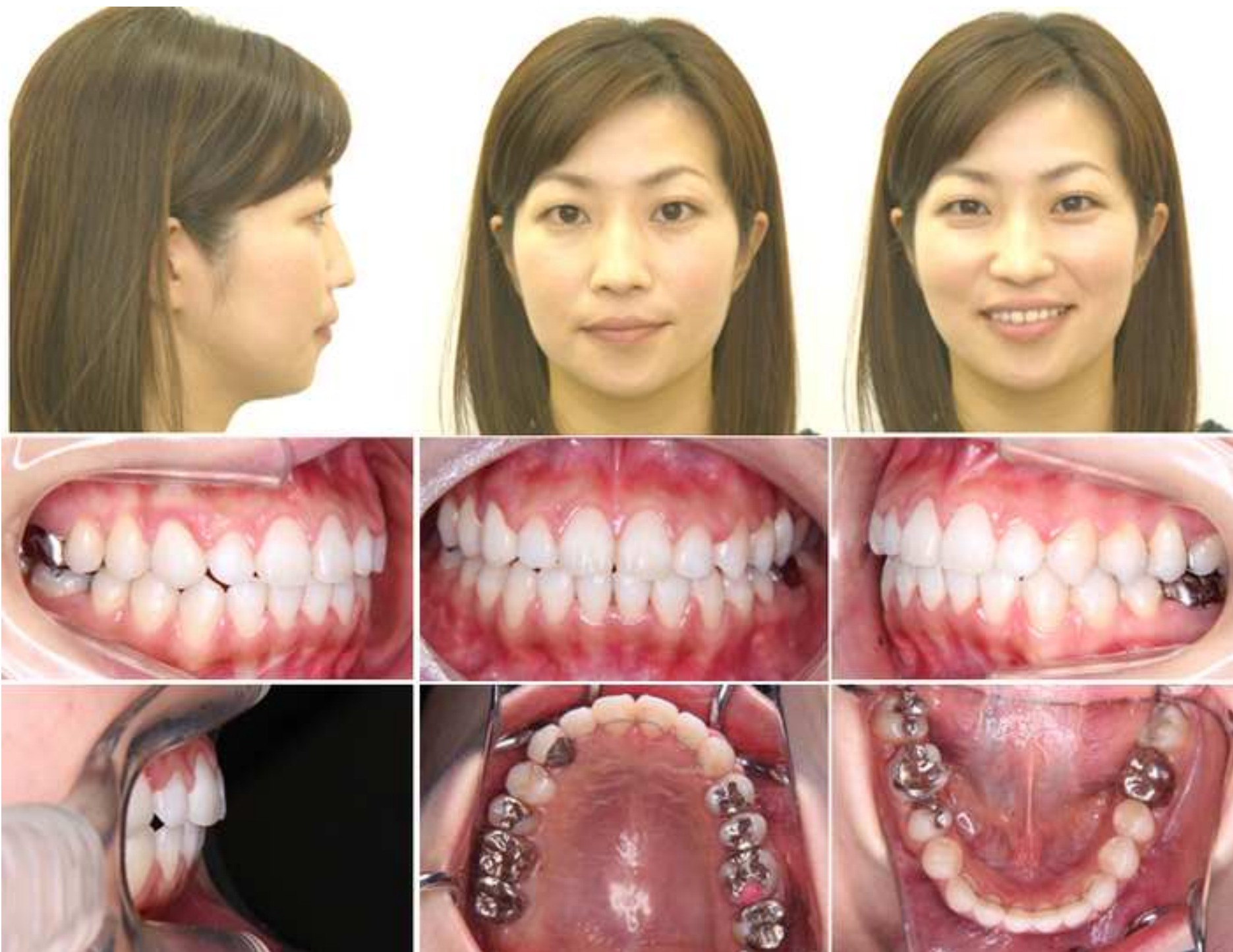


Figure 7
[Click here to download high resolution image](#)

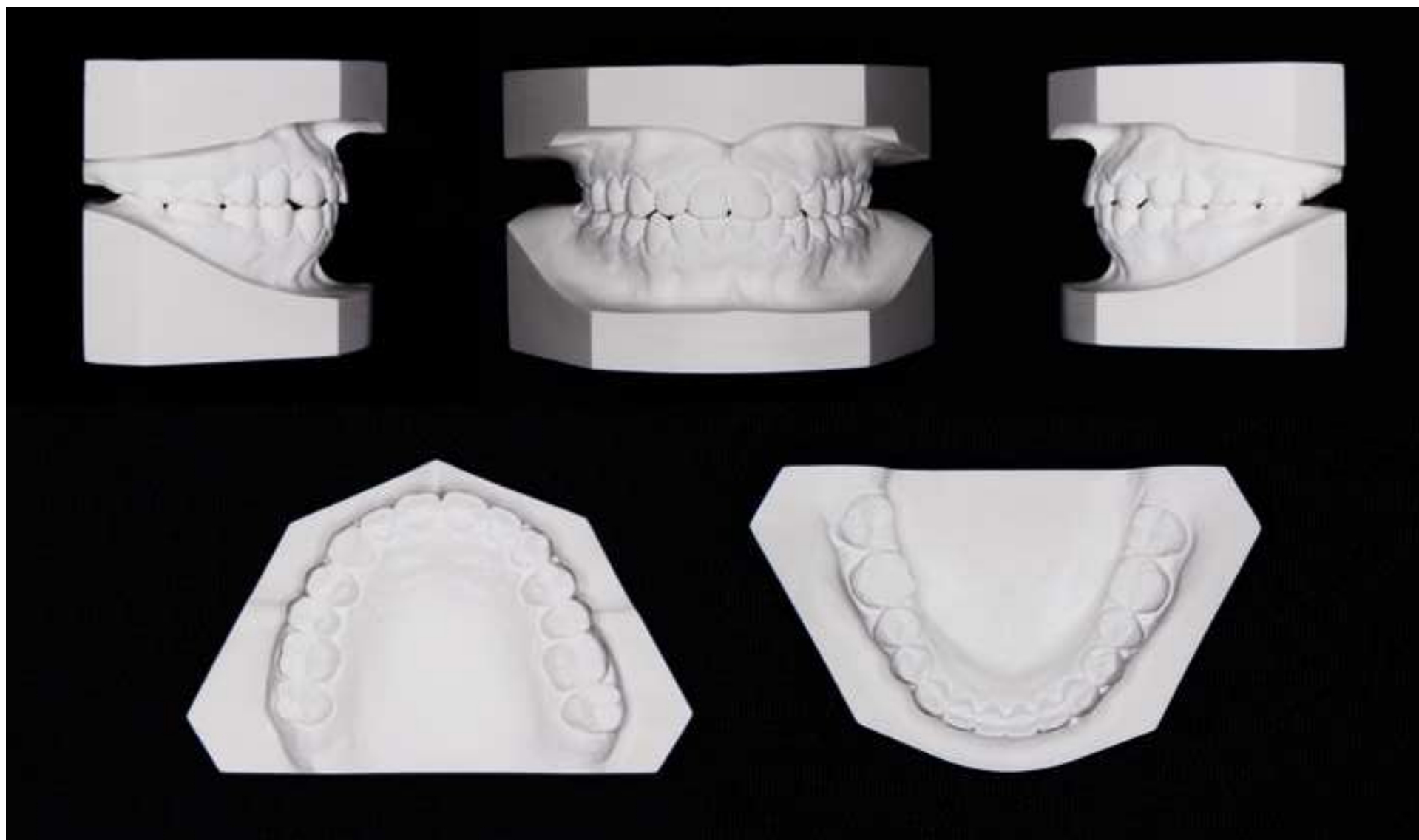


Figure 8
[Click here to download high resolution image](#)

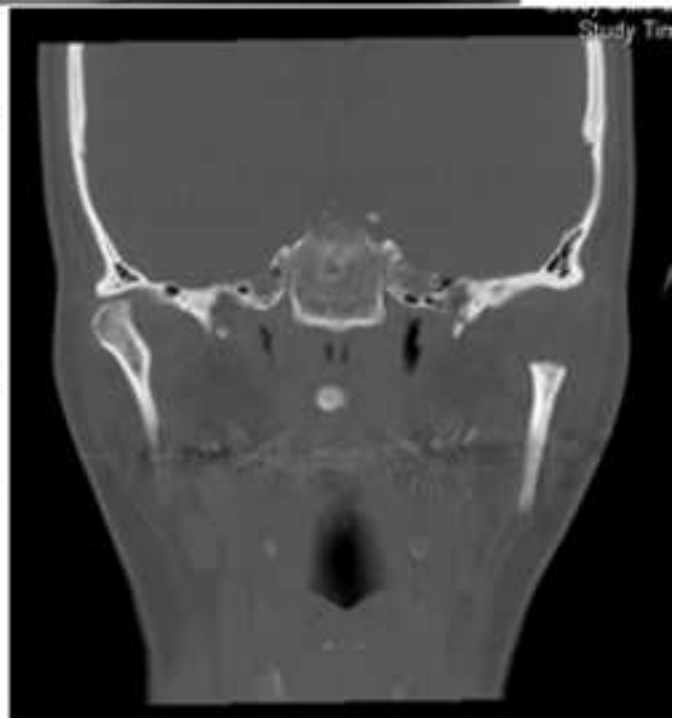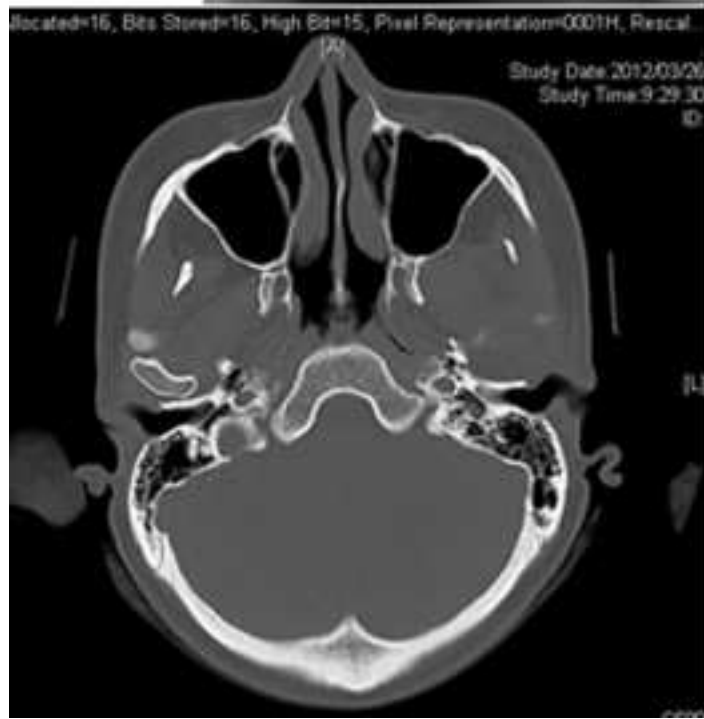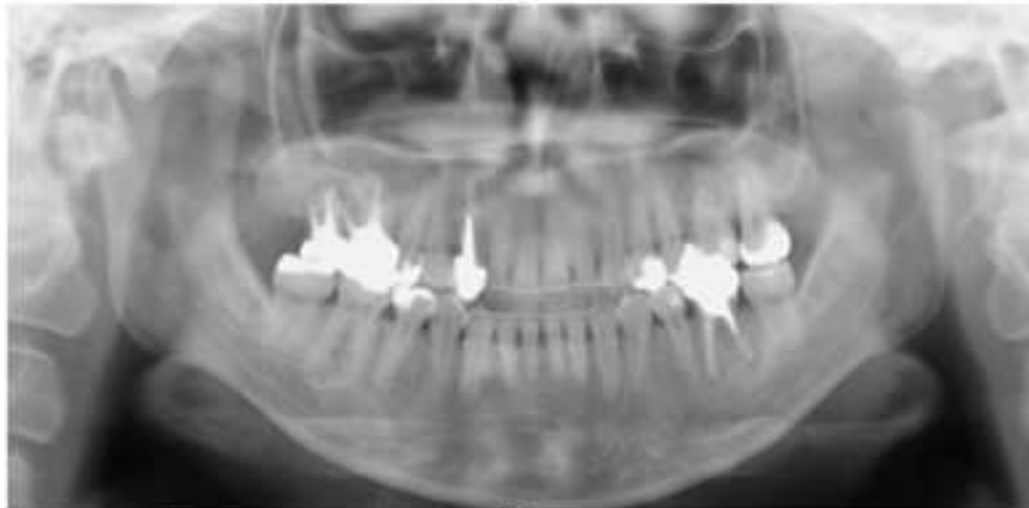
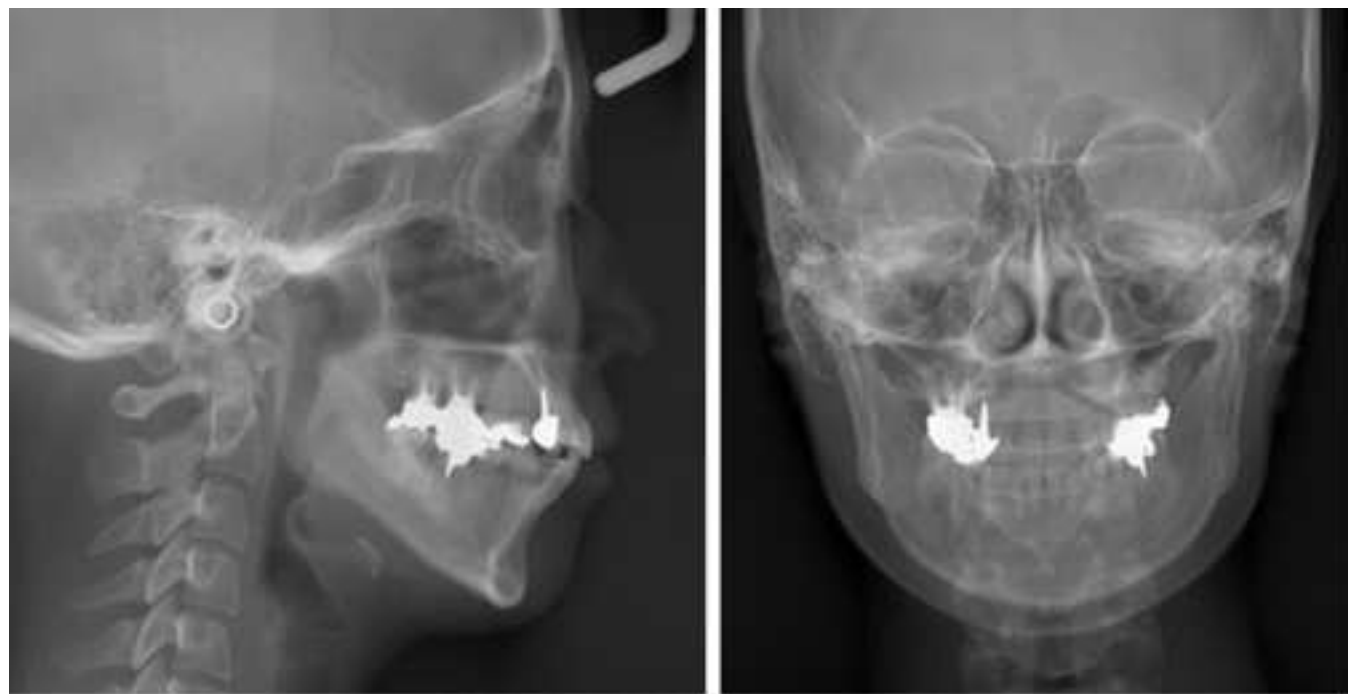


Figure 9
[Click here to download high resolution image](#)

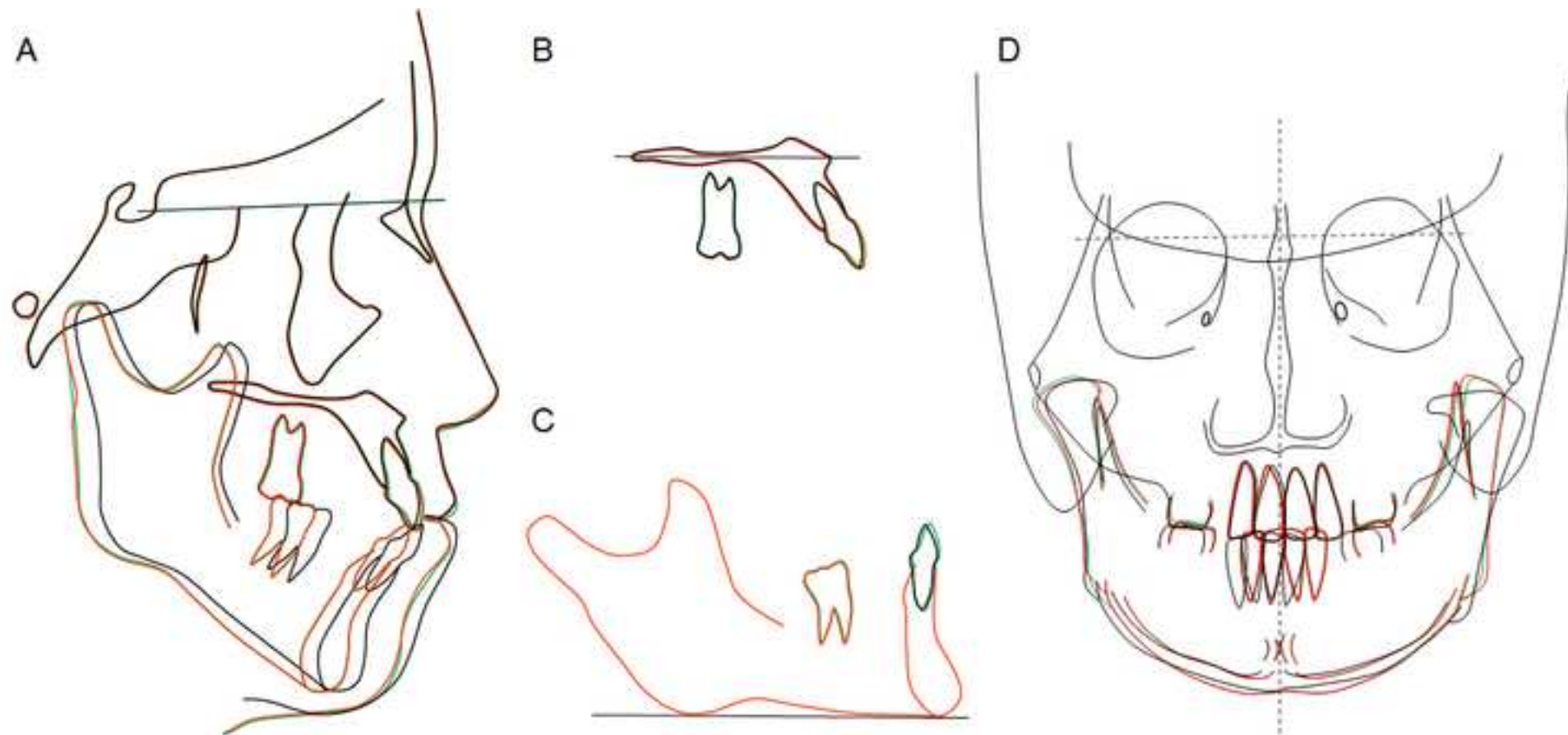


Figure 10
[Click here to download high resolution image](#)

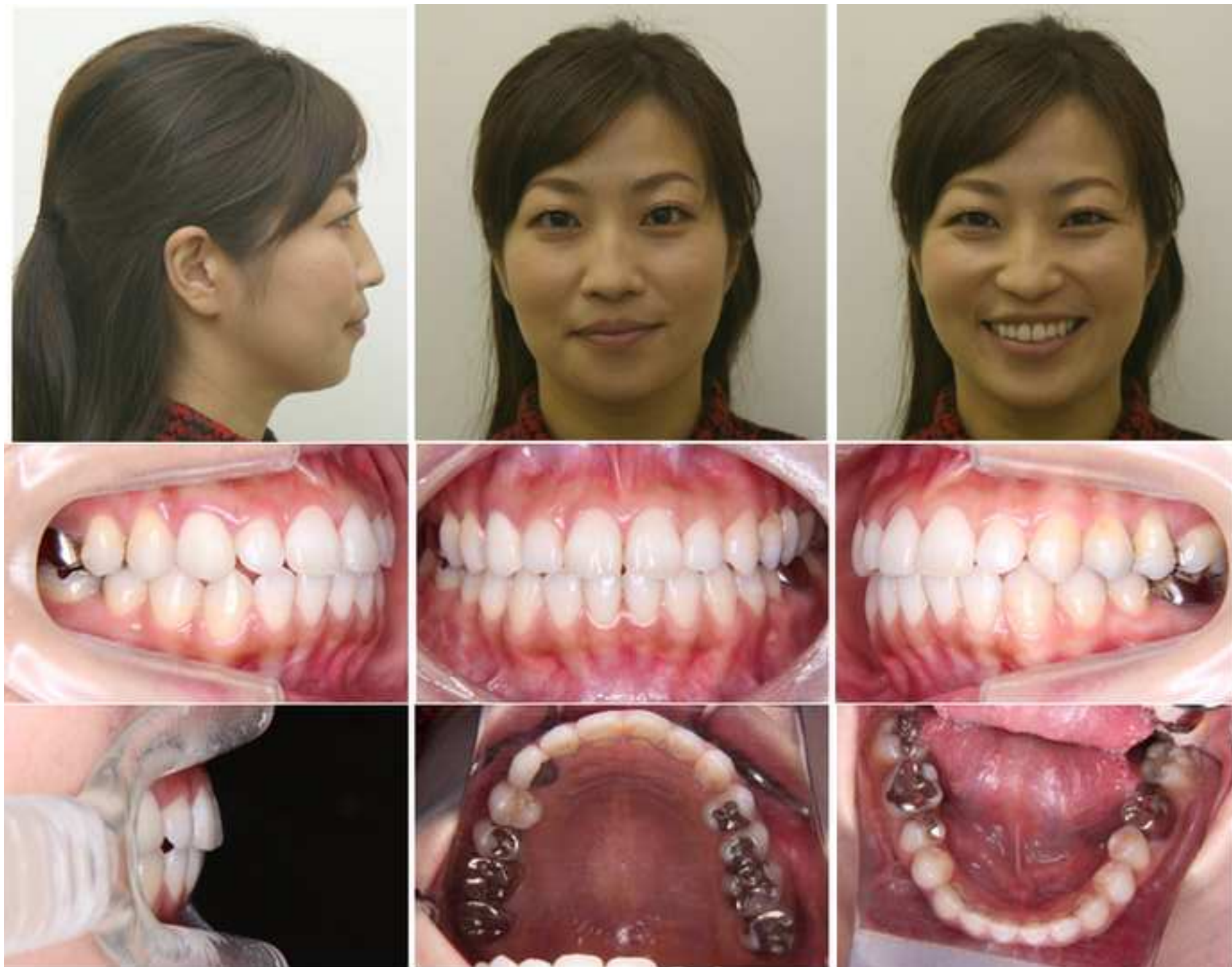

Figure 11
[Click here to download high resolution image](#)

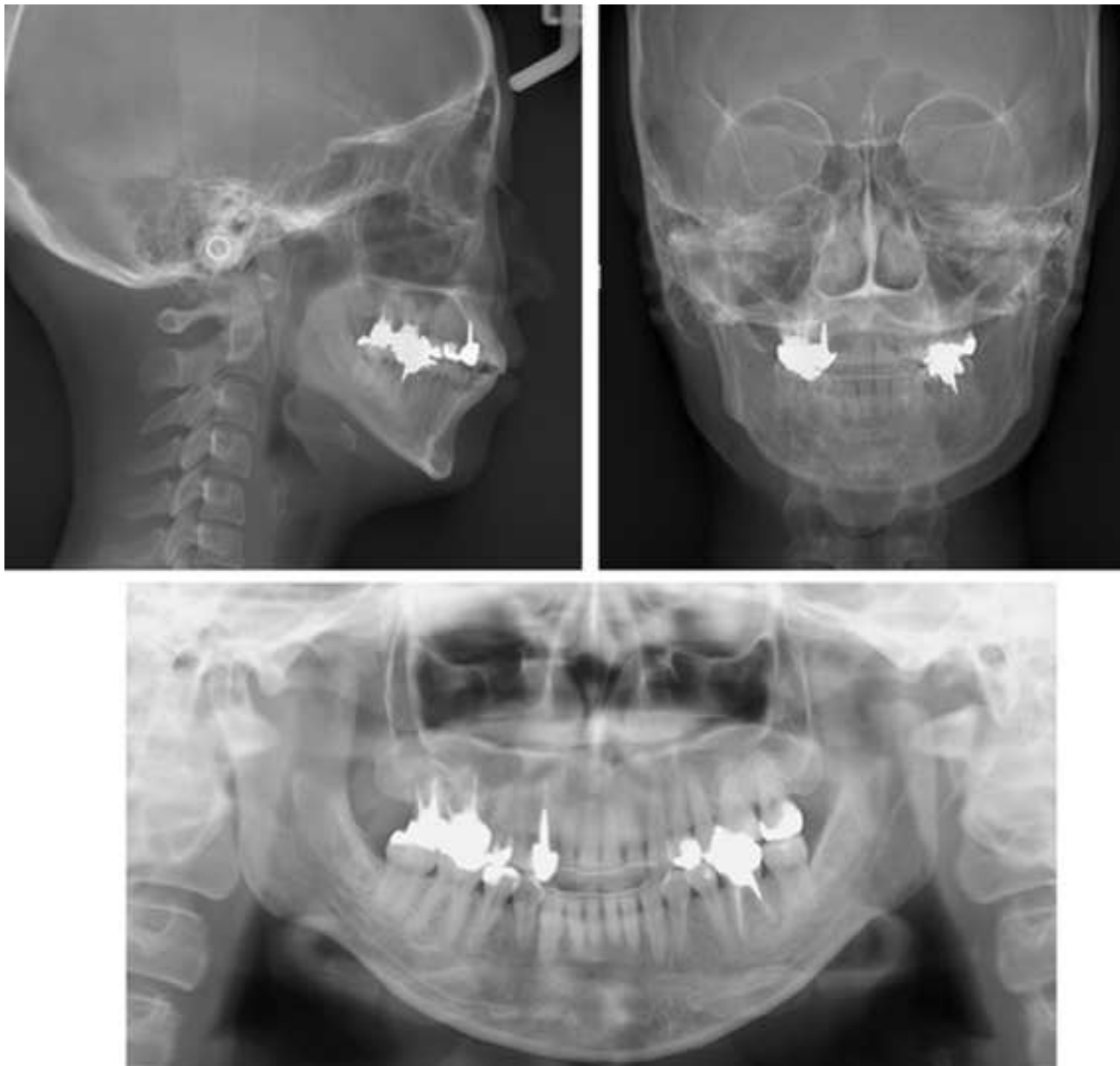


Table. Cephalometric summary

<i>Variable</i>	<i>Japnese norm*</i>	<i>SD</i>	<i>Pretreatment 32y 1m</i>	<i>Posttetreatme nt 35y 4m</i>	<i>Posteretentio n 36y 5m</i>
<i>Angular measurement (°)</i>					
ANB	2.8	2.4	0.2	3.7	3.7
SNA	80.8	3.6	87.1	87	87
SNB	77.9	4.5	86.9	83.3	83.3
Mandibular plane /FH	30.5	3.6	32.6	31.3	31.3
Gonial angle	122.1	5.3	134.3	130.7	129.5
U1-FH	112.3	8.3	110	111.4	111.5
L1-Mandibular plane	93.4	6.8	94.5	98.8	98.6
Interincisal angle	123.6	10.6	123	118.6	118.7
Occlusal plane	16.9	4.4	12.9	13.9	13.9
<i>Linear measurement (mm)</i>					
S-N	67.9	3.7	67.2	67.2	67.2
N-Me	125.8	5	122.9	121.8	121.8
Ar-Go	47.3	3.3	50.2	49.2	49.3
Ar-Me	106.6	5.7	108.4	105.3	105.3
Go-Me	71.4	4.1	66.2	63.2	63
Overjet	3.1	1.1	-0.8	2.2	2.3
Overbite	3.3	1.9	1.5	1.8	2