

ORIGINAL**Usefulness of an ICG fluorescence catheter system in TaTME for avoiding intraoperative urethral injury**

Shogo Ohta, MD, Masaaki Nishi, MD, PhD, FACS, Takuya Tokunaga, MD, PhD, FACS, Kozo Yoshikawa, MD, PhD, FACS, Jun Higashijima, MD, PhD, FACS, Tomohiko Miyatani, MD, PhD, Hideya Kashihara, MD, PhD, FACS, Chie Takasu, MD, PhD, FACS, Daichi Ishikawa, MD, PhD, and Mitsuo Shimada, MD, PhD, FACS

Department of Surgery, The University of Tokushima, 3-18-15 Kuramoto, Tokushima 770-8503, Japan

Abstract : Background. Sometimes intraoperative urethral injury occurs in Transanal total mesorectal excision (TaTME). The aim of this study is to investigate the usefulness of indocyanine green (ICG) fluorescent catheter system for avoiding intraoperative urethral injury in TaTME in experimental model. **Methods.** A urethral catheter was filled with the mixture of albumin and ICG and raw hams were applied in layers as the surrogate model of rectourethral muscle. The detectability of ICG fluorescence in this catheter was investigated by using laparoscope-type fluorescence camera system. **Results.** Fluorescence was detected when ICG was mixed with albumin or peripheral blood. ICG fluorescence could be detected within 4 mm depth of layered raw hams as the surrogate model. **Quantitative analysis of the picture detected that ICG fluorescence plateaued in lower concentration than that of serum.** **Conclusion.** ICG fluorescent catheter system may be useful for avoiding intraoperative urethral injury in TaTME. *J. Med. Invest.* 67:285-288, August, 2020

Keywords : TaTME, ICG, fluorescence, urethral injury, rectal cancer

INTRODUCTION

Transanal total mesorectal excision (TaTME) is a new surgical procedure for curative treatment of lower rectal cancer (1). This “down-to-up” procedure is more effective for dissection of the intrapelvic part in cases with obesity, narrow pelvis cavity, and bulky tumor compared with the conventional laparoscopic transabdominal approach (2). According to a systematic review, TaTME enables dissection of the rectal wall with adequate circumferential resection margin (CRM) and distal margin (3).

TaTME requires a transanal incision between the external and internal sphincter muscles and dissection of the smooth muscle layer. During dissection of the anterior rectal wall, the rectourethral muscle is incised. However, there is no obvious anatomical landmark, and the anterior rectal wall is close to the urethra (4). Intraoperative urethral injury was reported to occur in 2%-6% of cases (5-7). If the urethral wall can be detected more easily, the surgery could become safer. Anatomical navigation of the urethra is necessary to avoid intraoperative urethral injury.

Indocyanine green (ICG) fluorescence is used for anatomical navigation in several procedures, including mastectomy (8), coronary bypass graft (9), and hepatectomy (10). Dapris *et al.* (11) reported that ICG direct injection and fluorescence were useful for understanding the tumor dissection layer in TaTME. However, there are no reports on the usefulness of ICG fluorescence as a navigational tool to avoid intraoperative urethral injury. ICG fluorescence may contribute to easier location of the urethra. The aim of this study was to investigate the usefulness of an ICG fluorescence catheter system for avoiding intraoperative urethral injury in TaTME using an experimental model.

MATERIALS AND METHODS*Validation of materials with detectable fluorescence*

ICG fluorescence detectability in materials was investigated in a preliminary experiment. ICG (Daiichi-Sankyo, Japan) was prepared by dissolution in distilled water to a concentration of 2.5 mg/mL. Fluorescence of ICG in a 25% solution of human serum albumin (Nihon Pharmaceutical, Japan), peripheral human blood, urine from a healthy volunteer, or catheter jelly (Aspen, Japan) was evaluated using an Image 1 SPIES fluorescence camera system (Karl-Storz, Germany) at a distance of 4 cm.

Measurement of detectable thickness for ICG fluorescence

The detectability of ICG fluorescence was investigated. ICG (3 mL) was mixed with 25% albumin (7 mL) and placed in a 14 French silicon Foley catheter (Bard, USA). Raw ham layers as a surrogate model for the rectourethral muscle were laid over the Foley catheter. Fluorescence was evaluated using the Image 1 SPIES fluorescence camera system at a distance of 4 cm and an angle of 45° (Figure 1).

Correlation between albumin concentration and fluorescence intensity

Fluorescence of ICG in 25% albumin repeatedly diluted by two-fold was observed using the Image 1 SPIES fluorescence camera system as described above. Images of individual samples were taken by capturing a movie for analysis of fluorescence intensity. Fluorescence intensity in the captured images was plotted using Image J version 1.51j8 software (NIH, USA) as described previously (12).

Abbreviations

ICG : indocyanine green

TaTME : transanal total mesorectal excision

CRM : circumferential resection margin

MRI : magnetic resonance imaging

Received for publication March 9, 2020 ; accepted May 29, 2020.

Address correspondence and reprint requests to Masaaki Nishi, MD, PhD, FACS, Assistant Professor, Department of Surgery, The University of Tokushima Graduate School, 3-18-15 Kuramoto, Tokushima 770-8503, Japan and Fax : +81-88-631-9698.

Fluorescence evaluation

All fluorescence was evaluated in terms of fluorescence detection (yes/no) and fluorescence intensity (strong/weak) five times by three expert surgeons.

Statistical analysis

Statistical analyses were performed using SPSS statistics version 24 software (IBM, USA). All data were analyzed by the chi-square test. Values of $p < 0.05$ were considered to indicate significant differences.

RESULTS

ICG mixed with albumin or peripheral blood generates strong fluorescence

Fluorescence of ICG was investigated in mixtures with different materials. Four materials, peripheral blood, human serum albumin, human urine, and catheter jelly, were compared on the assumption that these materials are in clinical use during surgery. As a result, ICG fluorescence was detected in albumin or peripheral blood (fluorescence : yes 3/no 0 ; intensity : strong 3/weak 0). Fluorescence was not detected in urine and weakly detected in catheter jelly (Figure 2).

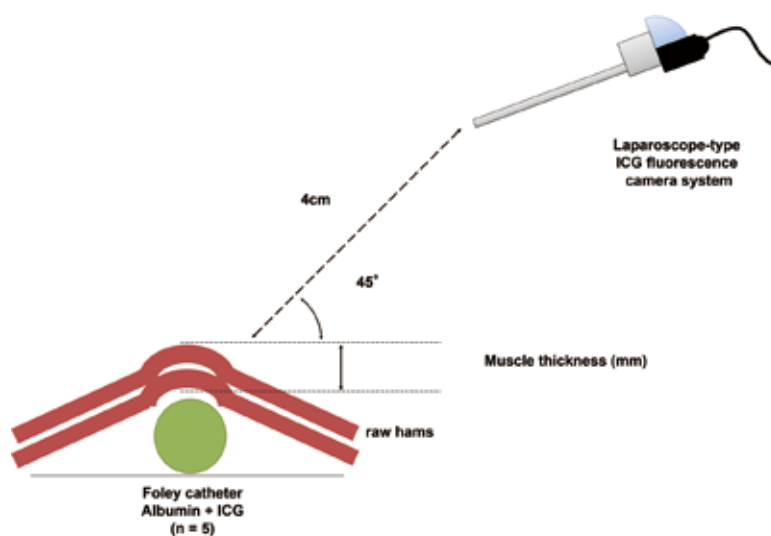


Figure 1. Experimental design of the surrogate model used in the study of detectable depth of ICG fluorescence.

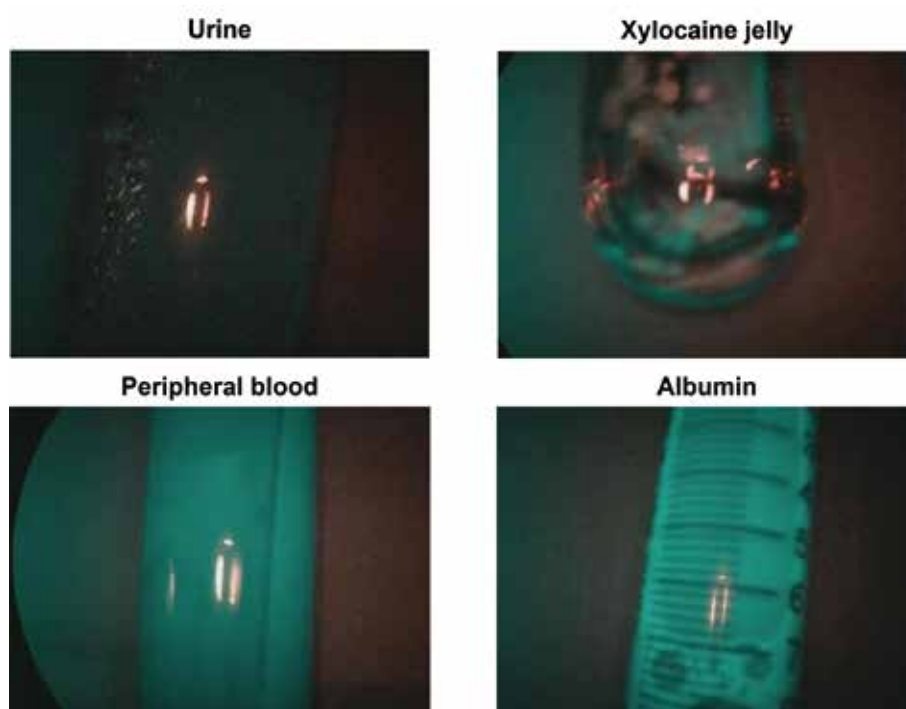


Figure 2. Fluorescence of mixtures of ICG and four materials, namely urine, peripheral blood, catheter jelly, and human serum albumin. Fluorescence of ICG was detected in mixtures with peripheral blood or albumin.

ICG fluorescence can be detected up to 4-mm depth in muscle

The maximum depth in muscles for detection of ICG fluorescence was measured as the detectability. For this experiment, the surrogate model was used (Figure 1). As the thickness of the raw ham layers increased, the fluorescence detection became weaker. At 4-mm thickness, the fluorescence was weak but was still detected (fluorescence : yes 3/no 0 ; intensity : strong 0/weak 3). Fluorescence was not observed at 5-mm thickness (Figure 3).

Low concentration of albumin can generate fluorescence with ICG

In clinical use, ICG is retrogradely injected and diluted by mixing with urine. The ICG solution was diluted and validated for detection of adequate fluorescence. As the albumin preparation concentration decreased, the detected fluorescence became weaker. The ICG fluorescence intensity plateaued at 0.78% albumin (1 : 2⁵ dilution) (Figure 4).

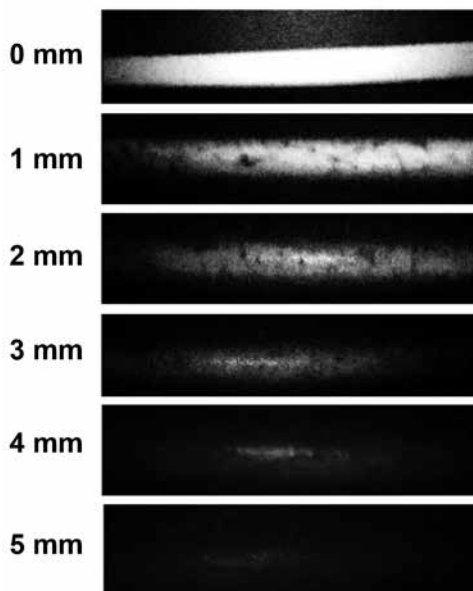


Figure 3. ICG fluorescence was detected up to 4-mm depth, but not at 5-mm depth, in raw ham layers. Images of ICG fluorescence in a mixture with albumin at depths of 0-5 mm in raw ham layers.

DISCUSSION

The results of the present study suggest that the ICG fluorescence catheter system may enable clinicians to become aware of whether or not the dissection line is close to the urethral wall.

In the conventional laparoscopic procedure, it is difficult to perform the resection with an adequate operative field in cases with obesity, narrow pelvis, or bulky tumor. As a result, positive CRM cases occur at 10%-16% (13, 14). Inadequate surgical CRM and distal margin bring about earlier recurrence (15). As an alternative, TaTME was reported to have shorter operation time, fewer postoperative complications, lower conversion rate, and more adequate resection margin, including CRM and distal margin, compared with the laparoscopic procedure in terms of short-term outcomes in systematic reviews (2, 3).

In TaTME, urethral injury was reported to occur in 2%-6% of cases (5-7). To avoid urethral injury, strategies involving accurate anatomical navigation have been investigated. Atallah *et al.* (16) suggested real-time navigation by preoperative pelvic magnetic resonance imaging (MRI). However, this was not true real-time navigation, and the deviation was ± 3.69 mm in fiducial placement. In our experiment, the ICG catheter system could be used for real-time navigation with detectability up to 4-mm depth, and may be superior to MRI navigation.

ICG excites green fluorescence from near-infrared light of wavelength > 790 nm. After injection into a peripheral vein, almost 95% of ICG molecules bind to serum albumin (17). Because the urine of healthy people does not contain albumin, it is necessary to perform retrograde intraurethral injection of an ICG-albumin mixture to detect urethral fluorescence. The ICG fluorescence catheter system is a simple and non-invasive technique, and may become a useful and safe option. A recent cadaveric study confirmed that retrograde direct intraurethral ICG injection is useful for detection of the urethra (18). The present report supports the notion that retrograde intraurethral ICG injection enables detection of the urethra.

The present results confirm that a low concentration of albumin can allow adequate detection of ICG fluorescence through a silicon catheter. In other words, adequate fluorescence can even be observed when the ICG-albumin mixture is mixed with urine and diluted. Our experiments proved that adequate fluorescence was detected after retrograde intraurethral injection with a catheter system. However, the study did not contain *in vivo* investigations such as animal models and clinical studies.

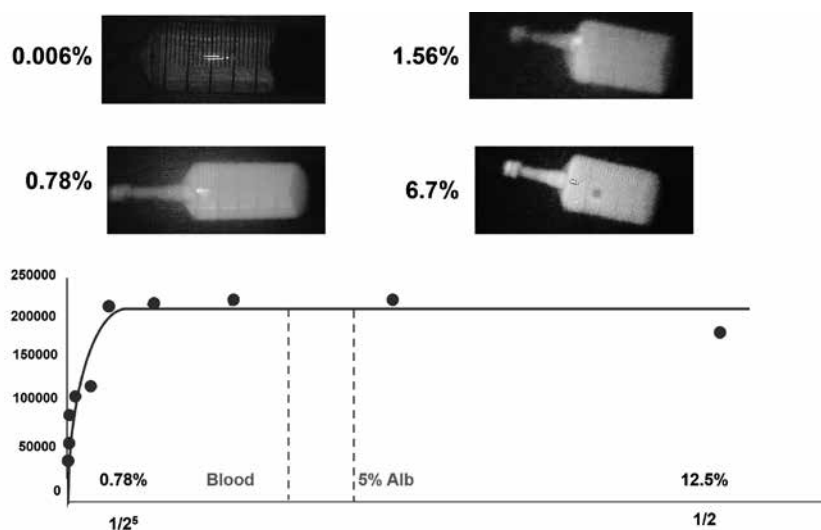


Figure 4. Validation of ICG fluorescence. ICG fluorescence plateaued in 0.78% human albumin.

To further clarify the feasibility and usefulness of the ICG fluorescence catheter system, we plan to perform an *in vivo* study or clinical trial.

In conclusion, we have provided evidence that the ICG fluorescence catheter system may be useful for avoiding intraoperative urethral injury in TaTME. If the urethra can be detected more easily in the operative view, TaTME may become a safer treatment procedure for mid and low rectal cancer.

AUTHOR CONTRIBUTIONS STATEMENT

S. O. conducted and performed the experiments, analyzed data, and wrote the manuscript ; D. I., T. T., and M. N. conducted and supported the experiments ; K. Y., J. H., T. M., H. K., C. T., and D. I. evaluated the detectability of ICG fluorescence ; S. O. and D. I. analyzed the quality and intensity of ICG fluorescence and edited the manuscript ; M. S. and M. N. checked the experiments and edited the manuscript. All authors reviewed the manuscript.

FINANCIAL SUPPORT

This study did not receive any financial support.

CONFLICTS OF INTEREST

The authors declare no competing interests.

ACKNOWLEDGMENTS

The authors thank Alison Sherwin, PhD, from Edanz Group (www.edanzediting.com/ac) for editing a draft of this manuscript.

REFERENCES

- deLacy AM, Rattner DW, Adelsdorfer C, Tasende MM, Fernandes M, Delgado S, Sylla P, Martines-Palli G : Transanal natural orifice transluminal endoscopic surgery (NOTES) rectal resection : "down-to-up" total mesorectal excision (TME)---short-term outcomes in the first 20 cases. *Surg Endosc* 27 : 3165-3172, 2013
- Araujo SE, Crawshaw B, Mendes CR, Delaney CP : Transanal total mesorectal excision : a systematic review of the experimental and clinical evidence. *Tech Coloproctol* 19 : 69-82, 2014
- Xu W, Xu Z, Cheng H, Ying J, Cheng F, Xu W, Cao J, Luo J : Comparison of short-term clinical outcomes between transanal and laparoscopic total mesorectal excision for the treatment of mid and low rectal cancer : A meta-analysis. *Eur J Surg Oncol* 42 : 1841-1850, 2016
- Nakajima Y, Muro S, Nasu H, Harada M, Yamaguchi K, Akita K : Morphology of the region anterior to the anal canal in males : visualization of the anterior bundle of the longitudinal muscle by transanal ultrasonography. *Surg Radiol Anat* 39 : 967-973, 2017
- Atallah S : Transanal total mesorectal excision : full steam ahead. *Tech Coloproctol* 19 : 57-61, 2015
- Kang L, Chen WH, Luo SL, Luo YX, Liu ZH, Huang MJ, Wang JP : Transanal total mesorectal excision for rectal cancer : a preliminary report. *Surg Endosc* 30 : 2552-2562, 2016
- Rouanet P, Mourregot A, Azar CC, Carrere S, Gutowski M, Quenet F, Saint-Aubert B, Colombo PE : Transanal Endoscopic Proctectomy : An Innovative Procedure for Difficult Resection of Rectal Tumors in Men With Narrow Pelvis. *Dis Colon Rectum* 56 : 408-415, 2013
- Troyan SL, Kianzad V, Gibbs-Strauss SL, Gioux S, Matsui A, Oketokoun R, Ngo L, Khamene A, Azar F, Frangioni JV : The FLARE™ Intraoperative Near-Infrared Fluorescence Imaging System : A First-in-Human Clinical Trial in Breast Cancer Sentinel Lymph Node Mapping. *Ann Surg Oncol* 16 : 2943-2952, 2009
- Marshall MV, Rasmussen JC, Tan IC, Aldrich MB, Adams KE, Wang X, Fife CE, Maus EA, Smith LA, Sevic-Muraca EM : Near-Infrared Fluorescence Imaging in Humans with Indocyanine Green : A Review and Update. *Open Surg Oncol J* 2 : 12-25, 2010
- Mery E, Golzio M, Guillermet S, Lanore D, Le Naour A, Thibault B, Tilkin-Mariame AF, Bellard E, Delord JP, Querleu D, Ferron G, Couderc B : Fluorescence-guided surgery for cancer patients : a proof of concept study on human xenografts in mice and spontaneous tumors in pets. *Oncotarget* 8 : 109559-109574, 2017
- Dapri G, Cahill R, Bourgeois P, Liberale G, Galdon Gomez M, Cadiere GB : Peritumoural injection of indocyanine green fluorescence during transanal total mesorectal excision to identify the plane of dissection - a video vignette. *Colorectal Dis* 19 : 589-600, 2017
- Schneider CA, Rasband WS, Eliceiri KW : NIH Image to Image J : 25 years of Image Analysis. *Nat Methods* 9 : 671-675, 2012
- Chen CC, Lai YL, Jiang JK, Chu CH, Huang IP, Chen WS, Cheng AY, Yang SH : Transanal total mesorectal excision versus laparoscopic surgery for rectal cancer receiving neoadjuvant chemoradiation : a matched case-control study. *Ann Surg Oncol* 23 : 1169-76, 2016
- Perdawood SK, Al Khefagie GA : Transanal vs laparoscopic total mesorectal excision for rectal cancer : initial experience from Denmark. *Colorectal Dis* 18 : 51-8, 2016
- West NP, Finan PJ, Anderin C, Lindholm J, Holm T, Quirke P : Evidence of the oncologic superiority of cylindrical abdominoperineal excision for low rectal cancer. *J Clin Oncol* 26 : 3517-3522, 2008
- Atallah S, Martin-Perez B, Larach S : Image-guided real-time navigation for transanal total mesorectal excision : a pilot study. *Tech Coloproctol* 19 : 679-84, 2015
- Cherrick GR, Stein SW, Leevy CM, Davidson CS : Indocyanine Green : Observations on its Physical Properties, Plasma Decay, and Hepatic Extraction. *J Clin Invest* 39 : 592-600, 1960
- Barnes TG, Penna M, Hompes R, Cunningham C : Fluorescence to highlight the urethra : a human cadaveric study. *Tech Coloproctol* 21 : 439-444, 2017