

CLINICAL IMAGE

A Case of Uterine Tumor Resembling Ovarian Sex-cord Tumor (UTROSCT) Exhibiting Similar Imaging Characteristics to Those of Ovarian Sex-cord Tumor

Mayumi Takeuchi¹, Kenji Matsuzaki², Yoshimi Bando³, Masato Nishimura⁴,
Aki Hayashi⁴, and Masafumi Harada¹

Keywords: *granulosa cell tumor, magnetic resonance imaging, ovary, sex-cord tumor, uterine tumor resembling ovarian sex-cord tumor*

A 48-year-old woman with progressive lower abdominal fullness was referred to our hospital. MR images were obtained by using a 3-Tesla superconducting unit (Discovery MR750, GE Healthcare, Waukesha, WI, USA) with 32 channel body-array torso coils. A huge solid pelvic mass measuring 20 cm in diameter arising from uterine cervix showed sponge-like appearance containing numerous variable cysts with/without intra-cystic hemorrhage on T₂-weighted images mimicking ovarian sex-cord tumors such as granulosa cell tumor (Fig. 1a and 1b). Prominent flow voids of dilated uterine arteries suggesting hypervascularity of the tumor were also demonstrated on T₂-weighted images (Fig. 1a). The solid portion of the mass showed high signal intensity on diffusion-weighted imaging (Fig. 1c) with low apparent diffusion coefficient, and intense contrast-enhancement on post-contrast T₁-weighted images (Fig. 1d). Susceptibility-weighted MR sequence (T₂ star-weighted angiography [SWAN]) revealed intra-tumoral hemorrhagic foci as signal voids. Chest-abdominal computed tomography revealed ascites, intra-peritoneal disseminations and multiple lymphadenopathies (parasternal and right pericardial). Uterine sarcoma was suspected based on the MR imaging findings and abdominal total hysterectomy with bilateral salpingo-oophorectomy was performed. Histological

examination of the mass revealed uterine tumor resembling ovarian sex-cord tumor (UTROSCT).

Uterine tumor resembling ovarian sex-cord tumors are rare uterine tumors, and recently World Health Organization (WHO) defined as neoplasms that resemble ovarian sex-cord tumors (such as granulosa cell tumor) without a component of recognizable endometrial stroma (former type II UTROSCT).^{1,2} The origin of UTROSCT remains uncertain, and the absence of *JAZF1-SUZ12* gene fusion suggests different origin from the endometrial stroma.² UTROSCT affects middle-aged women, and usually has a benign clinical course but may cause metastasis and/or recurrence. Most patients may present with abnormal genital bleeding, abdominal pain, and/or uterine enlargement. The tumors are often polypoid and submucosal, however, may be intramural, subserosal, or cervical. They are typically well circumscribed solid tumors but may contain hemorrhagic cyst in rather large tumors.¹ The average diameter is 6–7 cm. However, some case reports with imaging findings have been published, MR imaging characteristics of UTROSCT have not been reported in the literature.

In the current case, the tumor showed sponge-like appearance with multiple cystic areas throughout the tumor, which may be rarely seen in the other uterine tumors. Sponge-like appearance well reflects the pathologic features of ovarian granulosa cell tumor: intra-tumoral cystic spaces lined by granulosa cells and filled with fluid or clotted blood, and is a characteristic MR findings.³ Intra-tumoral hemorrhage is another characteristic findings of granulosa cell tumor.³ These MR findings may also be suggestive for UTROSCT, which histologically resembles granulosa cell tumor, and be helpful for the differential diagnosis.

¹Department of Radiology, Tokushima University, 3-18-15 Kuramoto-cho, Tokushima, Tokushima 770-8503, Japan

²Department of Radiological Technology, Tokushima Bunri University, Kagawa, Japan

³Division of Pathology, Tokushima University Hospital, Tokushima, Japan

⁴Department of Obstetrics and Gynecology, Tokushima University, Tokushima, Japan

*Corresponding author, Phone: +81-88-633-9283, Fax: +81-88-633-7468, E-mail: mayumi@tokushima-u.ac.jp

©2018 Japanese Society for Magnetic Resonance in Medicine

This work is licensed under a Creative Commons Attribution-NonCommercial-NoDerivatives International License.

Received: December 29, 2017 | Accepted: April 4, 2018

Conflicts of Interest

The authors declare that they have no conflicts of interest.

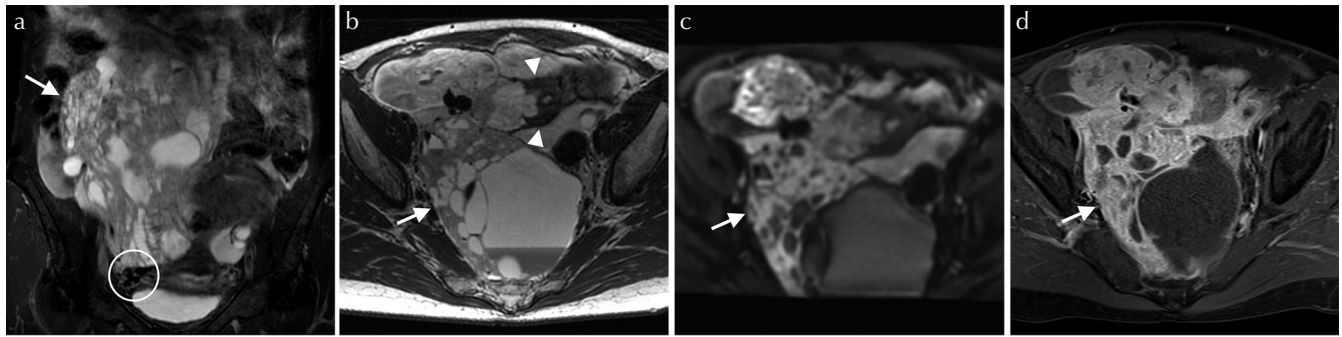


Fig. 1 A huge solid pelvic mass (arrow) arising from uterine cervix with “beak sign” (arrowheads) and prominent uterine arterial supply (circle) exhibiting sponge-like appearance on coronal T₂-weighted image with fat-saturation (TR/TE: 5,000/96 ms) (a), T₂-weighted image (5,000/102 ms) (b), diffusion weighted image (4,000/55 ms, $b = 800 \text{ sec/mm}^2$) (c), and post-contrast T₁-weighted image with fat-saturation (400/15 ms) (d).

References

1. Clement PB, Scully RE. Uterine tumors resembling ovarian sex-cord tumors. A clinicopathologic analysis of fourteen cases. *Am J Clin Pathol* 1976; 66:512–525.
2. Oliva E, Carcangiu MK, Carinelli SG, et al. Mesenchymal tumours. In WHO Classification of Tumours of Female Reproductive Organs, 4th ed. Kurman RJ, Carcangiu ML, Herrington CS, Young RH, Eds. International Agency for Research on Cancer, Lyon, 2014; 135–147.
3. Morikawa K, Hatabu H, Togashi K, Kataoka ML, Mori T, Konishi J. Granulosa cell tumor of the ovary: MR findings. *J Comput Assist Tomogr* 1997; 21:1001–1004.