

Oral granuloma in a pediatric patient with chronic graft-versus-host disease: A case report

Atsushi Uesugi, Fumihiko Tsushima, Makoto Kodama, Takeshi Kuroshima, Jinkyō Sakurai, Hiroyuki Harada

ORCID number: Atsushi Uesugi 0000-0002-0496-8591; Fumihiko Tsushima 0000-0002-1919-746X; Makoto Kodama 0000-0002-4969-8249; Takeshi Kuroshima 0000-0003-0861-9599; Jinkyō Sakurai 0000-0002-0271-8142; Hiroyuki Harada 0000-0002-8078-0195.

Author contributions: Atsushi U, Kuroshima T, and Tsushima F were the patient's oral and maxillofacial surgeons, reviewed the literature, and contributed to manuscript drafting; Sakurai J and Harada H were the patient's oral and maxillofacial surgeons, reviewed the literature, and drafted the manuscript; Kodama M performed pathological analysis, reviewed the literature, and drafted the manuscript. All authors issued final approval for the version to be submitted.

Informed consent statement: The authors got informed consent from the patient's family.

Conflict-of-interest statement: The authors declare that they have no conflict of interest.

CARE Checklist (2016) statement: The authors have read the CARE Checklist (2016) and have prepared and revised the manuscript according to the CARE Checklist (2016).

Atsushi Uesugi, Fumihiko Tsushima, Takeshi Kuroshima, Jinkyō Sakurai, Hiroyuki Harada, Oral and Maxillofacial Surgery, Tokyo Medical and Dental University, Tokyo 113-8549, Japan

Makoto Kodama, Human Pathology, Tokyo Medical and Dental University, Tokyo 113-8510, Japan

Corresponding author: Atsushi Uesugi, DDS, PhD, Medical Assistant, Oral and Maxillofacial Surgery, Tokyo Medical and Dental University, 1-5-45 Yushima, Bunkyo-ku, Tokyo 113-8549, Japan. uesugi.atsushi@tokushima-u.ac.jp

Abstract

BACKGROUND

Oral mucositis is often observed with graft-versus-host disease (GVHD); however, the occurrence of oral granuloma is rare. The rapid increase in granulomatous lesions should be distinguished from malignant tumors in patients with GVHD because malignant diseases can develop in those patients. This case is the youngest pediatric patient with granuloma associated with GVHD.

CASE SUMMARY

The patient was a 1-year and 5-mo-old girl who presented to our department for the management of oral nodules. At the age of 5 mo, she was diagnosed with primary immunodeficiency disease, cord blood transplant was performed at 11 mo and bone marrow transplant at 1 year of age. After transplantation, GVHD and oral mucositis developed, and tacrolimus was administered. Interestingly, nodules appeared on the lower lip and buccal mucosa, which spontaneously disappeared. Then, a new nodule appeared on the left lateral border of the tongue. Resection was performed and the histopathological diagnosis was granuloma. The origin of these nodules were considered to be the fibroblasts activated under inflammation caused by GVHD because the calcineurin inhibitor tacrolimus acted on their proliferation.

CONCLUSION

It is very important to distinguish oral granulomatous lesions from malignancies if GVHD is present at the base and if immunosuppressive agents and steroids are being administered.

Key Words: Oral granuloma; Graft-versus-host disease; Bone marrow transplantation; Primary immunodeficiency disease; Tacrolimus; Case report

Open-Access: This article is an open-access article that was selected by an in-house editor and fully peer-reviewed by external reviewers. It is distributed in accordance with the Creative Commons Attribution NonCommercial (CC BY-NC 4.0) license, which permits others to distribute, remix, adapt, build upon this work non-commercially, and license their derivative works on different terms, provided the original work is properly cited and the use is non-commercial. See: <http://creativecommons.org/licenses/by-nc/4.0/>

Manuscript source: Unsolicited manuscript

Specialty type: Medicine, research and experimental

Country/Territory of origin: Japan

Peer-review report's scientific quality classification

Grade A (Excellent): 0
 Grade B (Very good): 0
 Grade C (Good): 0
 Grade D (Fair): 0
 Grade E (Poor): 0

Received: June 9, 2020

Peer-review started: June 9, 2020

First decision: September 24, 2020

Revised: October 4, 2020

Accepted: October 26, 2020

Article in press: October 26, 2020

Published online: November 26, 2020

P-Reviewer: Gong N

S-Editor: Zhang L

L-Editor: A

P-Editor: Liu JH



©The Author(s) 2020. Published by Baishideng Publishing Group Inc. All rights reserved.

Core Tip: Oral mucositis is often observed with graft-versus-host disease (GVHD); however, the presence of oral granuloma is rare. This case is the youngest pediatric patient with granuloma associated with GVHD. At the age of 5 mo, she was diagnosed with primary immunodeficiency disease. After transplantation, she developed GVHD and oral mucositis. Notably, nodules appeared on the lip and buccal mucosa, which spontaneously disappeared. Then, a new nodule appeared on the tongue. Histopathological diagnosis was granuloma. It is important to distinguish rapidly grown granulomatous nodules from malignant tumors.

Citation: Uesugi A, Tsushima F, Kodama M, Kuroshima T, Sakurai J, Harada H. Oral granuloma in a pediatric patient with chronic graft-versus-host disease: A case report. *World J Clin Cases* 2020; 8(22): 5663-5669

URL: <https://www.wjgnet.com/2307-8960/full/v8/i22/5663.htm>

DOI: <https://dx.doi.org/10.12998/wjcc.v8.i22.5663>

INTRODUCTION

Although hematopoietic stem cell transplantation can be used to treat and prevent complications caused by primary immunodeficiency disease (PID), graft-versus-host disease (GVHD) can complicate recovery. Oral lesions are frequently observed in association with GVHD, typical findings include lichen planus-like mucosal changes, damage to the salivary glands, and trismus due to sclerosis. However, the occurrence of oral granuloma with GVHD is rare. Here, we report the case of a pediatric patient who developed GVHD after bone marrow transplantation (BMT) for PID and subsequently developed granuloma in the oral mucosa.

CASE PRESENTATION

Chief complaints

A 1-year and 5-month-old girl presented to our department for the management of oral nodules.

History of present illness

At 5 mo of age, the patient was diagnosed with PID upon sustaining a severe respiratory syncytial virus infection. At 11 mo of age, she received umbilical cord blood transplant but developed hemophagocytic syndrome, and the transplant failed to engraft. At 1 year of age, BMT was performed using the bone marrow from her HLA semi-matched father. In preparation for receiving BMT, she received fludarabine ($\times 3$ d), melphalan ($\times 1$ d), anti-thymocyte globulin ($\times 2$ d), and etoposide ($\times 2$ d beginning at 3 d prior to the scheduled procedure). In an effort to prevent GVHD, tacrolimus (FK506) was administered at 1 d prior to the procedure followed by methylprednisolone for 1 d and methotrexate for 4 d (on days 1, 3, 6, and 11) after BMT. Nonetheless, acute GVHD with oral mucositis developed on day 21; she was treated with additional FK506 and prednisolone. At 44 d after BMT, GVHD and oral mucositis had resolved somewhat. However, at day 64, a nodule transiently appeared in the lower lip mucosa; another nodule appeared in the buccal mucosa. The patient at 1 year and 5 mo of age was referred to our department for ongoing care.

Physical examination

On presentation, the patient had bleeding oral mucositis in the lip and buccal regions. There were no findings suggestive of lichen planus. Pedunculated nodules 8 mm \times 5 mm in size and 2 mm \times 2 mm in size were identified in the lower lip mucosa. The left buccal mucosa was grayish-white in color, with several easily bleeding nodules (Figure 1). The platelet count on this first visit was below the normal limits at 5×10^4 / μ L. However, 1 mo after the first visit, all lesions spontaneously reduced (Figure 2). After 1 mo, GVHD recurred with oral mucositis. Her condition improved in response

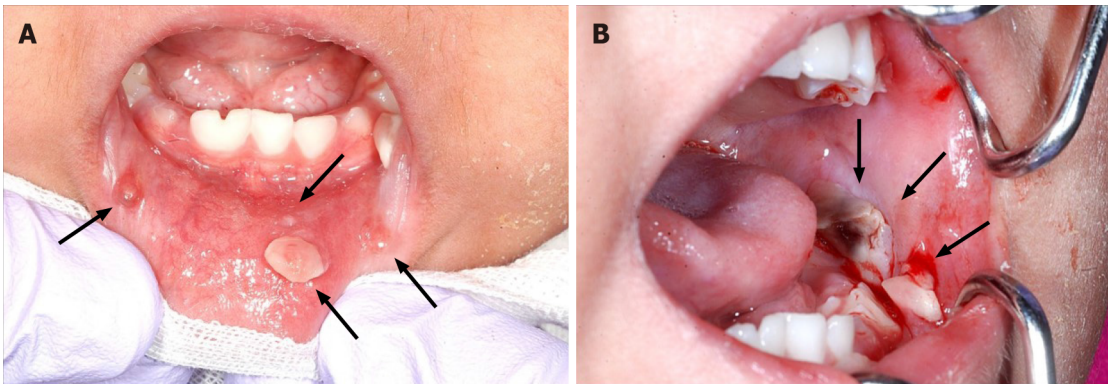


Figure 1 Oral mucositis of the lip and buccal region. There were no findings suggesting lichen planus. A: A pedunculated nodule 8 mm × 5 mm in size and a sessile nodule 2 mm × 2 mm in size in the lower lip mucosa (arrow); B: The left buccal mucosa was grayish-white with a bleeding nodule (arrow).

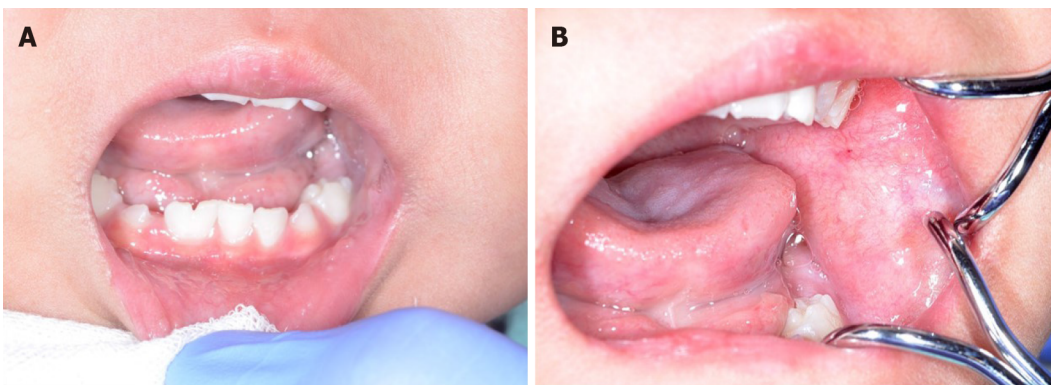


Figure 2 One month after the first visit, all lesions spontaneously reduced. A and B: Oral nodules in the lower lip mucosa had disappeared 1 mo after the first visit.

to elevated doses of both FK506 and prednisolone; however, GVHD-related gastrointestinal symptoms, mainly diarrhea and bloody stool, still persisted. Approximately 1 mo later, a nodule was detected on the left border of her tongue. Upon return to our department, an elastic soft, pedunculated nodule 12 mm × 10 mm in size was found on the left tongue border; this was diagnosed as a benign tumor (Figure 3). As her platelet count had sufficiently recovered (to $18.5 \times 10^4/\mu\text{L}$), the nodule was resected under general anesthesia. The procedure included 3-mm margins and excision into the muscle layer.

Pathological examination

The tumor pathology was notable for granulation tissue consisting of capillaries and fibroblasts accompanied by moderate infiltration with inflammatory cells, including neutrophils. No malignancy was reported nor were there any inclusion bodies suggestive of cytomegalovirus (CMV) infection (Figure 4). A deoxyribonucleic acid test to detect CMV was performed on the excised tissue, but the results were negative.

FINAL DIAGNOSIS

The final diagnosis of the presented case was granuloma of the tongue caused by calcineurin inhibitor used for the treatment of oral GVHD.

TREATMENT

After the excision, follow-up was performed without additional treatment.

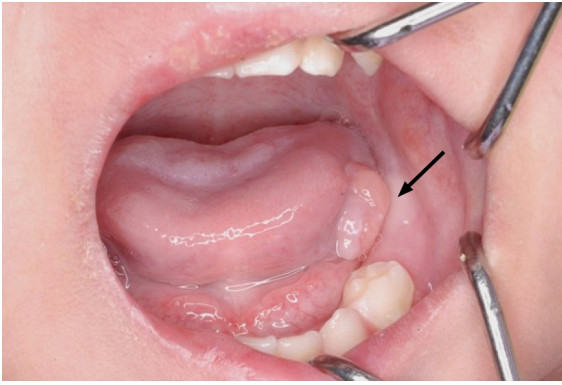


Figure 3 An elastic, soft, pedunculated nodule 12 mm in diameter was detected on the left tongue margin (arrow).

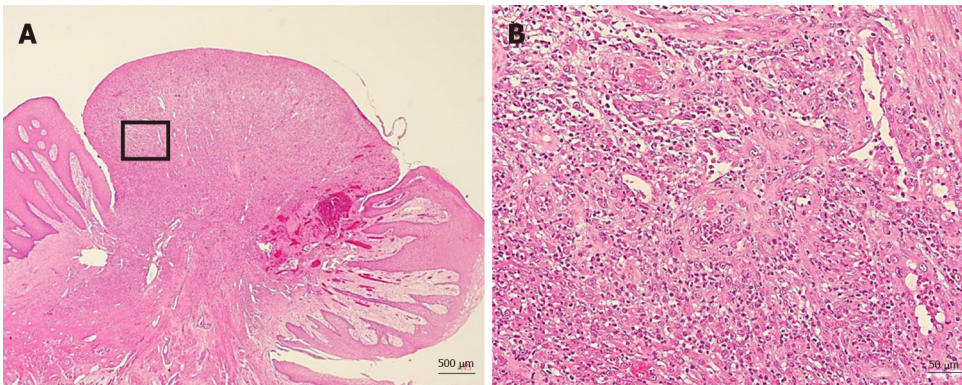


Figure 4 No malignancy was reported nor were there any inclusion bodies suggestive of cytomegalovirus infection. A: Histological examination of the excised tongue nodule showing granulation tissue with capillaries and fibroblasts (Hematoxylin-eosin stain $\times 20$, bar = 500 μm); B: Moderate infiltration with inflammatory cells, notably neutrophils. There was no malignancy or inclusion bodies suggestive of cytomegalovirus infection (Hematoxylin-eosin, $\times 200$, bar = 50 μm).

OUTCOME AND FOLLOW-UP

There was no recurrence of the lesion up to 1 year and 5 mo after the excision (Figure 5). However, the patient subsequently died due to an infection associated with PID.

DISCUSSION

GVHD associated with hematopoietic stem cell transplantation can be classified as acute or chronic. In this patient, GVHD developed 21 d after BMT and as such was diagnosed as acute GVHD. After several rounds of gastrointestinal symptoms, the diagnosis transitioned to chronic GVHD.

Typical oral lesions associated with GVHD include mucosal lichenoid changes, damage to the salivary glands, and trismus secondary to sclerosis^[1]. In this patient, oral mucositis mainly comprised granulomatous nodules.

Woo *et al*^[2] reported on non-gingival soft tissue granulomatous lesions in patients who developed GVHD after BMT. The features are as follows: (1) A non-gingival soft tissue nodule that exhibits rapid growth, raising malignancy concerns; (2) The presence of a certain degree of oral chronic GVHD in the tissues around the nodule; and (3) The presence of a certain degree of systemic GVHD, for which the patient was being treated with cyclosporin A (CsA)^[2].

Among the explanations for these observations, when oral mucositis is caused by GVHD, the fibroblasts of the oral mucosa are activated, and lesions can result from the actions of CsA, which has a proliferative impact on fibroblasts^[2,3].

In the present case, granulomatous nodules were detected in the non-gingival oral mucosa within a short time after the onset of GVHD. Initially, nodules were identified on the lower lip and left buccal mucosa; however, they spontaneously disappeared.

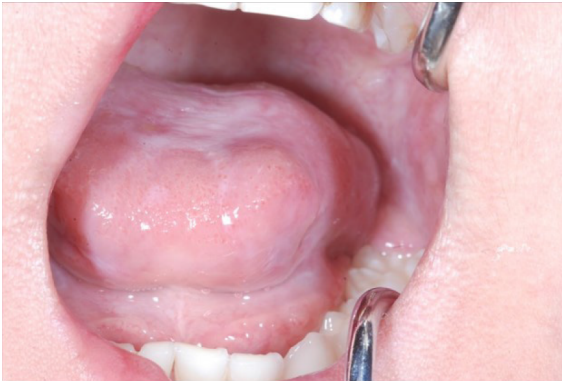

Figure 5 We observed no recurrence of the lesion at 1 year and 5 mo after the procedure.

Later, a nodule emerged at the left tongue border and was surgically removed. Prior to the appearance of these nodules, exacerbation of oral GVHD was observed.

In this case, FK506 was administered in an attempt to prevent and later treat GVHD instead of CsA. FK506 is a calcineurin inhibitor with a similar mechanism of action as CsA. CsA promotes fibroblast proliferation and collagen and glycosaminoglycan synthesis and likewise suppresses their degradation, resulting in connective tissue growth^[4].

To our knowledge, 15 cases of transplant-related calcineurin inhibitor-induced oral inflammatory nodules with chronic and oral GVHD have been reported^[5-7] (Table 1). The age at transplant was between 11 mo and 50 years, and the present case was the youngest. There were 12 cases where CsA was used as a calcineurin inhibitor and 3 cases where FK506 was used.

On the other hand, Terasawa *et al*^[8] reported the case of a patient with GVHD with a nodule on the lower lip associated with CMV infection. In this case, we examined the nodule that tested negative for CMV. However, it is possible that CMV was involved in generating the earlier lesions that spontaneously disappeared. In Table 1, only four cases, including our case, checked for CMV. Therefore, it is necessary to consider CMV infection when examining the presence of granulomatous nodules with GVHD.

Based on our findings, our conclusion is that the tongue granuloma reported in this patient is most likely the result of fibroblast activation during recovery from oral GVHD exacerbated by the proliferative actions of the calcineurin inhibitor FK506.

Patients with GVHD have a high risk of developing secondary tumors typically within 5 to 10 years following BMT^[9]. Furthermore, immunosuppressive agents and steroids administered prophylactically are also risk factors of secondary cancers. Therefore, it is necessary to follow-up with patients who develop GVHD to detect any malignancies as early as possible.

CONCLUSION

We experienced a rare case of granuloma on the tongue of a pediatric patient with GVHD. The differential diseases include malignant tumor and CMV infection. However, these diseases do not have unique clinical features and can only be differentiated *via* histopathological examination and quantitative deoxyribonucleic acid testing of the diseased tissue. In particular, if GVHD is present at the base and if immunosuppressive agents and steroids are being administered, it is extremely important to distinguish it from malignant tumors.

Table 1 Cases of transplant-related calcineurin inhibitor-induced oral inflammatory nodules with chronic and oral graft-versus-host disease

Year	Ref.	Age at transplant	Sex	Primary disease	ChronicGVHD	Oral GVHD	Calcineurininhibitor	Location	Treatment	Malignancy	CMV
1994	Lee <i>et al</i> ^[3]	19	M	AML	O	O	CsA	Buccal mucosa	Excision	No	Negative
1994	Lee <i>et al</i> ^[3]	45	M	CLL	O	O	CsA	Buccal mucosa	Excision	No	Negative
1994	Woo <i>et al</i> ^[2]	36	F	AML	O	O	CsA	Buccal mucosa, lower lip	Excision	No	Negative
1996	Woo <i>et al</i> ^[2]	27	F	CML	O	O	CsA	Buccal mucosa	Excision	No	Not stated
1996	Woo <i>et al</i> ^[2]	31	M	AML	O	O	CsA	Tongue	Excision	No	Not stated
1996	Woo <i>et al</i> ^[2]	50	F	Myelodysplasia	O	O	CsA	Buccal mucosa	Excision	No	Not stated
1996	Woo <i>et al</i> ^[2]	29	F	AML	O	O	CsA	Buccal mucosa	Excision	No	Not stated
1996	Woo <i>et al</i> ^[2]	33	F	CML	O	O	CsA	Tongue	Excision	No	Not stated
1996	Woo <i>et al</i> ^[2]	34	M	AML	O	O	CsA	Tongue	Excision	No	Not stated
2007	Al-Mohaya <i>et al</i> ^[5]	8	M	ALL	O	O	CsA	Tongue	Excision	No	Not stated
2007	Al-Mohaya <i>et al</i> ^[5]	3	M	PNP deficiency	O	O	FK506	Tongue	Excision	No	Not stated
2009	Suh <i>et al</i> ^[6]	46	M	Multiple myeloma	O	O	CsA	Tongue	Excision	No	Not stated
2016	Cheney-Peters <i>et al</i> ^[7]	9 and 11	M	Fanconi anemia	O	O	FK506	Tongue	Excision	No	Not stated
2016	Cheney-Peters <i>et al</i> ^[7]	19	M	Hodgkin's disease	O	O	CsA	Buccal mucosa	Excision	No	Not stated
2020	Present case	11 mo and 1	F	PID	O	O	FK506	Buccal mucosa, lower lip, tongue	Natural disappearance or excision	No	Negative

GVHD: Graft-versus-host disease; CMV: Cytomegalovirus; AML: Acute myelocytic leukemia; CLL: Chronic lymphocytic leukemia; CML: Chronic myelogenous leukemia; ALL: Acute lymphocytic leukemia; PNP: Purine nucleoside phosphorylase; PID: Primary immunodeficiency disease; CsA: Cyclosporine A; FK506: Tacrolimus.

ACKNOWLEDGEMENTS

The authors would like to thank Dr. Mari Tanaka from the Department of Pediatrics, Tokyo Medical and Dental University, for her kind of this case.

REFERENCES

- 1 **Filipovich AH**, Weisdorf D, Pavletic S, Socie G, Wingard JR, Lee SJ, Martin P, Chien J, Przepiorka D, Couriel D, Cowen EW, Dinndorf P, Farrell A, Hartzman R, Henslee-Downey J, Jacobsohn D, McDonald G, Mittleman B, Rizzo JD, Robinson M, Schubert M, Schultz K, Shulman H, Turner M, Vogelsang G, Flowers ME. National Institutes of Health consensus development project on criteria for clinical trials in chronic graft-versus-host disease: I. Diagnosis and staging working group report. *Biol Blood Marrow Transplant* 2005; **11**: 945-956 [PMID: 16338616 DOI: 10.1016/j.bbmt.2005.09.004]

- 2 **Woo SB**, Allen CM, Orden A, Porter D, Antin JH. Non-gingival soft tissue growths after allogeneic marrow transplantation. *Bone Marrow Transplant* 1996; **17**: 1127-1132 [PMID: 8807125]
- 3 **Lee L**, Miller PA, Maxymiw WG, Messner HA, Rotstein LE. Intraoral pyogenic granuloma after allogeneic bone marrow transplant. Report of three cases. *Oral Surg Oral Med Oral Pathol* 1994; **78**: 607-610 [PMID: 7838468 DOI: 10.1016/0030-4220(94)90173-2]
- 4 **Arora PD**, Silvestri L, Ganss B, Sodek J, McCulloch CA. Mechanism of cyclosporin-induced inhibition of intracellular collagen degradation. *J Biol Chem* 2001; **276**: 14100-14109 [PMID: 11278659 DOI: 10.1074/jbc.M010298200]
- 5 **Al-Mohaya M**, Treister N, Al-Khadra O, Lehmann L, Padwa B, Woo SB. Calcineurin inhibitor-associated oral inflammatory polyps after transplantation. *J Oral Pathol Med* 2007; **36**: 570-574 [PMID: 17850443 DOI: 10.1111/j.1600-0714.2007.00557.x]
- 6 **Suh JD**, Blackwell KE, Nabili V. Graft-versus-host disease of the tongue. *Otolaryngol Head Neck Surg* 2009; **140**: 272-273 [PMID: 19201305 DOI: 10.1016/j.otohns.2008.10.015]
- 7 **Cheney-Peters D**, Lund TC. Oral Pyogenic Granuloma after Bone Marrow Transplant in the Pediatric/Adolescent Population: Report of 5 Cases. *J Pediatr Hematol Oncol* 2016; **38**: 570-573 [PMID: 27271813 DOI: 10.1097/MPH.0000000000000593]
- 8 **Terasawa F**, Shirozu T, Moon M, Tatematsu T, Kouketsu A, Ishibashi K, Maeda M, Kaetsu A. Intraoral pseudotumor of lower lip mucosa due to cytomegalovirus infection after bone marrow transplantation in a leukemia patient: A case report. *J Oral Maxillofac Surg Med Pathol* 2013; **25**: 167-170 [DOI: 10.1016/j.ajoms.2012.12.004]
- 9 **Demarosi F**, Soligo D, Lodi G, Moneghini L, Sardella A, Carrassi A. Squamous cell carcinoma of the oral cavity associated with graft vs host disease: report of a case and review of the literature. *Oral Surg Oral Med Oral Pathol Oral Radiol Endod* 2005; **100**: 63-69 [PMID: 15953918 DOI: 10.1016/j.tripleo.2004.12.008]