

Risk Factor for Additional Intravenous Medication during Transforaminal Full-endoscopic Lumbar Discectomy under Local Anesthesia

Seiji YAMAYA,^{1,2} Fumitake TEZUKA,¹ Kosuke SUGIURA,¹ Makoto TAKEUCHI,¹ Hiroaki MANABE,^{1,3} Masatoshi MORIMOTO,¹ Kazuta YAMASHITA,¹ Yoichiro TAKATA,¹ Toshinori SAKAI,¹ Toru MAEDA,¹ and Koichi SAIRYO¹

¹Department of Orthopedics, Tokushima University, Tokushima, Tokushima, Japan

²Department of Orthopaedic Surgery, Sendai Nishitaga National Hospital, Sendai, Miyagi, Japan

³Department of Orthopedic Surgery, Tokushima Prefecture Naruto Hospital, Tokushima, Tokushima, Japan

Abstract

Transforaminal full-endoscopic lumbar discectomy (TELD) can be performed under local anesthesia. However, there have been no reports on risk factors for a change in vital signs or the need for additional medications to maintain adequate analgesia during this procedure. The purpose of this study was to identify risk factors for additional intravenous medication during TELD under local anesthesia. The following factors were retrospectively evaluated in 113 consecutive patients who underwent TELD under local anesthesia at our institution: demographic characteristics, radiological features at the intervertebral disc level, distance between the superior articular process and the exiting nerve root, height of the intervertebral disc, height of the bulging disc, height of the intervertebral foramen, and distance from the insertion site to the spinous process on magnetic resonance imaging (MRI) and computed tomography (CT) scans of the lumbar spine. Logistic regression analysis was performed to determine factors associated with the need for additional drugs. In all, 23 cases (20.4%) required additional intraoperative medications because of hypertension, hypotension, bradycardia, or pain. Logistic regression analysis revealed that age (partial regression coefficient 0.05, $p = 0.02$) and bulging disc height (partial regression coefficient -0.7 , $p = 0.003$) influenced the need for additional drugs. There were significant associations of need for additional intravenous medication with older age (>62 years) and a smaller bulging disc height (<8.2 mm). Patients with these factors require close monitoring for changes in vital signs or increasing pain when performing TELD under local anesthesia and may need additional intravenous medication.

Keywords: transforaminal full-endoscopic lumbar discectomy, lumbar disc herniation, minimally invasive spine surgery, local anesthesia, complications

Introduction

Surgical treatment of lumbar disc herniation (LDH) has been steadily advancing. In 1989, Hijikata described percutaneous nucleotomy, which was a minimally invasive procedure performed under local

anesthesia for LDH.¹⁾ More recently, posterolateral full-endoscopic lumbar discectomy has been developed for LDH.^{2–6)} Transforaminal full-endoscopic lumbar discectomy (TELD) through Kambin's safety triangle is a posterolateral approach that can be performed with an 8-mm skin incision and minimal disruption of spinal structures including ligaments and muscles. According to a meta-analysis that compared TELD with standard discectomy for LDH, although the visual analog scale score, MacNab score, complications, recurrence rate, and incidence of reoperation were equivalent between the two

Received August 5, 2020; Accepted November 6, 2020

Copyright© 2021 by The Japan Neurosurgical Society This work is licensed under a Creative Commons Attribution-NonCommercial-NoDerivatives International License.

groups, the clinical outcomes after TELD were superior to those after standard discectomy in terms of blood loss, operating time, hospital stay, and mean duration of disability.⁷⁾

However, a complication of TELD is exiting nerve root injury with postoperative dysesthesia and motor weakness. Exiting nerve root injury has a reported frequency of 1.0%–8.9% and is known to reduce physical function and overall patient satisfaction after TELD.^{8,9)} To avoid this complication, patients require intraoperative monitoring for symptoms such as leg pain or numbness; therefore, it is recommended that TELD be performed under local anesthesia. Although there have been some reports of TELD being performed under epidural or general anesthesia because of difficulty in the management of local anesthesia,^{10,11)} symptoms of intraoperative exiting nerve root “irritation,” such as leg pain or numbness, can only be confirmed under local anesthesia. At our institution, TELD is performed under local anesthesia in all cases.

In general, patients require careful monitoring for anaphylaxis and cardiovascular toxicity associated with local anesthetics during surgery. Although severe cases are very rare, it is important to assess the patient’s general condition, including their vital signs, and manage them. We also need to avoid any pain related to the procedure. There have been no reports on risk factors for a change in vital signs or the need for additional medication during TELD under local anesthesia.

Materials and Methods

The study was approved by the institutional review board at our institution (approval number #2788-1). We retrospectively reviewed the medical charts and anesthesia records from 121 consecutive cases of herniated nucleus pulposus (HNP) in 113 patients who underwent TELD under local anesthesia at our institution from May 2014 to December 2016. The same surgeon performed all the surgical procedures and was responsible for the intraoperative anesthetic management, including monitoring of vital signs and ordering additional intravenous medication during surgery when necessary.

Premedication protocol and local anesthesia

Hydroxyzine hydrochloride (25–50 mg) and pentazocine hydrochloride (7.5–15 mg) were administered intravenously for premedication followed by local anesthesia. About 7–9 mL of 1% lidocaine was injected subcutaneously, including 2 mL at the facet joint and 2 mL just below the surface of the annulus fibrosus (Fig. 1).

TELD and intraoperative medication protocol

In all cases, a duckbill cannula was inserted after carefully performing cylinder dilation. If the patient felt severe low back or leg pain, or developed hypertension, hypotension, tachycardia, or bradycardia during the operation, appropriate additional medication (pentazocine hydrochloride 7.5 mg for pain, nicardipine hydrochloride 0.5–1.0 mg for hypertension, or atropine sulfate 0.25 mg for bradycardia) was administered intravenously (Fig. 1). If a patient had symptoms associated with exiting nerve root irritation when the “inside-out” technique was being performed, we switched to a procedure to avoid exiting nerve root injury, such as the “outside-in” technique with foraminoplasty^{12–15)} or the “two incision” method. The inside-out technique is the procedure in which the cannula is placed into the disc to remove the HNP. The outside-in technique is the procedure whereby the cannula is placed in the intervertebral foramen to remove the HNP from the outside of the disc; this technique is performed with foraminoplasty using a high-speed drill to widen Kambin’s safety triangle and get closer to the HNP. The “two incision” method involves changing the insertion site of the initial needle medially to avoid exiting nerve root irritation.

Patient characteristics, intraoperative information, and radiological measurements

The following factors were examined: sex, age, body mass index, intervertebral disc level, and intraoperative variables, such as operating time per disc, total amount of local anesthetic used, and approach point (distance from the insertion site to the spinous process). The distance between the superior articular process and the exiting nerve root was assessed by magnetic resonance imaging (MRI) using axial T2-weighted images (Figs. 2A and 2B).^{9,16,17)} We used the Aquarius NET Server (TeraRecon, Inc., San Mateo, CA, USA) to reconstruct computed tomography (CT) images. First, the facet joint was identified on the axial slice (Fig. 3A) through the center of the disc space. We then reconstructed a sagittal slice through the center of the facet joint on the axial slice (Fig. 3A) and parallel to the pedicle on the coronal slice (Fig. 3B). The heights of the intervertebral disc (Fig. 3C-1), bulging disc (Fig. 3C-2), and intervertebral foramen (Fig. 3C-3) were measured on the reconstructed sagittal view. Bulging disc height is different from intervertebral disc height and indicates the distance between the upper vertebral endplate and the lower pedicle.^{16,18)} The distance from the insertion site to the spinous process and the frequency of administration of additional intraoperative intravenous medication

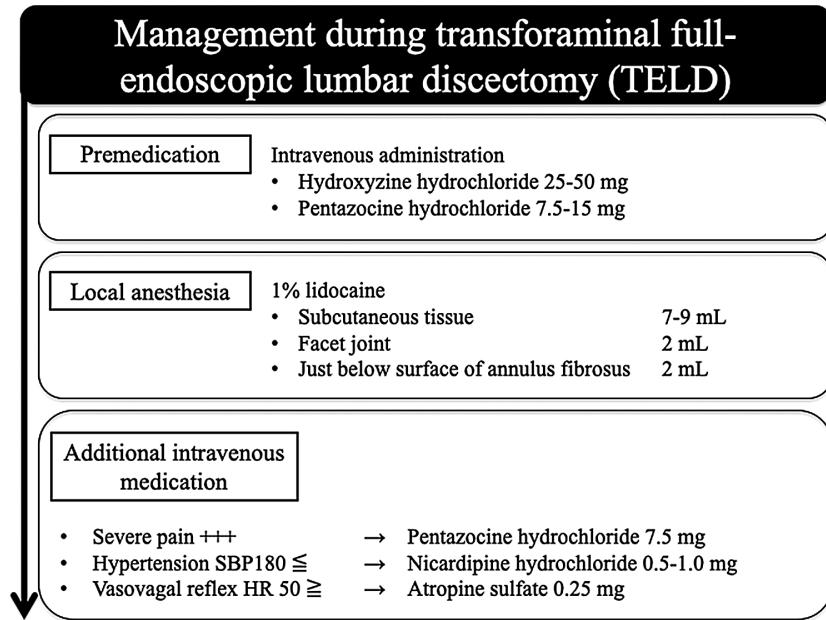


Fig. 1 Hydroxyzine hydrochloride and pentazocine hydrochloride were administered intravenously for premedication. Thereafter, 1% lidocaine was injected into the subcutaneous tissue, the facet joint, and just below the surface of the annulus fibrosus. Appropriate additional intravenous medication was administered if the patient reported pain or developed hypertension, hypotension, tachycardia, or bradycardia due to triggering of the vasovagal reflex during the operation.

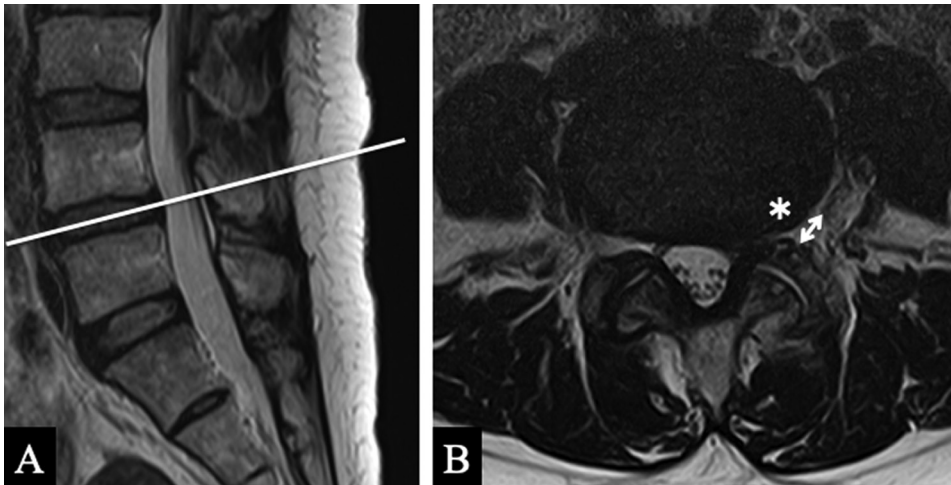


Fig. 2 Measurement of the distance (*) between the superior articular process and the exiting nerve root using the axial view through the center of the disc space of the sagittal view on T2-weighted MRI. (A) Sagittal view. (B) Axial view. MRI: magnetic resonance imaging.

(pentazocine hydrochloride 7.5 mg for pain, nicardipine hydrochloride 0.5–1.0 mg for hypertension, or atropine sulfate 0.25 mg for bradycardia) were recorded.

Statistical analysis

Multivariate regression analysis was performed to identify factors associated with the need for additional intravenous medication due to pain or

development of hypertension, hypotension, tachycardia, or bradycardia during the operation. The primary objective was the frequency of administration of additional intravenous medication during TELD. The explanatory variables were sex, age, body mass index, intervertebral disc level, distance between the superior articular process and the exiting nerve root (measured on axial MRI), height of the

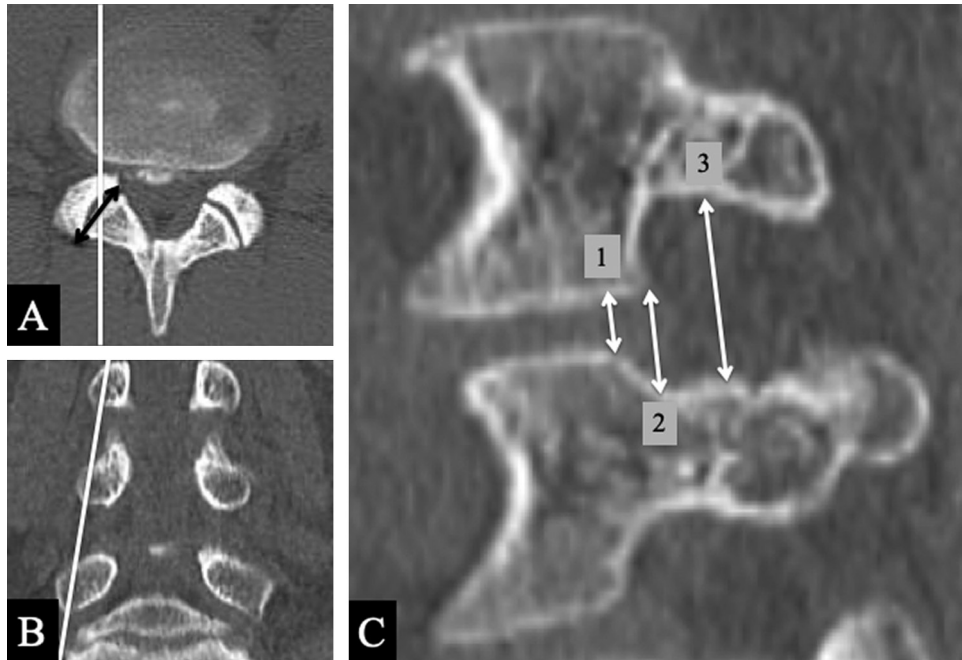


Fig. 3 Reconstructed axial (A), coronal (B), and sagittal (C) CT images of the lumbar spine. The heights of the intervertebral disc (C-1), the bulging disc (C-2), and the intervertebral foramen (C-3) were measured on a sagittal slice. CT: computed tomography.

intervertebral disc, height of the bulging disc, height of the intervertebral foramen (measured on CT images), and distance from the insertion site to the spinous process. JMP software version 11.0 (SAS Institute Inc., Cary, NC, USA) was used for the statistical analysis.

Results

Patient characteristics and intraoperative data

The subjects were 113 patients (70 men and 43 women) with a mean age of 44 years and a mean body mass index of 23.7. Patient characteristics and intraoperative data are summarized in Table 1. The intervertebral disc levels treated were L2-L3 (n = 6 discs), L3-L4 (n = 19), L4-L5 (n = 69), and L5-S1 (n = 27). The mean operating time per intervertebral disc was 69 min, the total amount of local anesthetic (1% lidocaine) used was 13 mL, and the mean distance from the insertion site to the spinous process was 6.9 cm for L2-L3, 7.8 cm for L3-L4, 8.7 cm for L4-L5, and 8.0 cm for L5-S1. There were no premedication-related complications, such as nausea, vomiting, or respiratory depression as a result of oversedation.

Preoperative MRI and CT measurements

Mean distance between the superior articular process and the exiting nerve root measured on the axial MRI

scans was 6.8 mm. The mean heights of the intervertebral disc, bulging disc, and intervertebral foramen measured on parasagittal CT slices were 6.0 mm, 8.8 mm, and 18.0 mm, respectively (Table 2).

Risk factors of additional intraoperative medications

In all, 23 patients (20.4%) required additional intravenous medication (an analgesic in 5 cases, an antihypertensive agent in 13, and a vasopressor in 8); 6 cases (5%) required medication due to sudden bradycardia or hypotension during surgery.

Logistic regression analysis revealed significant associations of age (partial regression coefficient 0.05, $p = 0.02$) and bulging disc height (partial regression coefficient -0.7 , $p = 0.003$) with the frequency of administering additional intravenous medication. Receiver-operating characteristic curve analysis identified the cutoff values of 62 years for age ($p = 0.0003$, area under the curve 0.73, sensitivity 54%, specificity 86%) and 8.2 mm for bulging disc height ($p < 0.001$, area under the curve 0.80, sensitivity 86%, specificity 72%).

Discussion

There have been few reports on intraoperative sedation, analgesia, and monitoring of vital signs during TELD under local anesthesia. Some studies have investigated the effectiveness and safety of continuous intravenous infusion of dexmedetomidine

Table 1 Patient characteristics and intraoperative information

Sex (male/female)		70/43
Mean age (years old)		44 (15–86)
Body mass index		23.7
Disc level (discs)	L2-L3:	6
	L3-L4:	19
	L4-L5:	69
	L5-S1:	27
		Mean (range)
Operative time per disc (min)		69 (28–110)
Total amount of local anesthetic use (mL)		13 (4–27)
Distance from the insertion site to the spinous process (cm)	L2-L3:	6.9
	L3-L4:	7.8
	L4-L5:	8.7
	L5-S1:	8.0
		(113 patients/121 discs)

Table 2 Radiological measurements using MRI and CT

	Mean (range)
Distance between the superior articular process and the exiting nerve root (mm)	6.8 (1.1–11.6)
Height of the intervertebral disc (mm)	6.0 (1.4–10.4)
Height of the bulging disc (mm)	8.8 (1.8–3.9)
Height of the intervertebral foramen (mm)	18.0 (10.9–25.5)
	(113 patients/121 discs)

CT: computed tomography, MRI: magnetic resonance imaging.

for intraoperative sedation during TELD under local anesthesia.¹⁹⁾ Unlike midazolam or propofol, dexmedetomidine can be used for procedural sedation in the prone position without concern over respiratory depression. However, this agent has side effects that include bradycardia and hypotension; therefore, it should be used by only experienced doctors such as anesthesiologists who can manage the patient's general status during a procedure.^{19,20)} Our premedication protocol routinely includes hydroxyzine hydrochloride and pentazocine hydrochloride, and we did not identify any cases of severe intraoperative complications related to these premedication agents, such as respiratory depression due to oversedation.

Although we do not use additional intravenous medication during surgery other than the standard agents showed in Fig. 1, 23 of our patients (20.4%) required additional medication because of hypertension, hypotension, bradycardia, or pain. Use of additional intravenous medication was significantly

associated with older age (>62 years) and smaller bulging disc height (<8.2 mm). Patients with these factors require particularly careful monitoring to detect changes in vital signs and increasing intraoperative pain when performing TELD under local anesthesia. Six patients (5%) developed sudden bradycardia or hypotension during surgery and required intravenous medication immediately. These events might have been due to triggering of the vasovagal reflex in response to pain.

In total, 105 of the 113 cases underwent TELD at a single disc level and 8 underwent TELD at 2 levels during the same procedure. The total volume of 5% lidocaine administered was higher when TELD was performed at 2 levels than when it was performed at a single level. However, there was no significant difference in the need for additional intravenous medication according to a number of disc levels. Four cases underwent TELD as a revision surgery, which was not a risk factor for needing additional intravenous medication.

The rationale for the recommendation that TELD be performed under local anesthesia is that surgeons can obtain feedback from awake patients during the procedure, which can help to avoid intraoperative nerve root injury.^{5,21)} However, in the clinical setting, we sometimes encounter patients in whom the approach is difficult because the intervertebral foramen is narrow in relation to the size of the cannula. Ozer et al. evaluated anatomical variations in Kambin's triangle by surgical views and cadaveric studies and alerted surgeons to the possibility of nerve damage during endoscopic lumbar surgery in patients with a small or no apparent triangle.²²⁾ Surgeons need to predict the size of Kambin's triangle preoperatively; however, it cannot be measured accurately even on CT or MRI. Therefore, other indicators are needed to identify difficult cases before surgery. We evaluated disc space narrowing in 160 patients who underwent microendoscopic discectomy and found that disc space may be a useful predictor of the size of Kambin's triangle before performing TELD.²³⁾ In our present study, bulging disc height was measured as the distance from the upper vertebral endplate to the lower pedicle and not the intervertebral disc height. In view of our results regarding the need for additional intravenous medication, bulging disc height may predict the area of safety for insertion of the cannula in TELD.

This study has some limitations, which stem mainly from its retrospective design. All the data analyzed were obtained by review of medical charts and anesthesia records. Although information on comorbidities such as diabetes mellitus, hypertension, hyperlipidemia, cardiovascular disease, and psychiatric disorders was recorded, we could not access the information on any oral medications prescribed for these conditions, which might have affected baseline vital signs during surgery. Furthermore, we had no data on preoperative symptoms, preoperative visual analog/numeric rating scale scores, or the interval between diagnosis and surgery. Therefore, we cannot definitively conclude whether or not changes in vital signs during TELD, such as bradycardia, hypertension, and hypotension, are due to inadequate pain control or nerve root irritation.

In conclusion, the use of additional intravenous medication during TELD was significantly associated with older age and smaller bulging disc height. Patients with these features should be monitored carefully for changes in vital signs and increasing intraoperative pain during TELD under local anesthesia and may need additional intravenous medication.

Conflicts of Interest Disclosure

All authors confirm that there are no conflicts of interest with people or organizations regarding this report.

References

- 1) Hijikata S: Percutaneous nucleotomy. A new concept technique and 12 years' experience. *Clin Orthop Relat Res* 238: 9–23, 1989
- 2) Kambin P, Schaffer JL: Percutaneous lumbar discectomy. Review of 100 patients and current practice. *Clin Orthop Relat Res* 238: 24–34, 1989
- 3) Schreiber A, Leu H: Percutaneous nucleotomy: technique with discoscopy. *Orthopedics* 14: 439–444, 1991
- 4) Yeung AT: The evolution of percutaneous spinal endoscopy and discectomy: state of the art. *Mt Sinai J Med* 67: 327–332, 2000
- 5) Yeung AT, Tsou PM: Posterolateral endoscopic excision for lumbar disc herniation: surgical technique, outcome, and complications in 307 consecutive cases. *Spine (Phila Pa 1976)* 27: 722–731, 2002
- 6) Yeung AT, Yeung CA: Minimally invasive techniques for the management of lumbar disc herniation. *Orthop Clin North Am* 38: 363–372; abstract vi, 2007
- 7) Li X, Han Y, Di Z, et al.: Percutaneous endoscopic lumbar discectomy for lumbar disc herniation. *J Clin Neurosci* 33: 19–27, 2016
- 8) Sairyo K, Matsuura T, Higashino K, et al.: Surgery related complications in percutaneous endoscopic lumbar discectomy under local anesthesia. *J Med Invest* 61: 264–269, 2014
- 9) Choi I, Ahn JO, So WS, Lee SJ, Choi IJ, Kim H: Exiting root injury in transforaminal endoscopic discectomy: preoperative image considerations for safety. *Eur Spine J* 22: 2481–2487, 2013
- 10) Fang G, Ding Z, Song Z: Comparison of the effects of epidural anesthesia and local anesthesia in lumbar transforaminal endoscopic surgery. *Pain Physician* 19: E1001–1004, 2016
- 11) Yoshikawa H, Andoh T, Tarumoto Y, Yamada R, Akihisa Y, Kudoh I: [Usefulness of epidural anesthesia for percutaneous endoscopic lumbar discectomy (PELD)]. *Masui* 60: 1370–1377, 2011 (Japanese)
- 12) Henmi T, Terai T, Hibino N, et al.: Percutaneous endoscopic lumbar discectomy utilizing ventral epiduroscopic observation technique and foraminoplasty for transligamentous extruded nucleus pulposus: technical note. *J Neurosurg Spine* 24: 275–280, 2016
- 13) Abe M, Takata Y, Higashino K, et al.: Foraminoplasty transforaminal percutaneous endoscopic discectomy at the lumbosacral junction under local anesthesia in an elite rugby player. *J Med Invest* 62: 238–241, 2015
- 14) Sairyo K, Higashino K, Yamashita K, et al.: A new concept of transforaminal ventral facetectomy including simultaneous decompression of foraminal

- and lateral recess stenosis: technical considerations in a fresh cadaver model and a literature review. *J Med Invest* 64: 1–6, 2017
- 15) Sairyo K, Chikawa T, Nagamachi A: State-of-the-art transforaminal percutaneous endoscopic lumbar surgery under local anesthesia: discectomy, foraminoplasty, and ventral facetectomy. *J Orthop Sci* 23: 229–236, 2018
 - 16) Hurdal Y, Xu B, Guo L, et al.: Radiographic measurement for transforaminal percutaneous endoscopic approach (PELD). *Eur Spine J* 26: 635–645, 2017
 - 17) Min JH, Kang SH, Lee JB, Cho TH, Suh JK, Rhyu IJ: Morphometric analysis of the working zone for endoscopic lumbar discectomy. *J Spinal Disord Tech* 18: 132–135, 2005
 - 18) Henmi T, Terai T, Nagamachi A, Sairyo K: Morphometric changes of the lumbar intervertebral foramen after percutaneous endoscopic foraminoplasty under local anesthesia. *J Neurol Surg A Cent Eur Neurosurg* 79: 19–24, 2018
 - 19) Kim KH: Safe sedation and hypnosis using dexmedetomidine for minimally invasive spine surgery in a prone position. *Korean J Pain* 27: 313–320, 2014
 - 20) Gerlach AT, Dasta JF: Dexmedetomidine: an updated review. *Ann Pharmacother* 41: 245–252, 2007
 - 21) Ahn S-S, Kim S-H, Kim D-W: Learning curve of percutaneous endoscopic lumbar discectomy based on the period (early vs. late) and technique (in-and-out vs. in-and-out-and-in): a retrospective comparative study. *J Korean Neurosurg Soc* 58: 539–546, 2015
 - 22) Ozer AF, Suzer T, Can H, et al.: Anatomic assessment of variations in Kambin's triangle: a surgical and cadaver study. *World Neurosurg* 100: 498–503, 2017
 - 23) Yamaya S, Nomura K, Nakamura Y, et al.: Can patients treated by MED become candidates for transforaminal PED? *J Spine Res* 8: 1375–1380, 2017 (Japanese)

Corresponding author: Koichi Sairyo, MD, PhD
 Department of Orthopedics, Tokushima University,
 3-18-15 Kuramoto, Tokushima, Tokushima 770-8503,
 Japan.
e-mail: sairyokun@gmail.com