

CASE REPORT

A case of Gross E esophageal atresia discovered following a unique clinical course

Noriko Yokota¹, Hiroki Ishibashi¹, Kenichi Suga², Hiroki Mori¹, Akiko Kitamura², Ryuji Nakagawa², and Mitsuo Shimada¹

¹Department of Pediatric and Pediatric Endoscopic Surgery, Tokushima University, Tokushima, Japan, ²Department of Pediatrics, Tokushima University, Tokushima, Japan

Abstract: The patient was a 15 months-old boy who had been diagnosed CHARGE syndrome, which is a multiple congenital anomaly syndrome caused by mutations in the *CHD7* gene. Mechanical ventilation management was initiated 2 hours after birth for dysphagia and respiratory failure, and tracheotomy was performed 3 months after birth for dysphagia and failed extubation. He was repeatedly hospitalized due to pneumonias. Approximately 1 year after birth, the boy had two consecutive episodes of sudden ventilatory insufficiency while replacing the tracheotomy cannula. A bronchoscopic examination under general anesthesia revealed a tracheoesophageal fistula directly below the tracheostomy. The patient was diagnosed with Gross E esophageal atresia, and we speculated that the cannula migrated to the esophagus via the fistula during tracheostomy cannula replacement. Gross E esophageal atresia is a rare disease. Its diagnosis is often delayed, and it is discovered by recurrent pneumonia in many cases. A tracheoesophageal fistula may also be found in children with deformities of the respiratory system. Furthermore, tracheoesophageal fistulae are often found in the neck. Therefore, when sudden ventilatory insufficiency occurs in a child with a tracheostomy after replacing the tracheostomy cannula, caution must be exercised since the cannula may have migrated to the esophagus via a fistula. *J. Med. Invest.* 69 : 141-144, February, 2022

Keywords: Gross E esophageal atresia, congenital H-type tracheoesophageal fistula, sudden ventilatory insufficiency during cannula replacement, CHARGE syndrome

INTRODUCTION

Among the congenital deformities of the esophagus, Gross E esophageal atresia has a low incidence rate. Since it has various clinical symptoms and no obstruction to the passage, the condition is often difficult to diagnose. Gross E esophageal atresia is accompanied by cyanosis, bloating sensation, asphyxia, aspiration, and recurrent respiratory infections such as pneumonia and accounts for 3.3%–5.8% of all cases of esophageal atresia (1, 2). Here, we report a case of Gross E esophageal atresia that was diagnosed following sudden ventilatory insufficiency due to the migration of a tracheostomy cannula to the esophagus via a fistula during cannula replacement as a complication of coloboma, heart defects, atresia of choanae, retarded growth and development, genital abnormalities, and ear anomalies (CHARGE) syndrome (3-5) with a literature review.

CASE

The patient was a 15-month-old boy who presented with the chief complaint of recurrent sudden ventilatory insufficiency during tracheostomy cannula replacement.

His familial history revealed that his older brother had a history of surgery for cleft lip and palate, but was normal in terms of mental and physical development and his older sister had a

history of surgery for congenital duodenal stenosis linked to annular pancreas, but there was no chromosomal abnormality or abnormal mental and physical development.

His mother had a history of giving birth to children with congenital anomalies; she underwent amniocentesis when the patient was a 16-week-old fetus, but the karyotype was normal. By fetal ultrasound performed at 25 weeks, deformities (right lip and palate cleft, anomalous origin of the right subclavian artery, absence of the right kidney, mega cisterna magna, and cerebellar hypoplasia) were noted. The child was born by spontaneous vaginal delivery at a gestational age of 39 weeks and 0 days with a birth weight of 2,658 g and an Apgar score of 8 at 1 minute and 10 at 5 minutes after birth. G-band analysis showed a normal male karyotype (46, XY).

Next-generation sequencing targeted to *CHD7* gene indicated large deletion exons 14 and 15 of the *CHD7* gene and following multiplex ligation-dependent probe amplification confirmed approximately 50% decrease in the signals for exons 14 and 15 of the *CHD7* gene at 13 months of age. Among the symptoms constituting the acronym CHARGE, the case patient did not present with coloboma, atresia of choanae and genital abnormalities, but had heart defects (patent ductus arteriosus and multifocal atrial tachycardia), cleft lip and palate, retarded growth and development (frontal lobe and bilateral hippocampal atrophies, cerebellar and brain stem hypoplasias), and ear anomalies (sensorineural deafness). In addition, the right kidney was absent.

Mechanical ventilation management was initiated for suffocation 2 hours after birth, and enteral feeding was initiated 2 days after birth. Abdominal distention was repeatedly observed under mechanical ventilation, especially high frequency oscillatory ventilation. A laryngoscopy by otorhinolaryngologist did not show the cause of dysphagia and respiratory failure. A tracheotomy was performed at our department 3 months after birth for

Received for publication September 17, 2021; accepted September 30, 2021.

Address correspondence and reprint requests to Hiroki Ishibashi, MD, Department of Pediatric and Pediatric Endoscopic Surgery, Tokushima University, 3-18-15 Kuramoto-cho, Tokushima 770-8503, Japan and Fax: +81-88-631-9698.

dysphagia and failed extubation, and the cannula was replaced regularly once a month. At 8 months of age, laparoscopic fundoplication (Nissen–Rossetti method) and gastrostomy were performed for gastroesophageal reflux. At 13 months of age, the patient experienced ventilatory insufficiency immediately after tracheostomy cannula replacement and developed cyanosis. Since ventilation was seen to be possible on slightly pulling the cannula, intratracheal granulation was suspected. Consequently, a bronchoscopy was performed under general anesthesia that revealed ventilation failure due to intratracheal granulation of the left main bronchus. The intratracheal granulation was treated by laser ablation, and the postoperative course was uneventful. At 14 months of age, the patient again experienced sudden ventilatory insufficiency immediately after cannula replacement and developed cyanosis and bradycardia. During resuscitation efforts, manual ventilation was attempted, but it was unsuccessful. When the tracheostomy cannula was replaced by another differently shaped cannula, ventilation was achieved and the patient's level of consciousness was restored. Because sudden ventilatory insufficiency occurred twice consecutively while a tracheostomy cannula was being replaced, deformities such as tracheoesophageal fistula and laryngotracheoesophageal cleft were suspected. Therefore, a plain chest computed tomography (CT) and bronchoscopy were performed under general anesthesia.

The plain chest CT at 2 months of age did not show a tracheoesophageal fistula, but the plain chest CT performed at 14 months of age revealed a tracheoesophageal fistula on the dorsal aspect of the trachea at the first thoracic vertebral level (Figure 1). Under general anesthesia, the tracheostomy was closed and a flexible bronchoscope was inserted while mask ventilation was provided; during this procedure, a tracheoesophageal fistula was identified directly under the tracheostomy (Figure 2). The fistula had an external diameter of 6.0 mm, which was about the same size as the tracheostomy cannula. It was presumed that during a tracheostomy cannula replacement, the cannula must have migrated to the esophagus via the tracheoesophageal fistula, causing sudden ventilatory insufficiency. The intratracheal granulation, which was previously removed by ablation, did not relapse. The patient was thus diagnosed with Gross E esophageal atresia and surgery was planned.

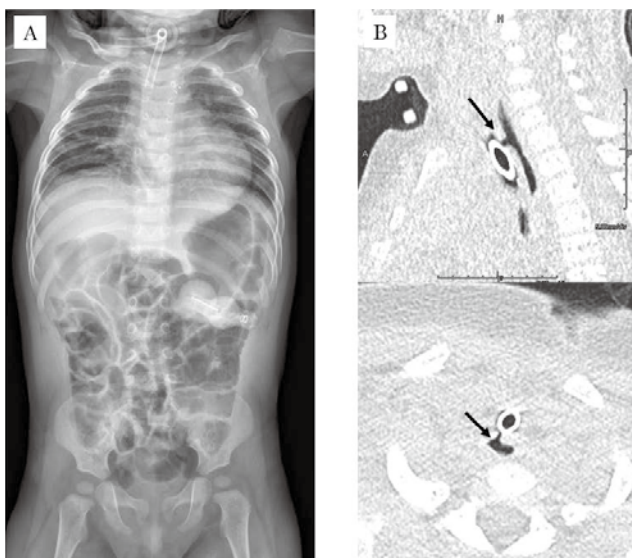


Figure 1. A) The X-ray, B) The plain chest CT findings at 14 months of age (Arrows indicate tracheoesophageal fistula.)

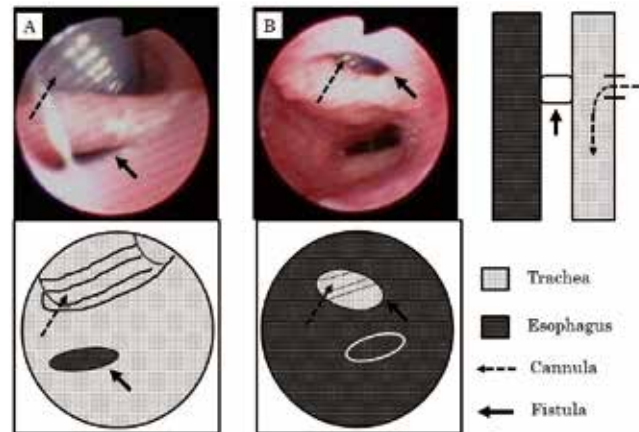


Figure 2. The bronchoscopic findings under general anesthesia. A) View from the trachea, B) View from the esophagus (Arrows indicate tracheoesophageal fistula.)

At the time of the surgery, the height and weight of the patient were 77.7 cm and 9.62 kg, respectively. Under general anesthesia, the patient's face was tilted to the left with the neck in the extension position, and a 3.5-cm skin incision was made along the supraclavicular crease by the right cervical approach. After the positions of the trachea and esophagus were identified, the esophagus was first separated and taped from the esophageal side to prevent recurrent laryngeal nerve injury. Next, the esophagus was pulled to separate the area surrounding the fistula. During the surgery, a flexible bronchoscope was inserted by an anesthesiologist, and using the light source as target, the tracheoesophageal fistula (Figure 3A) was identified and removed. The fistula had a diameter of approximately 7 mm. On the tracheal side, it was closed by continuous sutures using 5-0 PDS[®] (Figure 3Ba), and on the esophageal side, it was closed by a single knot suture using 5-0 PDS[®] (Figure 3Bb). To prevent recurrent fistula, the sternohyoid muscle was isolated as caudally as possible, and a flap was formed to cover and fix both the esophageal and tracheal sides of the closed fistula (Figure 3C). A drain was placed on the anterior aspect of the sternohyoid muscle, which was used to cover the sutured fistula to complete the surgery.

For 3 days after the surgery, the patient was sedated and a tracheostomy tube was placed such that its tip was over the fistula closure, and respiration was managed by mechanical ventilation. The postsurgical course was uneventful, and ventilation insufficiency during tracheostomy cannula replacement did not occur. A bronchoscopic examination performed at 8 months after the surgery did not show recurrent fistula (Figure 4). The patient is being followed up regularly in our outpatient clinic. Currently, about 18 months have passed since the surgery, and no recurrence of the fistula has been observed.

DISCUSSION

Gross E esophageal atresia is a type of esophageal atresia without passage obstruction in the presence of a tracheoesophageal fistula. It is a rare disease accounting for only 3.3%–5.8% of all the cases of esophageal atresia (2). The diagnosis of Gross E esophageal atresia is often delayed because the tracheoesophageal fistula is present but does not cause passage obstruction. In some cases, H-type esophageal atresia is diagnosed in adulthood for the first time. So, Gross E esophageal atresia is difficult to distinguish from gastroesophageal reflux or tracheomalacia (6).

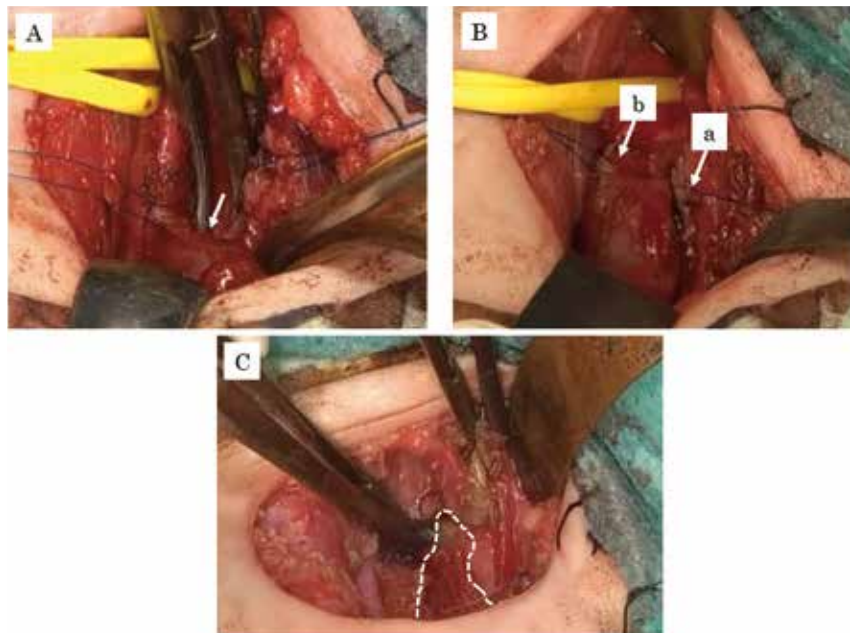


Figure 3. The operative findings A) The Arrow indicates tracheoesophageal fistula. B) Tracheoesophageal fistula was separated a) On the tracheal side, b) On the esophageal side. C) The sternohyoid muscle was formed to cover and fix both the esophageal and tracheal sides of the closed fistula.

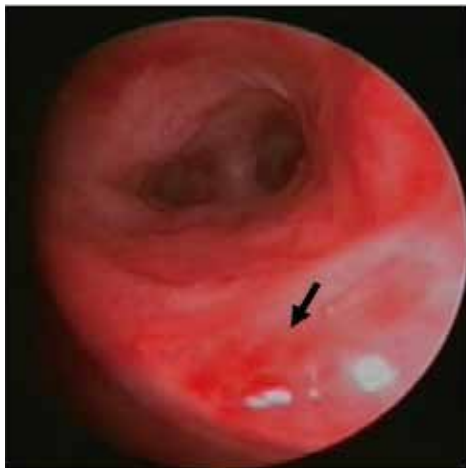

Figure 4. A bronchoscopic finding at 8 months after the surgery (Arrow indicates closed tracheoesophageal fistula.)

Its diagnosis is usually based on symptoms such as coughing while eating, bloating sensation, and pneumonia: recurrent episodes of respiratory infection and cyanosis are the most common (1, 2, 4, 7, 8). In newborn infants, weakness or choking during feeding can be the first signs of this disease (8). The present patient had been hospitalized several times in the pediatric department for severe pneumonia, but definitive diagnosis had not been established. In addition, because of the small size of the body at 2 months of age, no tracheoesophageal fistula was identified in the 0.5 mm slice plain chest CT. Due to complication with multiple anomalies, the patient was tube fed exclusively and had never eaten orally. Thus physical findings of food migration to the trachea through the fistula could not be obtained; this may also be a reason for the delayed diagnosis.

Since the tracheal cannula moved into the esophagus through the tracheoesophageal fistula during cannula exchange at

around 1 year of age, the location and size of the fistula may have changed with the patient's age. The cannula migrated to the esophagus once the fistula was positioned just below the tracheostomy and became large enough to accommodate the cannula. If there were resistance when exchanging the tracheal cannula, the tip of the cannula has partially entered the fistula and the fistula has become larger due to the expanding effect like a bougie. However, in this case, there was no resistance to insertion during tracheal cannula replacement before the onset of ventilatory insufficiency, so we consider this unlikely.

Bronchoscopy and esophagography in the prone position are particularly useful for making a definitive diagnosis in patients with suspected tracheoesophageal fistula (8, 9). However, diagnosis cannot be made in some cases even by the combined use of the abovementioned examination methods. In an examination using a rigid bronchoscope, respiratory management is possible while maneuvering the bronchoscope, but a fistula may be misidentified because the membranous trachea can only be observed along the tangential line (10). Indeed, in our case also, the fistula was missed in the first examination performed using a rigid bronchoscope. Therefore, the use of a flexible bronchoscope may prove beneficial for cases with suspected tracheoesophageal fistula.

In many cases, surgery with the cervical approach is possible; however, thoracotomy or thoracoscopic approach (11) is required when the fistula is located close to the tracheal bifurcation. Postoperative complications include suture failure of the fistula closure or recanalization of the tracheoesophageal fistula (12). Generally, the infrahyoid strap muscles (omohyoid or sternohyoid) are used for prevention of recurrence, but the sternocleidomastoid, lower pole of thyroid, thymus, connective or fibrous tissue, and mediastinal pleura, and fibrin glue have also been reportedly used (8, 13, 14). Similar to previous reports, the right sternohyoid muscle was used to prevent recurrent fistula in this case.

To the best of our knowledge, no previous reports have described Gross E esophageal atresia discovered following sudden ventilatory insufficiency when the tracheostomy cannula is

replaced. 30% of esophageal atresia cases are complicated by congenital multiple anomalies; VACTER association is a representative and several cases of CHARGE syndrome are also reported (15). Furthermore, the majority of tracheoesophageal fistulae are observed in the neck (near the first–second thoracic vertebrae) (1, 7, 11, 16). In children with multiple anomalies and respiratory symptoms, such as our patient, tracheoesophageal fistula (a tracheal deformity) is a possible complication. In addition, if symptoms such as pneumonia, the patient should be examined by bronchoscopy and esophagography in the prone position as soon as possible. Although it is difficult, it may lead to early diagnosis. Sudden respiratory failure during replacement of the tracheostomy cannula should be cautioned, as it suggests that the cannula has moved into the esophagus via the fistula.

In conclusion, we described a case of Gross E esophageal atresia that was discovered on the basis of sudden ventilatory insufficiency during cannula replacement as a complication of CHARGE syndrome.

CONFLICT OF INTERESTS-DISCLOSURE

The authors have no conflicts of interest directly relevant to the content of this article.

REFERENCE LIST

1. Brookes JT, Smith MC, Smith RJ, Bauman NM, Manaligod JM, Sandler AD : H-type congenital tracheoesophageal fistula : University Of Iowa experience 1985 to 2005. *Annals of Otolaryngology, Rhinology & Laryngology* 116 : 363-368, 2007
2. Ishimaru Y, Hatanaka M, Otani Y : H-Type Tracheoesophageal Fistula(Gross E Esophageal Atresia) Complicated With Wiskott-Aldrich Syndrome. *J Japanese Society of Pediatric Surgery* 43 : 53-57, 2007
3. Sanlaville D, Verloes A : CHARGE syndrome : an update. *European Journal of Human Genetics* 15 : 389-399, 2007
4. Hsu P, Ma A, Wilson M, Williams G, Curotta J, Munns CF, Mehr S : CHARGE syndrome : a review. *J paediatrics and child health* 50 : 504-511, 2014
5. Blake KD, Alexandra SH : Gastrointestinal and feeding difficulties in CHARGE syndrome : A review from head-to-toe. *American Journal of Medical Genetics Part C : Seminars in Medical Genetics* 175 : 4, 2017
6. Piastra M, Briganti V, Luca E, De Carolis MP, Domenico P, Conti G, Stival E, Tempera A, Calisti A, Serio P : Recurrent tracheoesophageal fistula and respiratory failure : the role of early airway endoscopic approach. *European Journal of Pediatric Surgery* 23 : 153-156, 2013
7. Basheer F, Jalil J, Shafique M, Hasnain MR : H-TYPE TRACHEOESOPHAGEAL FISTULA IN A CHILD WITH DYSMORPHISM : VATER OR NOT?. *PAFMJ* 67 : 875-78, 2017
8. Taghavi K, Tanny SP, Hawley A, Brooks JA, Hutson JM, Teague WJ, King SK, Nightingale M : H-type congenital tracheoesophageal fistula : Insights from 70 years of The Royal Children's Hospital experience. *J Pediatric Surgery* 56 : 686-691, 2021
9. Karnak İ, Şenocak ME, Hiçsönmez A, Büyükpamukçu N : The diagnosis and treatment of H-type tracheoesophageal fistula. *J pediatric surgery* 32 : 1670-1674, 1997
10. Suen HC : Congenital H-type tracheoesophageal fistula in adults. *J thoracic disease* 10 : S1905, 2018
11. Aygun D, Emre S, Nepesov S, Tekant G, Cokugras H, Camcıoglu Y : Presentation of H-type tracheoesophageal fistula in two adolescents : delayed diagnosis. *Pediatr Neonatol* 58 : 187-8, 2017
12. Haight C : Congenital tracheoesophageal fistula without esophageal atresia. *J Thoracic Surgery* 17 : 600-612, 1948
13. Kovesi T, Rubin S : Long-term complications of congenital esophageal atresia and/or tracheoesophageal fistula. *Chest* 126 : 915-925, 2004
14. Suzuki T, Masuda M, Mori T, Hirai Y, Sanada Y, Chiba M, Sumiya N. A : technique using a rectus abdominis muscle flap in the treatment of adult congenital tracheoesophageal fistulas. *J pediatric surgery* 38 : 1112-3, 2003
15. Khemakhem R, Riazulhaq M, Cherbini M : H-Type Tracheoesophageal Fistula in New Born. How to Avoid Delay in Diagnosis. *SM J Pediatr Surg* 2 : 1020, 2016
16. Blanco-Rodriguez G, Penchyna-Grub J, Trujillo-Ponce A, Nava-Ocampo AA : Preoperative catheterization of H-type tracheoesophageal fistula to facilitate its localization and surgical correction. *European journal of pediatric surgery* 16 : 14-7, 2006