

CASE REPORT

Bowen disease on the dorsum of the foot associated with human papillomavirus type 16

Kazutoshi Murao, Kanako Yamasaki, Hirokazu Agawa, Miyo Nakajima, Maiko Iwasaka, and Yoshiaki Kubo

Department of Dermatology, Tokushima University Graduate School of BioMedical Science, Tokushima, Japan

Abstract : A 94 years old Japanese female was presented to our hospital with a skin lesion on her left foot. A physical examination found a markedly hyperkeratotic reddish-brown plaque, measuring 3 cm in diameter. A biopsy specimen showed prominent papillomatosis, hyperkeratosis, and atypical keratinocytes throughout the epidermis. Individual cell keratinization, multinucleated keratinocytes, and many keratinocytes with clear cytoplasm were seen. We excised the lesion, and the skin grafting was used for covering the skin defect. We investigated whether human papillomavirus (HPV) was present in the lesion, and HPV 16 DNA was detected using the polymerase chain reaction. Immunohistochemical analysis showed several HPV-positive cells in the upper epidermis. In addition, the tumor cells showed strong and diffuse expression of p16^{INK4a}. Bowen disease (BD) is an intraepidermal squamous cell carcinoma. The precise pathogenesis of BD is unclear, but it involves various factors. HPV infection is one of these factors and is a well-known cause of BD of the genitalia and fingers. It has been shown that some BD lesions occurring at other locations are also associated with HPV. Dysregulation of the Rb/p16^{INK4a} pathway is considered to play an important role in HPV-induced BD, but the precise mechanism remains to be elucidated. *J. Med. Invest.* 69:152-154, February, 2022

Keywords : Bowen disease, human papillomavirus, p16^{INK4a}

INTRODUCTION

Human papillomavirus (HPV) is an important causative agent for cervical cancer, and most cervical cancers are caused by persistent mucous high-risk HPV infection. HPV 16 is the most frequently detected type. HPV also causes for another cancers, such as oropharyngeal, anal, penile, and skin. Bowen disease (BD) is squamous cell carcinoma *in situ*, and has been known to be associated with HPV infection especially cases involving on the external genitalia and fingers. In addition, it has been shown that some BD cases on the other locations are linked to the HPV infection.

Herein, we report a case of BD on the dorsum of the foot. We investigated whether HPV was present using the polymerase chain reaction (PCR), and HPV type 16 DNA was detected in the lesion.

CASE REPORT

A 94 years old, Japanese, otherwise healthy, female presented to our department with a skin tumor on the foot, which had been present for 2 years. She had no relevant medical history, and not taken any medications. A physical examination revealed a well-defined, markedly hyperkeratotic reddish-brown plaque, measuring 3 cm in diameter, on the dorsum of her left foot (Fig. 1a). A histopathological examination demonstrated prominent papillomatosis, parakeratotic hyperkeratosis, and acanthosis with atypical keratinocytes (Fig. 1b). The atypical keratinocytes lay in complete disorder, and keratinization of individual cell and

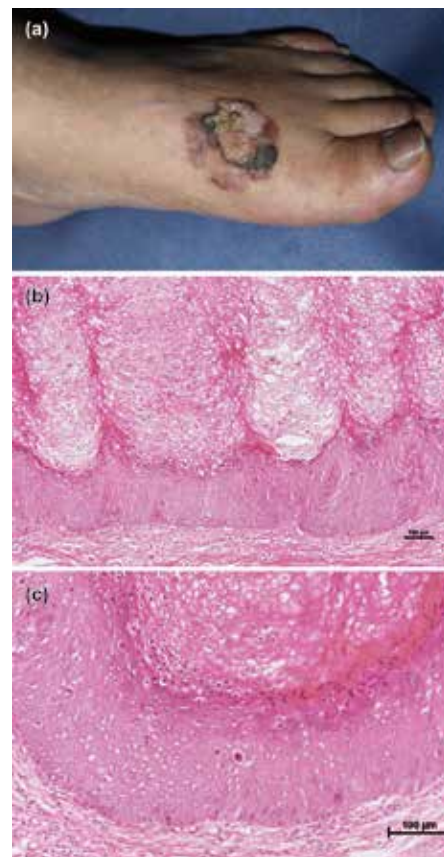


Figure 1. Clinicopathological findings (a) A reddish-brown plaque with marked hyperkeratosis was seen on the dorsum of the left foot. (b) Prominent papillomatosis, hyperkeratosis, and acanthosis with atypical keratinocytes were observed (hematoxylin and eosin staining; scale bar, 100 μ m). (c) Atypical keratinocytes, individual cell keratinization, and vacuolated keratinocytes were seen (hematoxylin and eosin staining; scale bar, 100 μ m).

Received for publication November 17, 2021; accepted March 4, 2022.

Address correspondence and reprint requests to Kazutoshi Murao, Department of Dermatology, Tokushima University Graduate School of BioMedical Science, 3-15-18 Kuramoto-cho, Tokushima City, Tokushima 770-8503, Japan and Fax: +81-886-32-0434.

multinucleated keratinocytes were seen. Many keratinocytes with clear cytoplasm were also observed in the horny and granular layers (Fig. 1c). There was no dermal invasion. Based on these findings, we made a diagnosis of BD. We excised the lesion, and the skin grafting was used for covering the skin defect. At one postoperative year, the lesion had not recurred.

We examined the lesion for HPV DNA using the PCR. After isolating DNA from frozen tumor tissue using the QIAamp DNA mini kit (Qiagen, Tokyo, Japan), we performed PCR with the L1C1/L1C2 primers (L1C1 : 5'-CGTAAACGTTT-TCCCTATTTTTTT-3' and L1C2 : 5'-TACCCTAAATAC-CCTATATTG-3'), as described previously (1). The PCR product from the lesion yielded a positive band for HPV (Fig. 2a). This PCR product was purified and subjected to DNA sequencing, as described previously (1). The partial sequence of the PCR product was identical to the sequence of HPV type 16. We performed further PCR utilizing a primer set which designed to detect HPV type 16, as described previously (1), and confirmed the presence of HPV 16 DNA (Fig. 2b). We also performed PCR with two pairs of primers (primers SKF1 and R1 and SKF2 and R2) that can amplify the genomes of HPV types related to cutaneous warts since the histological examination showed prominent papillomatosis and hyperkeratosis. However, no cutaneous types of HPV DNA were detected in the lesion (not shown).

Next, immunohistochemical analysis was performed to detect HPV (clone K1H8 ; 1:50 dilution ; DAKO, Japan) and p16^{INK4a} (clone G175-405 ; 1:25 dilution ; PharMingen, USA), as de-

scribed previously (1). There were several HPV-positive cells in the lesion (Fig. 3a), and the tumor cells showed strong and diffuse p16^{INK4a} staining (Fig. 3b).

DISCUSSION

HPV is a small, double-stranded, non-enveloped DNA virus, which infects various epithelial tissues, including the mucosae of the genitals and upper respiratory tract, and the epidermis. At present, more than 120 different types of HPV have been isolated, which can be grouped roughly into mucous and skin types depending on the tissue they infect. The mucous types of HPV can be further categorized into high- and low-risk groups on the basis of their malignant potential. High-risk types of HPV, e.g., 16, 18, 31, 33, 35, and 58, are etiologically associated with malignant lesions, most notably with cervical cancer. In addition to cervical cancer, high-risk types of HPV are linked to other cancers, such as oropharyngeal cancer and anal cancer. It is also generally accepted that cases of BD involving the genitalia or fingers are associated with HPV, and HPV 16 and 33 are the most frequently detected type of HPV.

BD is a squamous cell carcinoma *in situ*, and manifests as a well-demarcated, slowly enlarging scaly erythematous plaque. Histologically, the epidermis shows acanthosis with full-thickness keratinocyte atypia. Multinucleated keratinocytes and atypical individual cell keratinization are often present. BD

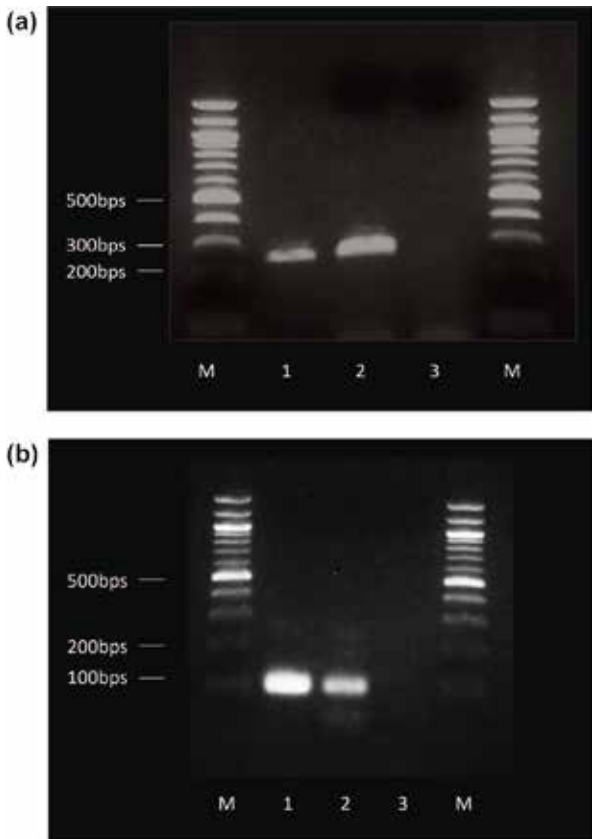


Figure 2. Detection of HPV DNA using PCR (a) Detection of HPV DNA using L1C1/L1C2 primers. (b) Detection of HPV DNA using HPV16F/16R primers. Lane M : 100-bp ladder marker ; 1 : positive control ; 2 : DNA isolated from the lesion ; 3 : negative control.

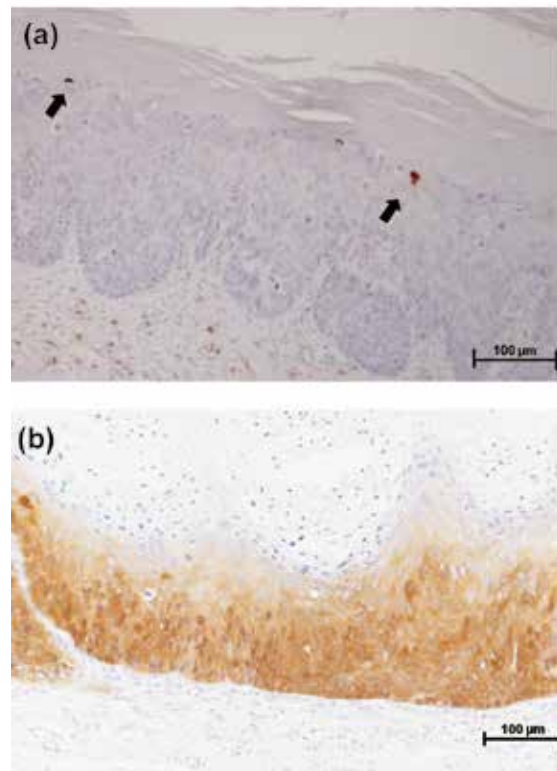


Figure 3. Immunohistochemical staining results (a) The immunohistochemical staining of HPV is shown. There were HPV positive cells in the lesion (arrow ; scale bar, 100 μm). (b) The immunohistochemical staining of p16^{INK4a} is shown. Tumor cells showed nuclear and cytoplasmic expression of p16^{INK4a} (scale bar, 100 μm).

lesions grow slowly, and transition to invasive squamous cell carcinoma occurs in a small percentage of cases. Although the precise pathogenesis of BD is unclear, various factors are suggested to be involved in the development of the disease, including ultraviolet light ; chronic exposure to arsenic ; immunosuppression ; and infection with mucous types of HPV, especially infection of the genitalia or fingers. HPV 16 and 33 are the most commonly detected types of HPV in BD lesions. In addition, although rare, it has been shown that some BD cases involving sites other than the external genitalia and fingers are also related to mucous types of HPV. Our previous study showed that 8.3% cases of extragenital BD were associated with HPV (2). But positive rate of HPV in extragenital BD are different among previous studies, presumably due to differences in the patient populations and the sensitivity of the HPV assays. There are no common sites among HPV-associated BD occurring other than external genitalia and fingers.

The mucous types of HPV usually reside in genital lesions, and it is unclear how they are transmitted to the extragenital sites. As for BD of the fingers, a previous report suggests that HPV may be transferred from genital lesions to the fingers by patients themselves (3). Therefore, it has been speculated that the self-inoculation of HPV from the external genitalia to another region may occur via the fingers.

The main mechanism underlying the tumorigenesis induced by HPV is the transforming activity of the viral E6 and E7 oncoproteins. The E6 interferes with the p53 protein whereas the E7 inactivates the Rb protein. Inactivation of the Rb protein induces the upregulation of p16^{INK4a} tumor suppressor gene protein expression via a negative feedback mechanism. In contrast, p16^{INK4a} is present at very low concentrations in normal cells. Therefore, p16^{INK4a} overexpression is considered as an indicator of HPV infection in several types of cancer, particularly cervical and oropharyngeal cancers (4). HPV infection-associated BD also involves p16^{INK4a} overexpression, as was observed in our case. However, it has been shown that most BD lesions, regardless of their HPV infection status, overexpress p16^{INK4a} (5). Our previous study also revealed similar results. Strong and diffuse p16^{INK4a} staining were observed in 103 of 133 BD lesions (73.6%), whereas HPV DNA was only detected in 12% of cases (2). It is uncertain whether these findings were obtained because BD is associated with high-risk types of HPV that cannot be detected by current methodologies or whether p16^{INK4a} overexpression

mechanisms other than HPV infection exist in BD. However, contrary to the case for cervical cancer, it seems that p16^{INK4a} overexpression is not a good indicator of HPV involvement in BD.

In conclusion, we reported a case of HPV 16-associated BD of the foot. Although such cases are rare, some BD lesions that arise at sites other than the genitalia and fingers are linked to HPV infection. Dysregulation of the Rb/p16^{INK4a} pathway is crucial for the pathogenesis of HPV-associated cancers, but the precise mechanism underlying the development of BD remains to be elucidated.

CONFLICT OF INTEREST

None declared.

REFERENCES

1. Murao K, Kubo Y, Takiwaki H, Arase S, Matsumoto K : Bowen's disease on the sole : p16^{INK4a} overexpression associated with human papillomavirus type 16. *Br J Dermatol* 152 : 170-173, 2005
2. Murao K, Yoshioka R, Kubo Y : Human papillomavirus infection in Bowen disease : Negative p53 expression, not p16^{INK4a} overexpression, is correlated with human papillomavirus-associated Bowen disease. *J Dermatol*, 41 : 878-884, 2014
3. Forslund O, Nordin P, Andersson K, Stenquist B, Hansson BG : DNA analysis indicates patient-specific human papillomavirus type 16 strains in Bowen's disease on fingers and in archival samples from genital dysplasia. *Br J Dermatol* 136 : 678-682, 1997
4. Sano T, Oyama T, Kashiwabara K, Fukuda T, Nakajima T : Expression status of p16 protein is associated with human papillomavirus oncogenic potential in cervical and genital lesions. *Am J Pathol* 153 : 1741-1748, 1998
5. Švajdler Jr M, Mezencev R, Kašpírková J, Kacerovská D, Kazakov DV, Ondič O, Michal M : Human papillomavirus infection and p16 expression in the immunocompetent patients with extragenital/extraungual Bowen's disease. *Am J Dermatopathol* 38 : 751-757, 2016