

# Changes in Choroidal Component Ratio and Circulation After Coffee Intake in Healthy Subjects

Daisuke Nagasato,<sup>1-3</sup> Yoshinori Mitamura,<sup>2</sup> Mariko Egawa,<sup>2</sup> Fumiko Muraio,<sup>2</sup> Toshihiko Nagasawa,<sup>1,2</sup> Natsumi Komori,<sup>1</sup> Shozo Sonoda,<sup>4</sup> Taiji Sakamoto,<sup>4</sup> and Hitoshi Tabuchi<sup>1-3</sup>

<sup>1</sup>Department of Ophthalmology, Saneikai Tsukazaki Hospital, Himeji, Japan

<sup>2</sup>Department of Ophthalmology, Institute of Biomedical Sciences, Tokushima University Graduate School, Tokushima, Japan

<sup>3</sup>Department of Technology and Design Thinking for Medicine, Hiroshima University Graduate School, Hiroshima, Japan

<sup>4</sup>Department of Ophthalmology, Kagoshima University Graduate School of Medical and Dental Sciences, Kagoshima, Japan

Correspondence: Yoshinori Mitamura, Department of Ophthalmology, Institute of Biomedical Sciences, Tokushima University Graduate School, 3-18-15 Kuramoto, Tokushima 770-8503, Japan; [ymitaymitaymita@yahoo.co.jp](mailto:ymitaymitaymita@yahoo.co.jp).

DN and YM contributed equally to the work presented here and should therefore be regarded as equivalent authors.

**Received:** October 3, 2020

**Accepted:** February 23, 2021

**Published:** March 18, 2021

Citation: Nagasato D, Mitamura Y, Egawa M, et al. Changes in choroidal component ratio and circulation after coffee intake in healthy subjects. *Invest Ophthalmol Vis Sci.* 2021;62(3):27. <https://doi.org/10.1167/iovs.62.3.27>

**PURPOSE.** The effects of coffee intake on the ratio of stromal and luminal components in the choroid and the underlying mechanism remain unclear. This prospective cross-sectional study aimed to explore how coffee intake affects the choroidal component ratio and circulation.

**METHODS.** Forty-nine right eyes of healthy adult volunteers were evaluated as the coffee intake group. Thirty-two right eyes of healthy volunteers served as the control group. The participants consumed 185 mL of coffee or water, respectively, and the systemic hemodynamics, enhanced-depth imaging optical coherence tomographic (EDI-OCT) images, and foveal mean blur rate (MBR), an indicator of blood flow velocity, were recorded at baseline and after coffee or water intake. The EDI-OCT images were binarized using ImageJ software, and subfoveal choroidal thickness (SCT) and whole, luminal, and stromal choroidal areas were calculated.

**RESULTS.** In the coffee intake group, significant decreases in SCT and luminal area peaked at 60 minutes after intake (both  $P < 0.001$ ), whereas a significant increase in MBR peaked at 30 minutes ( $P < 0.001$ ). No significant stromal area fluctuations were observed. SCT and luminal area fluctuations exhibited a significant positive correlation ( $r = 0.978$ ,  $P < 0.001$ ). Significant negative correlations of luminal area fluctuations with MBR fluctuations were observed by stepwise regression analysis ( $r = -0.220$ ,  $P < 0.001$ ). The control group exhibited no significant fluctuations.

**CONCLUSIONS.** Coffee-induced choroidal thinning may result mainly from a reduction in the choroidal vessel lumen, and this vessel lumen reduction correlated with an increased choroidal blood flow velocity after coffee intake. These coffee-induced changes in choroidal component ratio and circulation should be considered when evaluating choroids.

**Keywords:** choroidal structure, choroidal circulation, coffee

Caffeine is rapidly absorbed after ingestion, with a time to maximum blood concentration of 30 to 120 minutes.<sup>1</sup> Caffeine has various physiological effects, including central nervous system stimulation, increased blood pressure, and decreased heart rate (HR).<sup>2-5</sup> In the eye, caffeine intake causes decreases in blood flow velocity in the optic nerve head and retina.<sup>6,7</sup> With regard to retrobulbar hemodynamics, caffeine induces an increase in vascular resistance.<sup>8</sup> More than 70% of the ocular blood flow circulates in the choroid, and the autoregulatory nature of choroidal circulation ensures a constant choroidal blood flow despite changes in the dynamics of systemic circulation.<sup>9,10</sup>

Recent advances in optical coherence tomography (OCT) equipment and imaging methods have enabled non-invasive choroidal evaluations. Furthermore, Sonoda et al.<sup>11</sup> reported a method in which choroidal structure can be analyzed

using binarized enhanced-depth imaging OCT (EDI-OCT). This method enables analysis of the component ratios of the choroid, stromal and luminal areas, rather than a mere evaluation of choroidal thickness alone. By using this method, we revealed novel information about physiological changes in the choroid, such as structural changes due to aging, exercise, water intake, and diurnal variation.<sup>11-15</sup> We have also reported changes in the choroidal component ratio due to various retinochoroidal diseases and associations of the choroidal component ratio with treatment effects and prognosis.<sup>16-23</sup>

Although significant thinning of the choroid at 4 hours after coffee or caffeine intake has been described,<sup>24,25</sup> the detailed underlying mechanism remains unclear. The potential effects of coffee intake on the choroidal component ratio are also not well understood. However, the importance



of changes in the choroidal component ratio with regard to their associations with treatment effects and prognosis has been highlighted in actual clinical settings as described above.<sup>16–23</sup> We hypothesized that coffee intake may affect the choroidal component ratio when evaluating choroids in patients. In this study, therefore, we analyzed the choroidal component ratio using binarized EDI-OCT images to confirm whether or not coffee intake would influence the ratio of stromal and luminal components. We also measured the choroidal blood flow velocity to examine whether or not fluctuations in the choroidal component ratio and circulation would be correlated with fluctuations in systemic hemodynamics. In this study, we used coffee instead of pure caffeine (e.g., capsules) because we assumed that patients would consume coffee rather than caffeine before receiving routine medical care, and preliminary data indicated no differences in changes of the choroidal and systemic parameters between coffee and caffeine capsule intakes (data not shown).

## METHODS

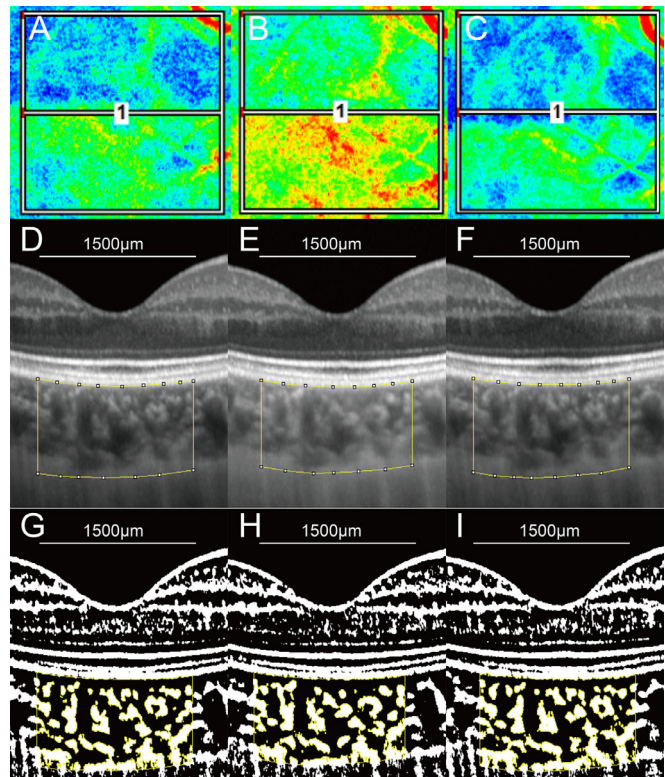
### Participants

Approval for this prospective, cross-sectional study was obtained from the ethics committee of Tsukazaki and Tokushima University Hospitals. The study protocol is compliant with the tenets of the Declaration of Helsinki. This study was also registered in the UMIN Clinical Trials Registry (registration number: R000033144). The participants were healthy adult volunteers who provided signed informed consent after receiving an explanation of the study protocol.

The coffee intake group included the right eyes of 49 participants. The control group included the right eyes of 32 participants who had been selected from the participants in the coffee intake group. To account for the effect of caffeine washout, control testing was conducted at intervals of 7 days or more after the coffee intake test. The study exclusion criteria included a high degree of myopia, defined as a spherical equivalent of  $-6.0$  diopters or less or an axial length of  $26.0$  mm or more; ocular diseases, such as retinal disease or glaucoma; and/or a history of previous ocular surgery, smoking, or systemic diseases such as diabetes and hypertension.

### Ocular and Systemic Examinations

Coffee and water intakes were conducted according to a previous report.<sup>24</sup> The participants were instructed to refrain from alcohol and caffeine consumption for 24 hours before the test and to refrain from exercise for 3 hours before the test. After resting for 10 minutes, the baseline ocular and systemic examinations were performed. The systolic blood pressure (SBP), diastolic blood pressure (DBP), and HR were measured on the right arm using a commercial sphygmomanometer (BP222; Tanita, Tokyo, Japan). The intraocular pressure (IOP) in the right eye was measured using an iCare TA01i tonometer (iCare, Helsinki, Finland). The mean arterial pressure (MAP) and mean ocular perfusion pressure (MOPP) were calculated using the equations  $MAP = DBP + 1/3(SBP - DBP)$  and  $MOPP = 2/3 MAP - IOP$ , respectively. The choroid was imaged in EDI mode using a Spectralis OCT2 (Heidelberg Engineering, Heidelberg, Germany), and the choroidal blood flow velocity was measured using laser



**FIGURE 1.** Two-dimensional color maps of the MBR measured using LSFG, EDI-OCT imaging, and converted binary images of a healthy 23-year-old man consuming 185 mL of canned coffee (148 mg caffeine). (A–C) LSFG images at baseline (A) and at 60 minutes (B) and 300 minutes (C) after coffee intake. A false-color composite map at a rectangle ( $5^\circ \times 5^\circ$ ) around the macula was created using the LSFG software. Rapid and slow blood flow areas are indicated as red and blue areas, respectively. The average MBR was 7.5 (arbitrary units) at the baseline; it increased to 12.8 at 60 minutes after coffee intake and then decreased to 8.2 at 300 minutes after intake. (D–F) EDI-OCT images at baseline (D) and at 60 minutes (E) and 300 minutes (F) after coffee intake. On white-on-black EDI-OCT images, the lumen is depicted as black with a low signal, and the stroma is depicted as white. (G–I) Converted binary images of the EDI-OCT images shown in panel D (G), panel E (H), and panel F (I). The choroidal thickness decreased slightly at 60 minutes after coffee intake relative to the baseline and then increased at 300 minutes. Note that the luminal area was constricted at 60 minutes relative to the baseline but was re-expanded at 300 minutes.

speckle flowgraphy (LSFG) (LSFG-NAVI; Softcare Co., Ltd., Fukuoka, Japan).

After obtaining the baseline data, the participants in the coffee intake group orally ingested 185 mL of canned coffee (containing 148 mg caffeine), and participants in the control group ingested 185 mL of water. The participants were instructed to avoid vigorous exercise during the test to eliminate the effects of exercise on the test results.<sup>13</sup> The same tests conducted at baseline were then performed after the participants rested for 10 minutes in the same order at 5, 30, 60, 120, 180, 240, and 300 minutes after ingestion of the coffee or water. All tests were conducted between 12:00 PM and 6:00 PM to minimize the influence of diurnal variations in the choroidal component ratio.<sup>14</sup> The participants in both groups fasted for 3 hours before the start of the examination. The participants refrained from consuming caffeinated food and beverages and consumed

TABLE 1. Clinical Characteristics of the Coffee Intake and Control Groups

	Coffee Intake Group	Control Group	P
Number of eyes, <i>n</i>	49	32	
Age (y), mean ± SD (range)	30.3 ± 4.9 (21–39)	30.6 ± 4.5 (23–38)	0.828*
Sex (female/male), <i>n</i>	30/19	17/15	0.498†
Spherical equivalent (D), mean ± SD (range)	−3.02 ± 2.12 (−5.88 to 0.32)	−2.64 ± 2.02 (−5.66 to 0.32)	0.425*
Axial length (mm), mean ± SD (range)	24.65 ± 1.09 (22.18–25.98)	24.51 ± 1.08 (22.18–25.98)	0.581*
Subfoveal choroidal thickness (µm), mean ± SD (range)	325.2 ± 51.1 (249–480)	323.0 ± 50.2 (258–413)	0.856*
Corneal thickness (µm), mean ± SD (range)	534.59 ± 30.67 (480–575)	530.03 ± 28.66 (493–569)	0.509*

\* Unpaired *t*-test.

† Fisher's exact test.

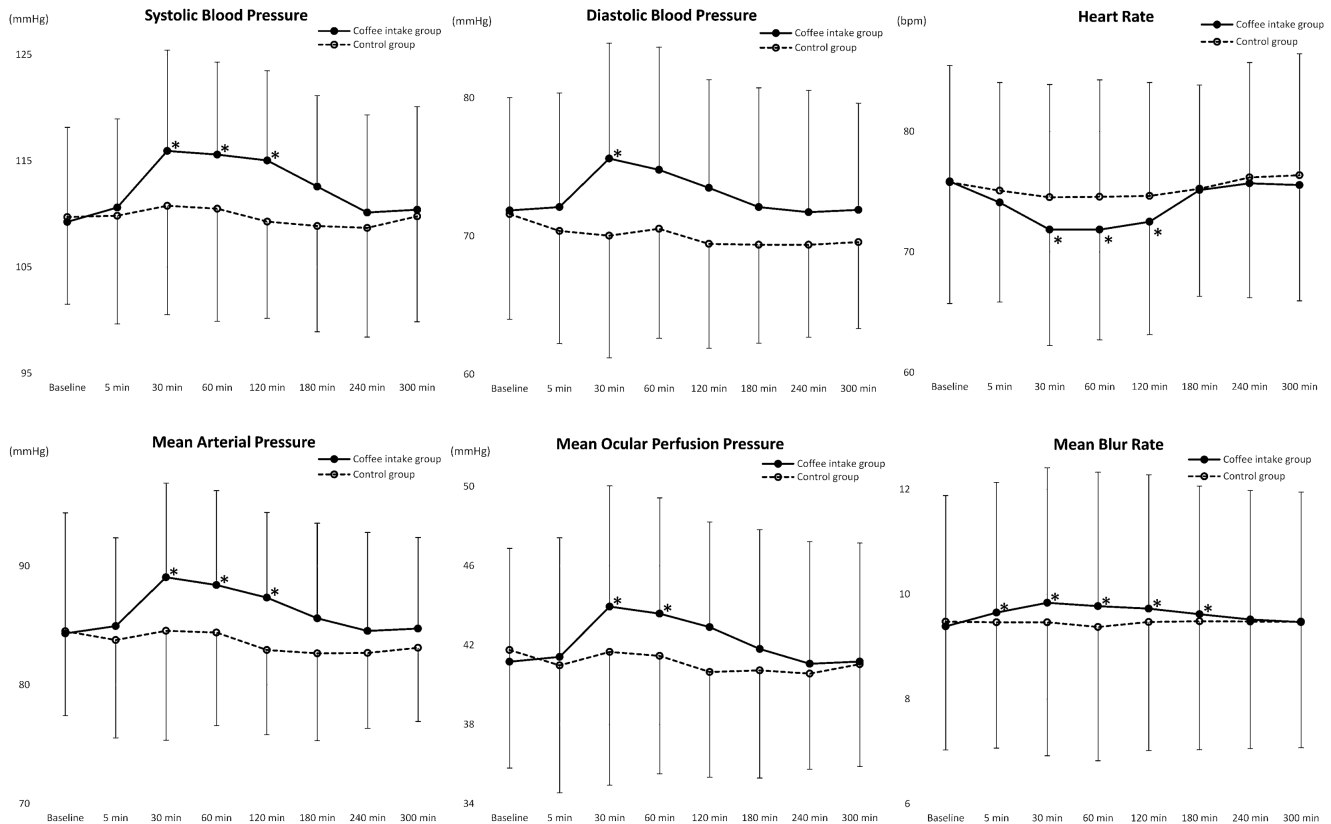


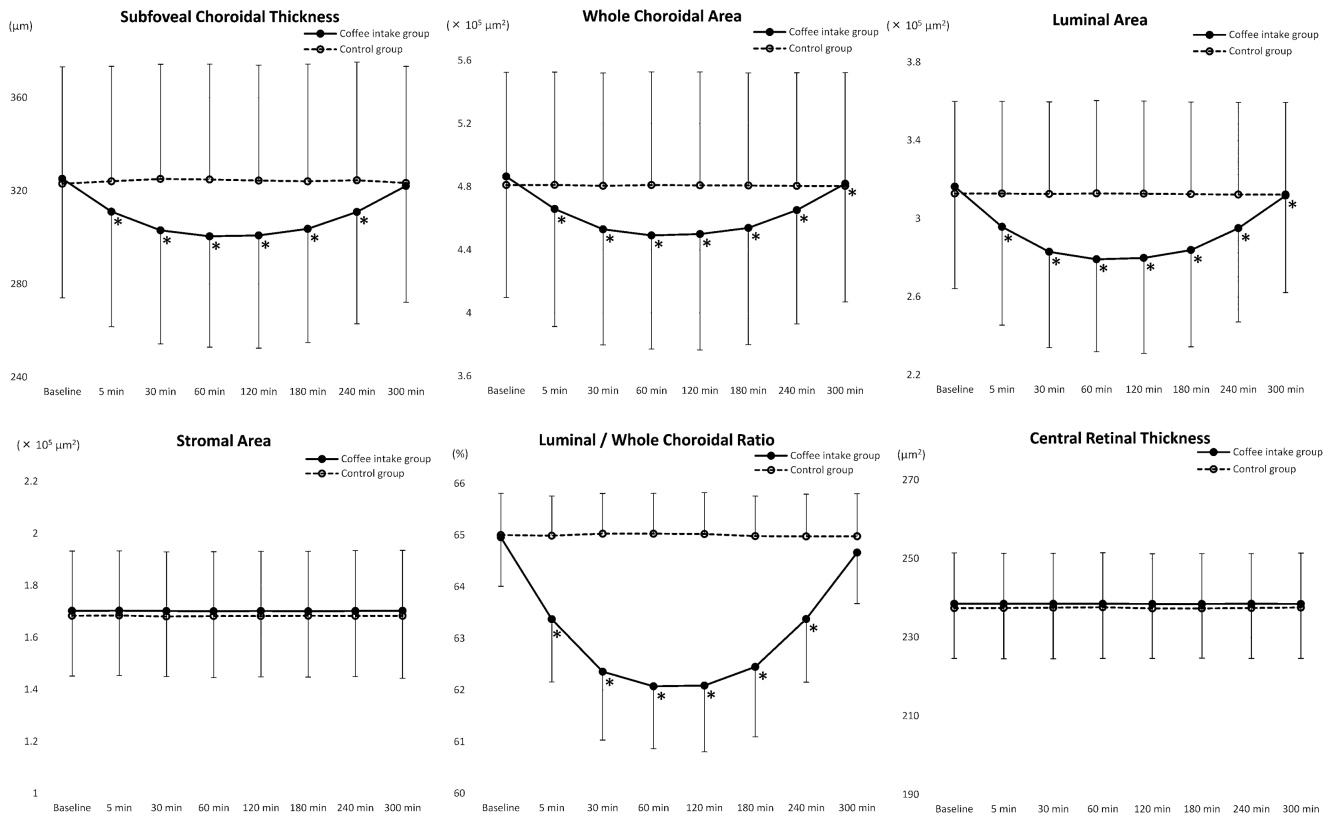
FIGURE 2. Changes in hemodynamic parameters in all eyes of the coffee intake group (49 eyes) and the control (water intake) group (32 eyes). In all 49 eyes of the coffee intake group (*closed circle*), significant fluctuations were observed in the SBP, DBP, MAP, mean ocular perfusion pressure, HR, and MBR (all  $P < 0.001$ ). Compared with the baseline, SBP and MAP were significantly increased at 30, 60, and 120 minutes (all  $P < 0.036$ ); mean ocular perfusion pressure was significantly increased at 30 and 60 minutes (both  $P < 0.011$ ); and DBP was significantly increased at 30 minutes ( $P = 0.001$ ) after coffee intake. HR was significantly decreased at 30, 60, and 120 minutes after coffee intake relative to the baseline (all  $P < 0.013$ ). These values returned to the baseline levels at 300 minutes (all  $P = 1.000$ ). The MBR was significantly increased at 5, 30, 60, 120, and 180 minutes (all  $P < 0.019$ ) and returned to the baseline level at 240 minutes ( $P = 0.667$ ). In the control group (*open circle*), there were no significant fluctuations in any of the hemodynamic parameters during the observation period (all  $P > 0.117$ ). Asterisks indicate significant changes from the baseline. Error bars indicate standard deviation.

only the minimum necessary foods and beverages during the examination.<sup>24</sup> The participants in the control group were assessed in exactly the same fashion as the coffee intake group.

Evaluation of Choroidal Blood Flow

The mean blur rate (MBR) was measured as an index of relative blood flow velocity using LSFSG. As the foveal

area contains few retinal blood vessels, the foveal MBR is largely considered to be derived from the blood flow in the choroidal vessels.<sup>13,15</sup> Accordingly, we measured the MBR in a square area of the fovea ( $5^\circ \times 5^\circ$ ) to evaluate the choroidal blood flow velocity.<sup>26</sup> Here,  $5^\circ$  of the measurement range of blood flow velocity in LSFSG is equivalent to 1500 µm of the analytical range of the EDI-OCT image in an emmetropic eye.<sup>27</sup> The MBR was measured three times at each time point, and the mean value of the three measurements was used for the analysis.



**FIGURE 3.** Changes in OCT parameters in all eyes of the coffee intake group (49 eyes) and the control (water intake) group (32 eyes). In all 49 eyes of the coffee intake group (closed circle), significant fluctuations were observed in the SCT, whole choroidal area, luminal area, and L/W ratio (all  $P < 0.001$ ). The SCT, whole choroidal area, luminal area, and L/W ratio were significantly decreased at 5, 30, 60, 120, 180, and 240 minutes after coffee intake (all  $P < 0.001$ ). These decreases peaked at 60 minutes, and the values increased thereafter. The SCT and L/W ratio returned to the baseline levels at 300 minutes (both  $P > 0.073$ ). The whole choroidal area and luminal area returned to values near the baseline at 300 minutes, although these values still differed significantly from the baseline (both  $P < 0.027$ ). There were no significant fluctuations in the stromal area and CRT (both  $P > 0.910$ ). In the control group (open circle), there were no significant fluctuations in any of the OCT parameters during the observation period (all  $P > 0.194$ ). Asterisks indicate significant changes from the baseline. Error bars indicate standard deviation.

### Enhanced-Depth Imaging Optical Coherence Tomography

Horizontal scans were performed in a 30° range centered on the fovea with the eye-tracking system and follow-up mode turned on. The examiner entered each radius of corneal curvature into the Eye Data of the OCT device and focused firmly on the fundus with the focus knob to accurately correct the length on the OCT images by axial length and corneal refraction. The subfoveal choroidal thickness (SCT) and central retinal thickness (CRT) were measured by two independent examiners who were blinded to the clinical data, using the caliper function of the OCT device. The measurements of both examiners were then averaged, and this value was used in the analysis.

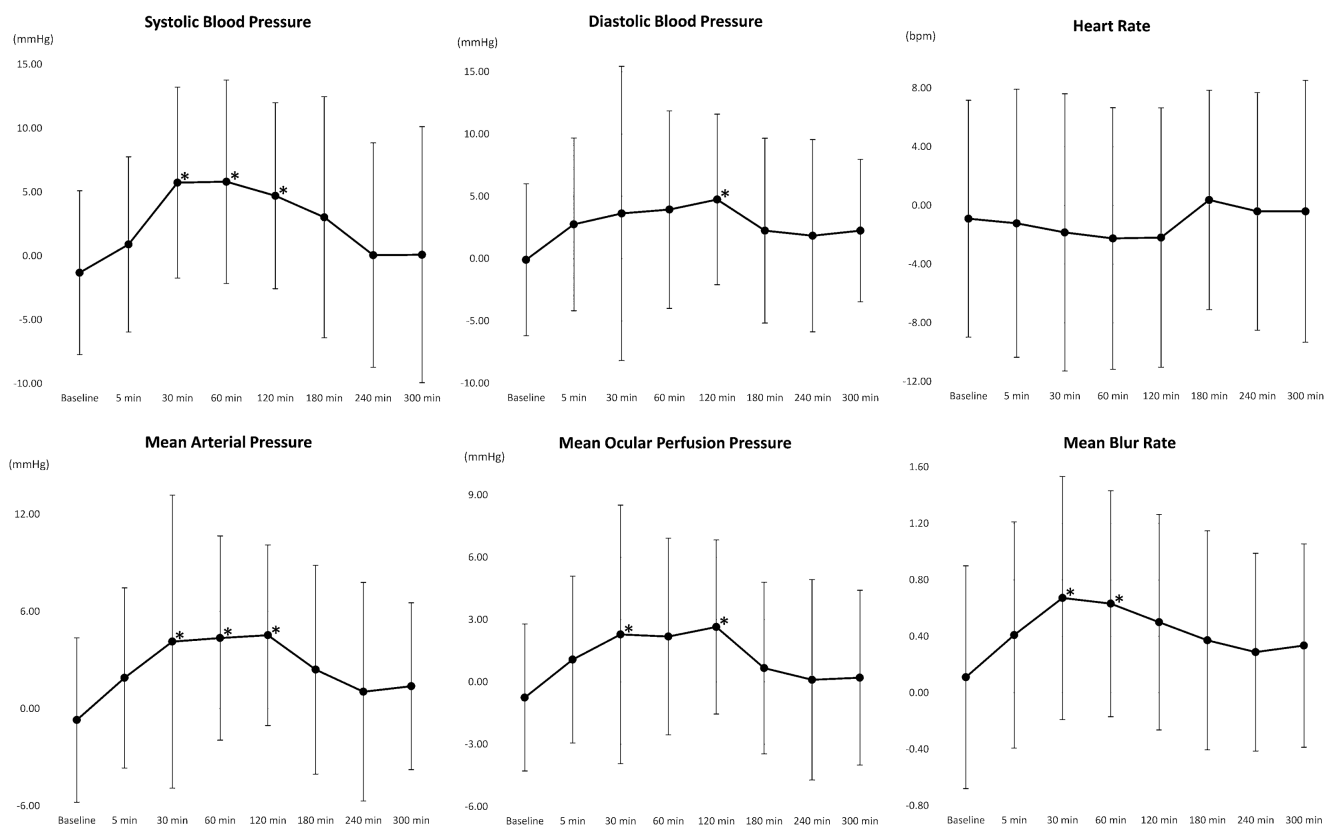
### Choroidal Component Ratio Analysis

We applied a method of choroidal component ratio analysis that has shown a high degree of reproducibility in our previous studies.<sup>11-16</sup> Details of the analysis using binarization techniques have been described elsewhere.<sup>11,13,14</sup> We used open-access ImageJ 1.47 (National Institutes of Health, Bethesda, MD, USA) to open each white-on-black EDI-OCT

image file. We then analyzed each image using the Niblack method, which is a binarization processing method built into the software (Fig. 1). Next, the Oval Selection Tool in ImageJ was used to select three low-luminance regions in the central part of a blood vessel with a diameter > 100  $\mu\text{m}$  in the outer choroid. The average reflectance of the three regions was calculated, and the obtained value was used as the minimum image luminance to reduce the noise contained in the captured image. Using the region of interest manager, the choroidal area centered on the fovea with a width of 1500  $\mu\text{m}$  between Bruch's membrane, and the chorioscleral border was set manually as an analysis range.

Grayscale EDI-OCT images display 256 shade gradations, which were automatically replaced with two white-black gradations using the Niblack Auto Local Threshold function. Consequently, the areas of white and black pixels were regarded as the stromal and luminal areas, respectively. Data describing the relationship between pixel spacing on the image and the actual distance on the fundus (scaling  $x$  and scaling  $z$ ) were retrieved from the Spectralis OCT2 and input into ImageJ, which automatically calculated the stromal and luminal areas. This allowed us to determine the whole choroidal, luminal, and stromal areas and to calcu-





**FIGURE 4.** Differences in hemodynamic parameters between the coffee intake test and the control (water intake) test of the same subjects (32 eyes). The line graphs show the mean and standard deviation of the coffee test value minus the control test value at each time point in the 32 eyes that underwent both the coffee intake test and the control test. Paired testing at each time point between the two tests was performed. Compared with the respective values of the control test, significant increases in the coffee intake test were observed in SBP and MAP at 30, 60, and 120 minutes (all  $P < 0.024$ ); in the MBR at 30 and 60 minutes (both  $P < 0.016$ ); in MOPP at 30 and 120 minutes (both  $P < 0.046$ ); and in DBP at 120 minutes ( $P = 0.026$ ). There were no significant differences at any time points in HR (all  $P > 0.790$ ). Asterisks indicate significant differences between the coffee intake test and the control test.

late the ratio of the luminal area to the whole choroidal area (L/W ratio). These choroidal parameters were measured three times per EDI-OCT image, and the mean value of the three measurements was used in the analysis. All clinical findings were masked during the choroidal component ratio analysis.

**Statistical Analysis**

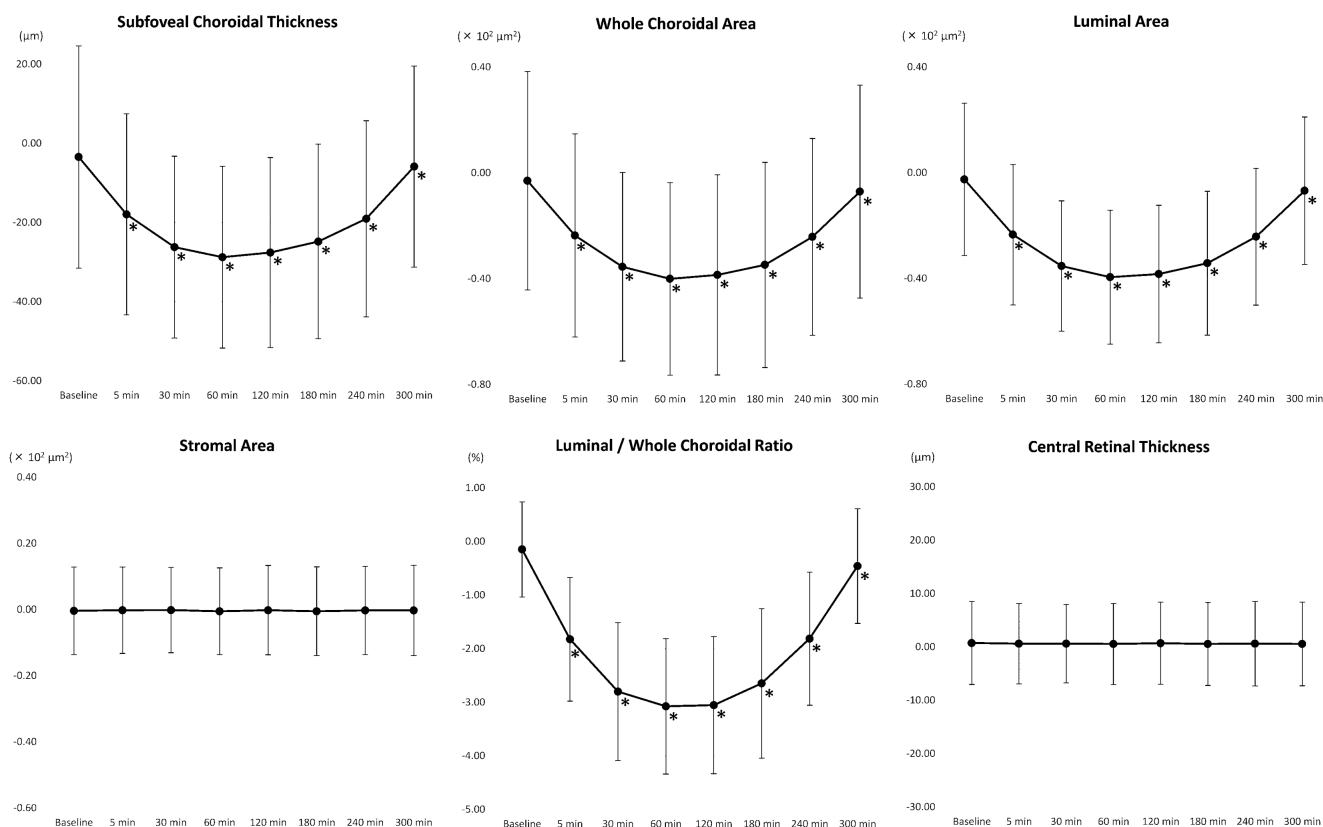
The unpaired *t*-test and Fisher’s exact test were used to compare differences in clinical characteristics between the coffee and water intake groups. Fluctuations in ocular and systemic parameters after coffee or water intake were analyzed using a repeated-measures ANOVA and corrected using the Greenhouse–Geisser method. When significant fluctuations were detected, the Bonferroni test was used to determine whether there were significant differences between the values at baseline and at each time point after coffee or water intake.

Correlation coefficients were calculated to examine correlations among fluctuations in the systemic parameters, IOP, MBR, and EDI-OCT parameters within a participant over repeated observations. The correlation coefficients within participants and corresponding *P* values were calculated using general linear model analyses. In the general linear model, the EDI-OCT parameters were set as dependent vari-

ables, and one variable from the systemic parameter or MBR and the subject were set as independent variables. The correlation coefficients between participants were calculated using the sum of the squares of the values of systemic parameters or MBR and the residual sum of squares. Furthermore, to identify factors with independent effects on the dependent variable, we constructed a multivariate model in which the independent variables were entered by the stepwise method.

For 32 eyes that underwent both coffee intake and control tests, repeated-measures ANOVAs were performed to evaluate the time series transition of each parameter in each intervention (coffee or control). A repeated-measures analysis model was constructed in which each parameter was a dependent variable, and time (baseline, 5, 30, 60, 120, 180, 240, or 300 minutes), interventions, and their interaction terms were within-subject factors. Paired testing was made at each time point between interventions in terms of changes. Each test was corrected for test multiplicity by the Holm method.

For this study, SPSS Statistics 23 (IBM, Armonk, NY, USA) was used to conduct all the statistical analyses.  $P < 0.05$  was considered statistically significant. A correlation coefficient  $< 0.2$  was considered to indicate a lack of correlation, even if the *P* value met the cutoff for significance as advocated by Guilford.<sup>28</sup>



**FIGURE 5.** Differences in OCT parameters between the coffee intake test and the control (water intake) test of the same subjects (32 eyes). The line graphs show the mean and standard deviation of the coffee test value minus the control test value at each time point in the 32 eyes that underwent both the coffee intake test and the control test. Paired testing at each time point between two tests was performed. Compared with the control test, significant decreases in the coffee intake test were observed in SCT, whole choroidal area, luminal area, and L/W ratio at all time points after the baseline (all  $P < 0.050$ ). There were no significant differences at any time point in the stromal area and central retinal thickness (all  $P > 0.794$ ). Asterisks indicate significant differences between the coffee intake test and the control test.

**RESULTS**

No significant differences in the clinical characteristics were observed between the coffee intake and control groups (all  $P > 0.050$ ) (Table 1).

**Fluctuations in Hemodynamic Parameters and Intraocular Pressure**

Significant fluctuations in the SBP, DBP, MAP, MOPP, MBR, and HR were observed in all 49 eyes of the coffee intake group over time (all  $P < 0.001$ ). Compared with the respective baseline values, significant increases were observed in the MBR at 5, 30, 60, 120, and 180 minutes (all  $P < 0.019$ ); in SBP and MAP, at 30, 60, and 120 minutes (all  $P < 0.036$ ); in MOPP, at 30 and 60 minutes (both  $P < 0.011$ ); and in DBP, at 30 minutes ( $P = 0.001$ ) (Fig. 2). The HR decreased significantly at 30, 60, and 120 minutes relative to the baseline (all  $P < 0.013$ ). All of these hemodynamic parameters returned to the baseline levels at 300 minutes (all  $P = 1.000$ ). There was no significant fluctuation in IOP ( $P = 0.895$ ). In the control group, no significant fluctuations in any hemodynamic parameters or IOP were observed (all  $P > 0.117$ ).

**Fluctuations in OCT Parameters**

In all 49 eyes of the coffee intake group, the SCT, whole choroidal area, luminal area, and L/W ratio fluctuated signifi-

cantly (all  $P < 0.001$ ), and all of these values had decreased significantly at 5, 30, 60, 120, 180, and 240 minutes relative to the baseline (all  $P < 0.001$ ) (Fig. 3). Additionally, these values exhibited peak decreases at 60 minutes and began to increase thereafter. At 300 minutes, the SCT and L/W ratio had returned to the baseline level (both  $P > 0.073$ ), whereas the whole choroidal area and luminal area had nearly recovered but remained significantly different from the baseline values ( $P = 0.026$  and  $P = 0.015$ , respectively). No significant fluctuations were observed in the stromal area and CRT ( $P = 0.911$  and  $P = 0.998$ , respectively). In the control group, no significant fluctuations were observed in any of the OCT parameters (all  $P > 0.194$ ).

**Comparison Between Coffee Intake Test and Control Test**

For 32 eyes that underwent both tests, significant increases after coffee intake were observed in SBP and MAP at 30, 60, and 120 minutes (all  $P < 0.024$ ); in the MBR, at 30 and 60 minutes (both  $P < 0.016$ ); in MOPP, at 30 and 120 minutes (both  $P < 0.046$ ); and in DBP, at 120 minutes ( $P = 0.026$ ) (Fig. 4) compared with the respective values of the control test. Significant decreases after coffee intake were observed in SCT, whole choroidal area, luminal area, and L/W ratio at all time points after the baseline (all  $P < 0.050$ ) (Fig. 5).

**TABLE 2.** Correlations of Fluctuations in Choroidal Parameters with Fluctuations in Systemic Parameters, IOP, and MBR in the Coffee Intake Group

Choroidal Parameter	IOP	MBR	DBP	SBP	Heart Rate	MOPP	MAP	SCT
SCT	<i>r</i> = -0.058 <i>P</i> = 0.280	<b><i>r</i> = -0.287</b> <b><i>P</i> &lt; 0.001</b>	<b><i>r</i> = -0.228</b> <b><i>P</i> &lt; 0.001</b>	<b><i>r</i> = -0.336</b> <b><i>P</i> &lt; 0.001</b>	<b><i>r</i> = 0.265</b> <b><i>P</i> &lt; 0.001</b>	<b><i>r</i> = -0.277</b> <b><i>P</i> &lt; 0.001</b>	<b><i>r</i> = -0.313</b> <b><i>P</i> &lt; 0.001</b>	—
(stepwise regression)	—	( <b><i>r</i> = -0.218</b> ) ( <b><i>P</i> &lt; 0.001</b> )	—	( <b><i>r</i> = -0.281</b> ) ( <b><i>P</i> &lt; 0.001</b> )	( <b><i>r</i> = 0.186</b> ) ( <b><i>P</i> &lt; 0.001</b> )	—	—	—
Whole choroidal area	<i>r</i> = -0.051 <i>P</i> = 0.346	<b><i>r</i> = -0.301</b> <b><i>P</i> &lt; 0.001</b>	<b><i>r</i> = -0.236</b> <b><i>P</i> &lt; 0.001</b>	<b><i>r</i> = -0.372</b> <b><i>P</i> &lt; 0.001</b>	<b><i>r</i> = 0.275</b> <b><i>P</i> &lt; 0.001</b>	<b><i>r</i> = -0.301</b> <b><i>P</i> &lt; 0.001</b>	<b><i>r</i> = -0.335</b> <b><i>P</i> &lt; 0.001</b>	—
(stepwise regression)	—	( <b><i>r</i> = -0.229</b> ) ( <b><i>P</i> &lt; 0.001</b> )	—	( <b><i>r</i> = -0.319</b> ) ( <b><i>P</i> &lt; 0.001</b> )	( <b><i>r</i> = 0.193</b> ) ( <b><i>P</i> &lt; 0.001</b> )	—	—	—
Luminal area	<i>r</i> = -0.055 <i>P</i> = 0.311	<b><i>r</i> = -0.294</b> <b><i>P</i> &lt; 0.001</b>	<b><i>r</i> = -0.236</b> <b><i>P</i> &lt; 0.001</b>	<b><i>r</i> = -0.374</b> <b><i>P</i> &lt; 0.001</b>	<b><i>r</i> = 0.278</b> <b><i>P</i> &lt; 0.001</b>	<b><i>r</i> = -0.300</b> <b><i>P</i> &lt; 0.001</b>	<b><i>r</i> = -0.336</b> <b><i>P</i> &lt; 0.001</b>	<b><i>r</i> = 0.978</b> <b><i>P</i> &lt; 0.001</b>
(stepwise regression)	—	( <b><i>r</i> = -0.220</b> ) ( <b><i>P</i> &lt; 0.001</b> )	—	( <b><i>r</i> = -0.322</b> ) ( <b><i>P</i> &lt; 0.001</b> )	( <b><i>r</i> = 0.197</b> ) ( <b><i>P</i> &lt; 0.001</b> )	—	—	—
Stromal area	<i>r</i> = 0.048 <i>P</i> = 0.376	<i>r</i> = -0.140 <i>P</i> = 0.009	<i>r</i> = -0.039 <i>P</i> = 0.474	<i>r</i> = -0.006 <i>P</i> = 0.913	<i>r</i> = -0.014 <i>P</i> = 0.797	<i>r</i> = -0.049 <i>P</i> = 0.361	<i>r</i> = -0.031 <i>P</i> = 0.567	<i>r</i> = 0.132 <i>P</i> = 0.014
(stepwise regression)	—	( <b><i>r</i> = -0.140</b> ) ( <b><i>P</i> = 0.009</b> )	—	—	—	—	—	—
L/W ratio	<i>r</i> = -0.065 <i>P</i> = 0.234	<b><i>r</i> = -0.271</b> <b><i>P</i> &lt; 0.001</b>	<b><i>r</i> = -0.231</b> <b><i>P</i> &lt; 0.001</b>	<b><i>r</i> = -0.388</b> <b><i>P</i> &lt; 0.001</b>	<b><i>r</i> = 0.285</b> <b><i>P</i> &lt; 0.001</b>	<b><i>r</i> = -0.299</b> <b><i>P</i> &lt; 0.001</b>	<b><i>r</i> = -0.339</b> <b><i>P</i> &lt; 0.001</b>	<b><i>r</i> = 0.952</b> <b><i>P</i> &lt; 0.001</b>
(stepwise regression)	—	( <b><i>r</i> = -0.192</b> ) ( <b><i>P</i> &lt; 0.001</b> )	—	( <b><i>r</i> = -0.338</b> ) ( <b><i>P</i> &lt; 0.001</b> )	( <b><i>r</i> = 0.206</b> ) ( <b><i>P</i> &lt; 0.001</b> )	—	—	—

Bold indicates significant correlation. A correlation coefficient < 0.2 was considered to indicate a lack of correlation even if the *P* value met the cutoff for significance. In the stepwise multiple regression analyses, the fluctuation in one variable from the choroidal parameters was set as the dependent variable, and fluctuations in the IOP, MBR, DBP, SBP, HR, MOPP, and MAP were set as independent variables.

### Correlation of Fluctuations in Choroidal Parameters With Those in Hemodynamic Parameters

In all 49 eyes of the coffee intake group, fluctuations in the SCT, whole choroidal area, luminal area, and L/W ratio exhibited significant negative correlations with fluctuations in the SBP, DBP, MAP, MOPP, and MBR (all  $|r| > 0.227$ ,  $P < 0.001$ ) and significant positive correlations with fluctuations in the HR (all  $|r| > 0.264$ ,  $P < 0.001$ ) (Table 2). However, fluctuations in the stromal area were not significantly correlated with fluctuations in the systemic hemodynamic parameters (all  $|r| < 0.050$ ,  $P > 0.360$ ). Stepwise regression analyses showed that fluctuations in the SCT, whole choroidal area, and luminal area exhibited significant correlations with fluctuations in the SBP and MBR (all  $|r| > 0.217$ ,  $P < 0.001$ ) and that fluctuations in the L/W ratio exhibited significant correlations with fluctuations in the SBP and HR (both  $|r| > 0.205$ ,  $P < 0.001$ ).

Fluctuations in the SCT were significantly correlated with fluctuations in the luminal area ( $r = 0.978$ ,  $P < 0.001$ ) and L/W ratio ( $r = 0.952$ ,  $P < 0.001$ ) (Table 2). Although the correlation between fluctuations in the SCT and fluctuations in the stromal area was significant, the correlation coefficient was low, and this correlation was not considered relevant ( $r = 0.132$ ,  $P = 0.014$ ).

In the control group, there were no significant correlations between the fluctuations in any of the choroidal parameters and any of the hemodynamic parameters and IOP (all  $|r| < 0.147$ ,  $P > 0.057$ ).

### DISCUSSION

In this study, we demonstrated that coffee intake was associated with significant decreases in SCT, whole choroidal area, luminal area, and L/W ratio and significant increases in SBP, DBP, MAP, MOPP, and MBR. However, no significant fluctuations were observed in the stromal area, CRT, or IOP. Although previous studies have described choroidal

thinning after coffee intake,<sup>24,25,29</sup> to our knowledge ours is the first to report that coffee intake causes contraction of the choroidal lumen but has no effect on the stroma. In our study, the choroidal lumen began to contract 5 minutes after coffee intake, and the consequent choroidal thinning peaked at approximately 60 minutes. The choroidal thinning persisted for 240 to 300 minutes. These data suggest that clinicians should consider the effects of caffeine on the choroidal component ratio for at least 240 to 300 minutes after coffee intake when analyzing the choroidal component ratio in patients with retinochoroidal diseases. The maximum variation in the L/W ratio due to coffee intake in this study was 2.9%, which was larger than the variations due to diurnal variation (1.0%)<sup>14</sup> and consumption of 1000 mL of water (1.5%).<sup>15</sup> Because the reported post-treatment variabilities of the L/W ratio were 4.1% after anti-vascular endothelial growth factor therapy for retinal vein occlusion<sup>21</sup> and 7.0% after steroid therapy for Vogt-Koyanagi-Harada disease,<sup>17</sup> the effect of coffee on the L/W ratio seems to be non-negligible in clinical practice.

The mechanism by which caffeine intake can alter the choroidal luminal area is not fully understood. Caffeine is believed to inhibit adenosine-mediated vasodilatation by binding to adenosine receptors and to induce vasoconstriction.<sup>30</sup> Terai et al.<sup>31</sup> measured the retinal vessel diameter using a retinal vessel analyzer and reported significant constriction at 1 hour after caffeine intake. The degree of retinal vessel constriction is greater after coffee intake than that caused by the autoregulation of retinal circulation, which is associated with an increase in the systemic blood pressure caused by isometric exercise.<sup>32</sup> This observation led Terai et al. to infer that, in addition to the autoregulatory mechanism of retinal circulation, the direct pharmacological action of caffeine is also associated with caffeine-induced retinal vasoconstriction. It is highly possible that choroidal vessel constriction could be attributed to the direct pharmacological action of caffeine.

The constriction of choroidal vessels could be attributed to the indirect pharmacological action of caffeine. The media of the choroidal artery wall contain smooth muscle,

the contraction of which is controlled by the sympathetic and parasympathetic nerves,<sup>33,34</sup> mainly via  $\alpha$ 1A-adrenergic receptors distributed on the choroid.<sup>35</sup> Caffeine is known to promote adrenaline secretion, which may constrict the choroidal vessels. Moreover, Robertson et al.<sup>36</sup> reported that the intake of 250 mg caffeine significantly increased the plasma renin activity by 57%. Possibly, the increased plasma renin activity induced by caffeine intake triggered the renin-angiotensin-aldosterone system to initiate systemic vasoconstriction (including the choroidal vessels).

Hemodynamic autoregulation is a unique mechanism by which a constant blood flow is maintained in a tissue despite changes in perfusion pressure. Choroidal circulation was not traditionally thought to be autoregulated, despite the known existence of autoregulation in retinal circulation. Kiel et al.<sup>37,38</sup> investigated the choroidal blood flow using laser Doppler flowmetry and concluded that the choroid exhibits autoregulatory properties that maintain a constant choroidal blood flow even when the ocular perfusion pressure is fluctuating, particularly in response to a sudden mechanical change in systemic blood pressure. We can infer that the caffeine-induced constriction of the choroidal vessels may have triggered autoregulation of the choroid, and this autoregulation may have increased the choroidal blood flow velocity to maintain a constant blood flow. Although this inference is not definitive because we did not measure the choroidal blood flow itself, it seems to be consistent with our study data, which revealed a significant negative correlation between fluctuations in the luminal area due to coffee intake and MBR fluctuations.

Okuno et al.<sup>6</sup> measured the blood flow velocity at the midpoint between the optic nerve head and macula and reported that the chorioretinal blood flow velocity decreased by 6% at 60 minutes after the administration of 100 mg caffeine. In contrast, we evaluated the choroidal blood flow velocity using measurements obtained in the foveal area, which does not contain large, medium, or capillary retinal vessels.<sup>39</sup> As the blood flow measurements by Okuno et al. included the influence of retinal capillary circulation, they may not reflect solely on choroidal circulation. Lotfi et al.<sup>7</sup> measured leukocyte velocity in the retinal capillary of the macula using the blue field simulation technique and reported that this parameter decreased by 13% after the ingestion of 200 mg caffeine. This result suggests that caffeine intake decreases the retinal capillary blood flow velocity. Therefore, the decrease in blood flow velocity reported by Okuno et al. may have been strongly influenced by a decrease in retinal circulation due to the measurement location.

The present study had some limitations. First, we included only a small number of participants. Second, although the binarization technique-based analysis was performed automatically, the choroidal area to be analyzed was set manually. Third, analysis of a larger choroidal area is necessary to determine whether similar changes occur across the entire choroid. Fourth, the examiner entered each radius of corneal curvature into the Eye Data of the OCT device and focused firmly on the fundus to correct the length on the OCT images by axial length and corneal refraction. However, diurnal fluctuations of the corneal refraction and refocusing at each measurement time point might introduce slight measurement errors. Finally, our study participants were limited to healthy young adults. A previous report claimed that changes in the SCT due to coffee intake were correlated with age, suggesting that an age-related decrease

in metabolism would explain the more pronounced effects of coffee in elderly individuals.<sup>24</sup>

In conclusion, the whole choroidal area, luminal choroidal area, and proportion of the lumen in the whole choroid exhibited significant decreases after coffee intake, whereas no significant changes were observed in the stromal area. The fluctuations in choroidal thickness were significantly correlated with those in the luminal area, but not with those in the stromal area. These results suggest that choroidal thinning after coffee intake is caused by a reduction in the choroidal luminal area. Moreover, we showed an increase in choroidal blood flow velocity after coffee intake that was correlated with the reduction in the luminal area. These findings suggest that clinicians should consider the physiological changes in choroidal component ratio and circulation associated with coffee intake prior to assessing these parameters.

### Acknowledgments

Supported in part by Grant-in-Aid 19K09951 from the Ministry of Education, Science, Sports, and Culture, Japan (YM).

Disclosure: **D. Nagasato**, None; **Y. Mitamura**, None; **M. Egawa**, None; **F. Murao**, None; **T. Nagasawa**, None; **N. Komori**, None; **S. Sonoda**, None; **T. Sakamoto**, None; **H. Tabuchi**, None

### References

- Blanchard J, Sawers SJ. The absolute bioavailability of caffeine in man. *Eur J Clin Pharmacol.* 1983;24(1):93–98.
- Whitsett TL, Manion CV, Christensen HD. Cardiovascular effects of coffee and caffeine. *Am J Cardiol.* 1984;53(7):918–922.
- Smits P, Thien T, Van't Laar A. The cardiovascular effects of regular and decaffeinated coffee. *Br J Clin Pharmacol.* 1985;19(6):852–854.
- Casiglia E, Bongiovi S, Paleari CD, et al. Haemodynamic effects of coffee and caffeine in normal volunteers: a placebo-controlled clinical study. *J Intern Med.* 1991;229(6):501–504.
- Mathew RJ, Wilson WH. Caffeine induced changes in cerebral circulation. *Stroke.* 1985;16(5):814–817.
- Okuno T, Sugiyama T, Tominaga M, et al. Effects of caffeine on microcirculation of the human ocular fundus. *Jpn J Ophthalmol.* 2002;46(2):170–176.
- Lotfi K, Grunwald JE. The effect of caffeine on the human macular circulation. *Invest Ophthalmol Vis Sci.* 1991;32(12):3028–3032.
- Ozkan B, Yüksel N, Anik Y, Altintas O, Demirci A, Çağlar Y. The effect of caffeine on retrolubar hemodynamics. *Curr Eye Res.* 2008;33(9):804–809.
- Lovasik JV, Kergoat H, Riva CE, Petrig BL, Geiser M. Choroidal blood flow during exercise-induced changes in the ocular perfusion pressure. *Invest Ophthalmol Vis Sci.* 2003;44(5):2126–2132.
- Polska E, Simader C, Weigert G, et al. Regulation of choroidal blood flow during combined changes in intraocular pressure and arterial blood pressure. *Invest Ophthalmol Vis Sci.* 2007;48(8):3768–3774.
- Sonoda S, Sakamoto T, Yamashita T, et al. Choroidal structure in normal eyes and after photodynamic therapy determined by binarization of optical coherence tomographic images. *Invest Ophthalmol Vis Sci.* 2014;55(6):3893–3899.
- Sonoda S, Sakamoto T, Yamashita T, et al. Luminal and stromal areas of choroid determined by binarization method of



- optical coherence tomographic images. *Am J Ophthalmol*. 2015;159(6):1123–1131.
13. Kinoshita T, Mori J, Okuda N, et al. Effects of exercise on the structure and circulation of choroid in normal eyes. *PLoS One*. 2016;11(12):e0168336.
  14. Kinoshita T, Mitamura Y, Shinomiya K, et al. Diurnal variations in luminal and stromal areas of choroid in normal eyes. *Br J Ophthalmol*. 2017;101(3):360–364.
  15. Nagasato D, Mitamura Y, Egawa M, et al. Changes of choroidal structure and circulation after water drinking test in normal eyes. *Graefes Arch Clin Exp Ophthalmol*. 2019;257(11):2391–2399.
  16. Egawa M, Mitamura Y, Akaiwa K, et al. Changes of choroidal structure after corticosteroid treatment in eyes with Vogt-Koyanagi-Harada disease. *Br J Ophthalmol*. 2016;100(12):1646–1650.
  17. Kawano H, Sonoda S, Yamashita T, Maruko I, Iida T, Sakamoto T. Relative changes in luminal and stromal areas of choroid determined by binarization of EDI-OCT images in eyes with Vogt-Koyanagi-Harada disease after treatment. *Graefes Arch Clin Exp Ophthalmol*. 2016;254(3):421–426.
  18. Egawa M, Mitamura Y, Sano H, et al. Changes of choroidal structure after treatment for primary intraocular lymphoma: retrospective, observational case series. *BMC Ophthalmol*. 2015;15:136.
  19. Egawa M, Mitamura Y, Niki M, et al. Correlations between choroidal structures and visual functions in eyes with retinitis pigmentosa. *Retina*. 2019;39(12):2399–2409.
  20. Sonoda S, Sakamoto T, Kuroiwa N, et al. Structural changes of inner and outer choroid in central serous chorioretinopathy determined by optical coherence tomography. *PLoS One*. 2016;11(6):e0157190.
  21. Mitamura Y, Enkhmaa T, Sano H, et al. Changes in choroidal structure following intravitreal aflibercept therapy for retinal vein occlusion [published online ahead of print July 3, 2020]. *Br J Ophthalmol*. <https://doi.org/10.1136/bjophthalmol-2020-316214>.
  22. Daizumoto E, Mitamura Y, Sano H, et al. Changes of choroidal structure after intravitreal aflibercept therapy for polypoidal choroidal vasculopathy. *Br J Ophthalmol*. 2017;101(1):56–61.
  23. Kinoshita T, Mitamura Y, Mori T, et al. Changes in choroidal structures in eyes with chronic central serous chorioretinopathy after half-dose photodynamic therapy. *PLoS One*. 2016;11(9):e0163104.
  24. Vural AD, Kara N, Sayin N, Pirhan D, Ersan HB. Choroidal thickness changes after a single administration of coffee in healthy subjects. *Retina*. 2014;34(6):1223–1228.
  25. Dervişoğulları MS, Totan Y, Yüce A, Kulak AE. Acute effects of caffeine on choroidal thickness and ocular pulse amplitude. *Cutan Ocul Toxicol*. 2016;35(4):281–286.
  26. Sugiyama T, Araie M, Riva CE, Schmetterer L, Orgul S. Use of laser speckle flowgraphy in ocular blood flow research. *Acta Ophthalmol*. 2010;88(7):723–729.
  27. Suzuki T, Terasaki H, Niwa T, Mori M, Kondo M, Miyake Y. Optical coherence tomography and focal macular electroretinogram in eyes with epiretinal membrane and macular pseudohole. *Am J Ophthalmol*. 2003;136(1):62–67.
  28. Guilford JP. *Fundamental Statistics in Psychology and Education*. New York: McGraw Hill; 1956.
  29. Zengin MO, Cinar E, Karahan E, Tuncer I, Kucukerdonmez C. The effect of caffeine on choroidal thickness in young healthy subjects. *Cutan Ocul Toxicol*. 2015;34(2):112–116.
  30. Campochiaro PA, Sen HA. Adenosine and agonists cause vasodilatation and hemorrhages. Implications of ischemic retinopathies. *Arch Ophthalmol*. 1989;107(3):412–416.
  31. Terai N, Spoerl E, Pillunat LE, Stodtmeister R. The effect of caffeine on retinal vessel diameter in young healthy subjects. *Acta Ophthalmol*. 2012;90(7):e524–e528.
  32. Blum M, Bachmann K, Wintzer D, Riemer T, Vilser W, Strobel J. Noninvasive measurement of the Bayliss effect in retinal autoregulation. *Graefes Arch Clin Exp Ophthalmol*. 1999;237(4):296–300.
  33. Bron AJ, Tripathi RC, Tripathi BJ. *Wolff's Anatomy of the Eye and Orbit*. 8th ed. London: Chapman & Hall; 1997.
  34. Nickla DL, Wallman J. The multifunctional choroid. *Prog Retin Eye Res*. 2010;29(2):144–168.
  35. Suzuki F, Taniguchi T, Nakamura S, et al. Distribution of alpha-1 adrenoceptor subtypes in RNA and protein in rabbit eyes. *Br J Pharmacol*. 2002;135(3):600–608.
  36. Robertson D, Frölich JC, Carr RK, et al. Effects of caffeine on plasma renin activity, catecholamines and blood pressure. *N Engl J Med*. 1978;298(4):181–186.
  37. Kiel JW, van Heuven WA. Ocular perfusion pressure and choroidal blood flow in the rabbit. *Invest Ophthalmol Vis Sci*. 1995;36(3):579–585.
  38. Kiel JW, Shepherd AP. Autoregulation of choroidal blood flow in the rabbit. *Invest Ophthalmol Vis Sci*. 1992;33(8):2399–2410.
  39. Iwase T, Yamamoto K, Ra E, et al. Diurnal variations in blood flow at optic nerve head and choroid in healthy eyes: diurnal variations in blood flow. *Medicine (Baltimore)*. 2015;94(6):e519.