

## Multidisciplinary treatment of skeletal muscle metastasis from lung cancer: A case of triceps muscle metastasis of lung squamous cell cancer

Keiko Haji<sup>a</sup>, Seidai Sato<sup>a</sup>, Hiroto Yoneda<sup>a</sup>, Toshihiko Nisisho<sup>b</sup>, Hiroshi Nokihara<sup>a</sup>, Yasuhiko Nishioka<sup>a,\*</sup>

<sup>a</sup> Department of Respiratory Medicine & Rheumatology, Graduate School of Biomedical Sciences, Tokushima University, Tokushima, Japan

<sup>b</sup> Department of Orthopedics, Institute of Biomedical Sciences, Tokushima University Graduate School, Tokushima, Japan

### ARTICLE INFO

#### Keywords:

Lung cancer  
Muscle metastasis  
Mass  
Paralysis  
Combined therapy

### ABSTRACT

A 62-year-old Japanese man presented a hard and painful intramuscular mass in the right upper arm during the chemotherapy for lung squamous cell carcinoma. Initially, this mass containing fluid accumulation was treated by radiotherapy and antibiotics as a muscle metastasis suspected to be complicated with local infection. However, because the swelling and pain of his right arm did not improve, he underwent a surgical debridement of the mass. These local treatments succeeded in relieving the patient's symptoms for a while. However, after temporary remission, the recurrence tumor developed the paralysis of right radial nerve and ulnar nerve in his upper arm. Despite further combined therapy including drainage, additional radiotherapy, and chemotherapy, paralysis made his performance status deteriorated. He was eventually discontinued aggressive treatment due to worsened general condition.

We herein report a case of lung cancer followed unusual course due to muscle metastasis in the triceps muscle. Because the paralysis caused by muscle metastasis can be the factor to deteriorate the performance status of patient, the combined therapy including antibiotics, debridement, radiotherapy and chemotherapy as early as possible should be considered to avoid its risk.

### Introduction

The common sites of distant metastasis in lung cancer are brain, bone, liver and adrenal gland [1–3]. On the other hand, it is known that tumors including lung cancer are less likely to metastasize to skeletal muscles [4,5]. Therefore, the clinical features of muscle metastasis have not been fully studied yet. One previous report described that the median survival of patients with skeletal muscle metastasis from non-small cell lung cancer (NSCLC) is only six months [4]. On the other hand, this report also suggested 5-year survival of these patients might be able to be prolonged if the appropriate local treatments were applied [4]. However, no effective and appropriate treatment for muscle metastasis has been established.

In this report, we present a case of muscle metastasis from lung cancer. Combined local treatments, including radiotherapy, antibiotics, and debridement, initially succeeded in relieving the patient's symptoms. However, subsequent local recurrence developed paralysis of

radial and ulnar nerves in patient, which eventually led to deteriorate his performance status.

### Case presentation

A 62-year-old man receiving nab-paclitaxel as third line chemotherapy for lung cancer presented to our hospital due to arm pain. He was diagnosed with lung squamous cell carcinoma (cT2bN0M0 Stage IIIB) one year ago. Programmed death ligand 1 immunohistochemistry showed tumor proportion score of 50%. As a first line treatment, he was treated by the chemoradiation therapy of cisplatin and Tegafur/Gimeracil/Osteracil Potassium combined with irradiation to lung primary region. A small nodule in his triceps brachii muscle had been recognized from computed tomography (CT) findings and showed increased radiotracer uptake on fluorodeoxyglucose positron emission tomography (FDG/PET)/CT scan (Fig. 1A and B). However, because it was hard to be biopsied due to its size, we planned to follow up carefully

\* Corresponding author. Department of Respiratory Medicine and Rheumatology, Graduate School of Biomedical Sciences, Tokushima University Graduate School, 3-18-15 Kuramoto-cho, Tokushima, 770-8503, Japan.

E-mail address: [yasuhiko@tokushima-u.ac.jp](mailto:yasuhiko@tokushima-u.ac.jp) (Y. Nishioka).

<https://doi.org/10.1016/j.rmcr.2021.101470>

Received 17 May 2021; Received in revised form 1 July 2021; Accepted 6 July 2021

Available online 8 July 2021

2213-0071/© 2021 The Authors.

Published by Elsevier Ltd.

This is an open access article under the CC BY-NC-ND license

(<http://creativecommons.org/licenses/by-nc-nd/4.0/>).

this nodule by the imaging findings. Two months after the chemoradiation therapy, because the lung cancer recurred in his left adrenal gland and pelvic bone, chemotherapy was changed to Pembrolizumab. Three months later, abdominal CT showed an increase in the size of left adrenal metastasis. At this point, because the size of mass in his right upper arm had also increased, we suspected it was metastasis from his known NSCLC (Fig. 1B and C). The regimen was changed to nab-paclitaxel for the purpose of disease control including the metastatic regions. After chemotherapy was changed to nab-paclitaxel, stable disease had been achieved (Fig. 1C and D). The chemotherapy with nab-paclitaxel was continued for a total of six months (total seven courses).

The pain of his upper arm was developed from three weeks before visiting. Whole-body CT scan demonstrated a large mass of  $8.0 \times 7.0 \times 10.0$  cm in his triceps brachii muscle involving low density (Fig. 1E). This result suggested the intramuscular nodule had increased its size gradually and caused pain. Furthermore, contrast-enhanced magnetic resonance imaging (MRI) showed that the thick wall of the mass enhanced with gadolinium, and that the high signal of contents in the mass on the T2-weighted images and partially high signal on the T1-weighted images (Fig. 2). His serum level of white blood cell (WBC), C-reactive protein (CRP), and lactate dehydrogenase were high (Table 1). The tumor marker of squamous cell carcinoma antigen and cytokeratin 19 fragment tended to increase (Table 1).

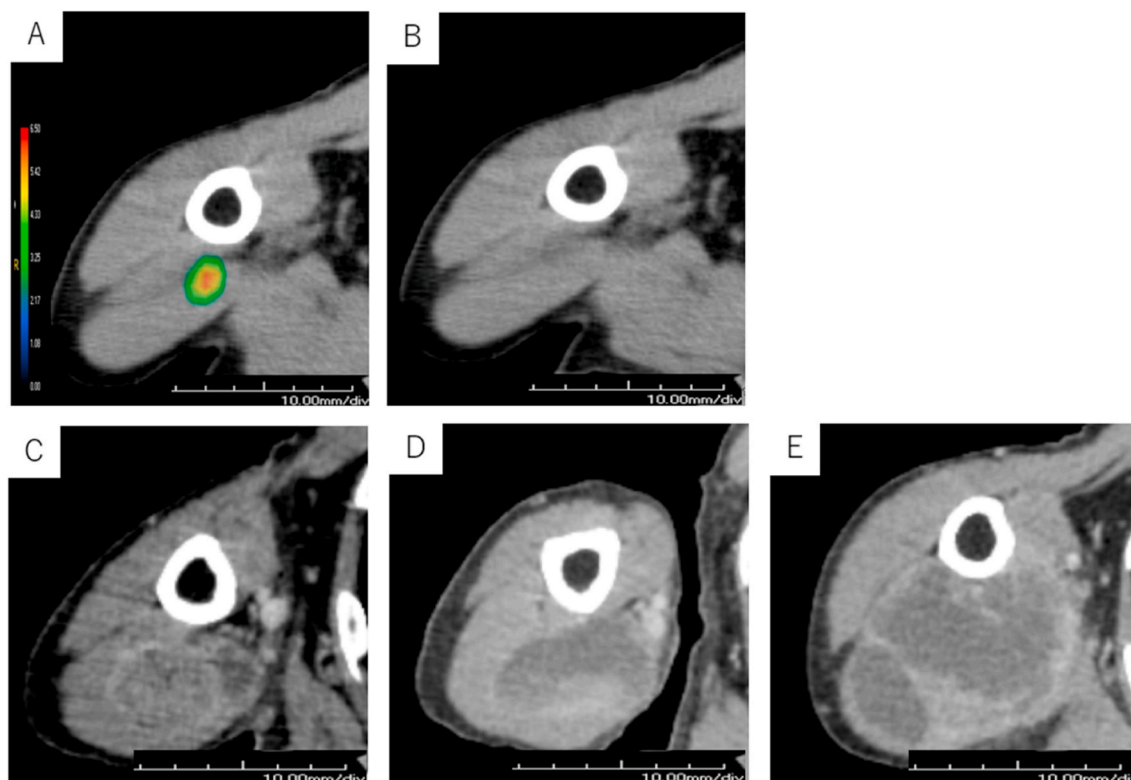
From these results, the mass in his upper arm was suspected to be a metastasis from lung squamous cell carcinoma accompanied with intratumoral infection. Antibiotic therapy with cefazolin and clindamycin was started from day one of hospitalization. The chemotherapy of nab-paclitaxel was discontinued because of sign of recurrence in muscle region. Local radiotherapy (30 Gy/10 Fr) to the mass was started from day seven of hospitalization. However, despite continued radiotherapy and antibiotic therapy, the value of CRP and WBC remained still high.

The pain in his right arm did not improve either. Therefore, on day 17 of hospitalization, he underwent a debridement of the mass. The mass contained a high proportion of neutrophil cells pathologically, however a bacterial cultivation was negative. The pathological analysis of the mass confirmed the mass was a metastasis of lung squamous cell carcinoma. After debridement of the mass, physical sign and blood test findings including WBC, CRP, and tumor markers were gradually improved. Therefore, we changed intravenous antibiotics to oral one, and he left the hospital.

One month after his discharge, as the size of mass in his right arm increased, he begun to have the symptom of abductor digiti minimi muscle weakness and the dropped hand. These symptoms suggested that the recurrent tumor caused paralysis in his radial nerve and ulnar nerve of right arm. Although the pain of his right upper arm also getting worse, it could be well managed with transdermal fentanyl patch 3 mg every 24 hours and oxycodone 5 mg as a rescue medication. Despite further combined therapy including drainage of the content of tumor, additional radiation therapy, and chemotherapy with nab-paclitaxel, his performance status had deteriorated. Because he could not continue receiving the aggressive treatment, he was transferred to hospice 20 months after the first diagnosis of lung cancer.

## Discussion

The mechanism of skeletal muscle metastasis of lung cancer has not been fully clarified yet. It may be attributed to the 'seed and soil' hypothesis explained that the outcome of metastasis was not due to chance, but certain tumor cells ('seed') have specific affinity for the milieu of certain organs ('soil') [6]. However, despite the abundant blood flow in muscle, skeletal muscle metastases from cancer are rarely encountered in clinical practice. Several theories had explained the possible factors



**Fig. 1.** A: Increased uptake in the right triceps muscle (maximum standardized uptake value (SUV) = 6.3) in fluorodeoxyglucose positron emission tomography (FDG/PET) at the first visit. B: Computed tomography (CT) imaging taken at the first visit shows a nodule measuring  $2.5 \times 1.8 \times 1.6$  cm in the right triceps muscle. C: CT imaging taken just before starting nab-paclitaxel shows a mass measuring  $2.7 \times 4.0 \times 5.4$  cm in the right triceps muscle. D: CT imaging taken after two cycles of nab-paclitaxel shows a mass measuring  $2.2 \times 4.2 \times 5.0$  cm in the right triceps muscle. E: CT imaging taken six months after starting nab-paclitaxel shows a mass measuring  $8.0 \times 7.0 \times 10.0$  cm.

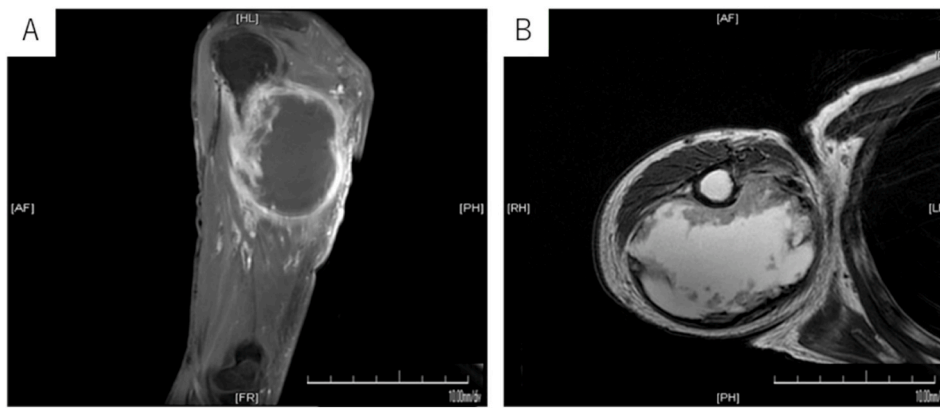


Fig. 2. Contrast-enhanced magnetic resonance imaging/T1-weighted image (A), T2-weighted images(B) after six months of starting nab-paclitaxel.

**Table 1**  
Laboratory data on admission and course of tumor marker.

Hematology		Biochemistry	
WBC	25,200/ $\mu$ L	AST	50 U/L
Neutro	90.4%	ALT	53 U/L
Lympho	3.6%	LDH	596 U/L
Mono	3.8%	T-bil	0.5 mg/dL
Eosino	1.5%	$\gamma$ -GTP	146 U/L
Baso	0.1%	CK	27 g/dL
RBC	$372 \times 10^4/\mu$ L	TP	6.7 g/dL
Hb	10.7 g/dL	Alb	3.5 g/dL
Ht	33.3%	BUN	18 mg/dL
Plt	$40.7 \times 10^4/\mu$ L	Cre	0.66 mg/dL
Coagulation		CRP	13.58 mg/dL
PT	13.3 Sec	PCT	0.22 ng/mL
APTT	36.8 Sec		
Fib	1369 mg/dL		
D-dimer	1.4 $\mu$ g/mL		
	Admission -25days	Admission + 11days	Admission + 34days
SCC	3.3 ng/mL	6.8 ng/mL	2.0 ng/mL
CYFRA	6.3 ng/mL	22.5 ng/mL	2.0 ng/mL

SCC: squamous cell carcinoma antigen, CYFRA: cytokeratin 19 fragment.

**Table 2**  
Patient's characteristics of literature search.

Site	No. cases	
	Daniel et al. <sup>[2]</sup>	Our research
Above diaphragm	53 (40.5%)	12 (21.4%)
Under diaphragm	77 (59.2%)	44 (78.6%)
Skull	0	2
Chest wall	20	2
Abdominal wall	22	24
Upper limb	33	8
Lower limb	55	20
NR	9	
Symptom	No. cases	
	Daniel et al. <sup>[2]</sup>	Our research
Pain	83	38
Mass	78	16
Paralysis	0	2
Histology	No. cases	
	Daniel et al. <sup>[2]</sup>	Our research
Adeno	48	15
Squamous	43	31
Large	4	4
NSCLC	13	4

NR: not recorded, Adeno: adenocarcinoma, Squamous: squamous cell carcinoma, Large: large cell carcinoma, NSCLC: non-small cell lung cancer.

responsible for the high resistance of muscles to cancer metastasis. One previous report suggested the hypothesis that the biomechanical damage to cancer cells arrested in the microvasculature of skeletal muscles accounts for the rapid death of many of them [7]. Another report suggested that the lactic acid produced by muscles is one of the factors for preventing tumor metastasis [8,9]. Furthermore, Stein-Werblowsky R had proposed a hypothesis that a strong immune response produced by muscle might destroy tumor emboli [10]. These factors may be related with rarity of skeletal muscle metastasis.

Clinical feature of skeletal muscle metastasis is not fully understood because of its rarity. It was reported that lung carcinoma is the most frequent primary source leading to clinically recognized soft tissue metastases, followed by renal carcinoma, and colon carcinoma [11]. Pop D et al. reviewed 114 cases in the international literature of skeletal muscle metastases from NSCLC (period: 1946–2007) [4]. We also searched the literature with similar contents published after 2008, and found 54 cases. The source of our literature search was PubMed using the search items “muscle metastases” and “lung cancer” in the period between 2008 and 2020. The summarized characteristics of these cases are described in Table 2. According to the previous literature search, the sites of lung cancer metastases were more frequent in the muscles under the diaphragm than above the diaphragm [4]. Squamous cell carcinoma was the most frequent subtype of NSCLC which caused skeletal muscle metastases [4]. The same tendency was found in our literature search (Table 2).

The pain was the most frequent symptom of muscle metastasis in both literature search. The paralysis was reported in only two cases [12, 13]. However, in both cases, the performance status of patient was deteriorated by paralysis due to muscle metastasis. In the present case, the general condition had begun to worsen since his right arm was paralyzed. As a result, the chemotherapy was discontinued. Pop D et al. reported the 5-year survival rate of patients with skeletal muscle metastasis from NSCLC was 14.4% when local treatment was applied, but 0% when only chemotherapy or supportive care was done [4]. According to these facts, the local therapies combined chemotherapy, radiotherapy and surgical therapy for muscle metastasis to avoid paralysis may be important to provide patients long-term survival.

However, in the present case, the duration of remission was only one month despite the combined therapy after the muscle metastasis started to progress rapidly. By the time the combined therapy was started, the size of the mass was already over 7 cm. On the other hand, Mogi A et al. reported a case of NSCLC with muscle metastasis of which duration of remission achieved more than four and half years [14]. In this case, the combined therapy including chemotherapy and radiotherapy to the muscle metastasis was performed soon after the diagnosis when the size of metastatic tumor was less than 4 cm [14]. Although the data accumulated so far are not conclusive enough to draw unambiguous conclusions because of few previous reports, it is likely that the aggressive diagnosis and the combined therapy to muscle metastatic lesion as early as possible may lead better prognosis.

Surov A et al. reported that 32.5% of skeletal muscle metastases of 61 cancer cases presented abscess-like intramuscular lesions with central low attenuation and rim enhancement radiologically [15]. However, only two cases were diagnosed as being accompanied with intramuscular infection by needle aspiration [15]. Bernardino V et al. also reported the muscle metastasis frequently mimics muscle abscess radiologically and clinically [16]. In the present case, although a bacterial cultivation from tumor specimen was negative, it was still difficult to deny a complication of intramuscular infection or intratumoral abscess by clinical and radiological findings. Culture tests carried out after

the start of antibiotic administration might also have affected negative results. However, because the inflammation caused by infection can cause neuropathy, even though whether the present case complicated infection or not, we believe that the combined therapy including not only radiotherapy but also antibiotics and debridement contributed to delay patient getting paralysis.

## Conclusion

We experienced a unique case of muscle metastasis from NSCLC developed paralysis of brachial nerve. When we encounter the lung cancer patients with the lesion suspected as the muscle metastasis, the aggressive diagnosis and the combined therapy including antibiotics, debridement, radiotherapy and chemotherapy should be considered as early as possible to avoid the deterioration of performance status with the paralysis.

## Declaration of competing interest

The authors declare that have no known competing financial interests or personal relationships that could have appeared to influence the work reported in this paper.

## Acknowledgements

This study received no specific grant from any funding agency in the public, commercial, or not-for-profit sectors.

## References

- [1] M.J. Schuchert, J.D. Luketich, Solitary sites of metastatic disease in non-small cell lung cancer, *Curr Treat Options in Oncol* 4 (1) (2003) 65–79.
- [2] C. Perisano, M.S. Spinelli, C. Graci, et al., Soft tissue metastases in lung cancer: a review of the literature, *Eur Rev Med Pharmacol Sci* 16 (14) (2012) 1908–1914.
- [3] P.P. McKeown, P. Conant, L.E. Auerbach, Squamous cell carcinoma of the lung: an unusual metastasis to pectoralis muscle, *The Annals of Thoracic Surgery* 61 (5) (1996) 1525–1526.
- [4] D. Pop, A.S. Nadeemy, N. Venissac, et al., Skeletal muscle metastasis from non-small cell lung cancer, *Journal of Thoracic Oncology* 4 (10) (2009) 1236–1241.
- [5] G. Mignani, D. McDonald, S. Boriani, M. Avella, L. Gaiani, M. Campanacci, Soft tissue metastasis from carcinoma, A case report. *Tumori*. 75 (6) (1989) 630–633.
- [6] I.J. Fidler, The pathogenesis of cancer metastasis: the “seed and soil” hypothesis revisited, *Nat Rev Cancer* 3 (6) (2003) 453–458.
- [7] L. Weiss, Biomechanical destruction of cancer cells in skeletal muscle: a rate-regulator for hematogenous metastasis, *Clin Exp Metast* 7 (5) (1989) 483–491.
- [8] S. Seely, Possible reasons for the high resistance of muscle to cancer, *Medical Hypotheses* 6 (2) (1980) 133–137.
- [9] M.M. LaBan, R. Nagarajan, J.C. Riutta, Paucity of muscle metastasis in otherwise widely disseminated cancer: a conundrum, *American Journal of Physical Medicine & Rehabilitation* 89 (11) (2010) 931–935.
- [10] R. Stein-Werblowsky, Skeletal muscle and tumour metastasis, *Experientia* 30 (4) (1974) 423–424.
- [11] T.A. Damron, J. Heiner, Distant soft tissue metastases: a series of 30 new patients and 91 cases from the literature, *Ann Surg Oncol* 7 (7) (2000) 526–534.
- [12] T. Oshima, H. Kuno, K. Sekiya, H. Tomita, T. Kobayashi, M. Kumamoto, A case of medial pterygoid muscle metastasis of lung cancer presenting with trismus, *Int Canc Conf J* 8 (4) (2019) 153–156.
- [13] H.K. Kahangy, A. Goodridge, Leg pain disclosing lung cancer: a case report and review of the literature, *Can J Neurol Sci* 44 (4) (2017) 465–466.
- [14] A. Mogi, T. Kosaka, E. Yamaki, H. Kuwano, Successful resection of stage iv non-small cell lung cancer with muscle metastasis as the initial manifestation: a case report, *Ann Thorac Cardiovasc Surg* 18 (5) (2012) 468–471.
- [15] A. Surov, M. Hainz, H.-J. Holzhausen, et al., Skeletal muscle metastases: primary tumours, prevalence, and radiological features, *Eur Radiol* 20 (3) (2010) 649–658.
- [16] V. Bernardino, L.S. Val-Flores, J. Lopes Dias, L. Bento, Just another abdominal pain? Psoas abscess-like metastasis in large cell lung cancer with adrenal insufficiency, *Case Reports* 2015 (jun10 1) (2015) bcr2014204496–bcr2014204496.