

## **A case report of Sotos syndrome treated with nonsurgical orthodontic technique**

**Authors:** Ryoko Shioyasono, DDS<sup>a</sup>; Kaoru Yoshinaga, DDS<sup>b</sup>; Atsushi Shioyasono, DDS, PhD<sup>c</sup>; Ayami Ito, DDS<sup>a</sup>; Keiichiro Watanabe, DDS, PhD<sup>d</sup>; Masahiro Hiasa, DDS, PhD<sup>e</sup>; Shinya Horiuchi, DDS, PhD<sup>f</sup>; Eiji Tanaka, DDS, PhD<sup>g</sup>

### **Author's affiliations and positions**

<sup>a</sup> Clinical Resident, Department of Orthodontics and Dentofacial Orthopedics, Tokushima University Hospital, Tokushima, Japan.

<sup>b</sup> Graduate Student, Department of Orthodontics and Dentofacial Orthopedics, Tokushima University Graduate School of Oral Sciences, Tokushima, Japan.

<sup>c</sup> Assistant Professor, Department of Oral and Maxillofacial Surgery, Kagawa University Hospital, Kagawa, Japan.

<sup>d</sup> Assistant Professor, Department of Orthodontics and Dentofacial Orthopedics, Institute of Biomedical Sciences, Tokushima University Graduate School, Tokushima Japan.

<sup>e</sup> Assistant Professor and Lecturer, Department of Orthodontics and Dentofacial Orthopedics, Institute of Biomedical Sciences, Tokushima University Graduate School, Tokushima, Japan.

<sup>f</sup> Assistant Professor and Lecturer, Department of Orthodontics and Dentofacial Orthopedics, Tokushima University Hospital, Tokushima, Japan.

<sup>g</sup> Professor and Chair, Department of Orthodontics and Dentofacial Orthopedics, Institute of Biomedical Sciences, Tokushima University Graduate School, Tokushima, Japan.

**Running title:** A treatment case of Sotos syndrome

All authors certify that this paper is free of conflict of interest.

### **Description of each Author's contribution to the submission**

Ryoko Shioyasono, DDS: Planning and performing orthodontic treatment; Writing and editing the manuscript.

Kaoru Yoshinaga, DDS: Performing case analyses and orthodontic treatment.

Atsushi Shioyasono, DDS, PhD: Performing case analyses; Editing the manuscript.

Ayami Ito, DDS: Performing case analyses and orthodontic treatment.

Keiichiro Watanabe, DDS, PhD: Critical review and revision of the manuscript.

Masahiro Hiasa, DDS, PhD: Critical review and revision of the manuscript.

Shinya Horiuchi, DDS, PhD: Critical review and revision of the manuscript.

Eiji Tanaka, DDS, PhD: Corresponding author; Writing and editing the manuscript.

**Correspondences:**

Eiji Tanaka, DDS, PhD

Department of Orthodontics and Dentofacial Orthopedics, Institute of Biomedical Sciences,  
Tokushima University Graduate School

3-18-15 Kuramoto-cho, Tokushima 770-8504, Japan

Tel: +81-88-6337356; Fax: +81-88 6339138

E-mail: [etanaka@tokushima-u.ac.jp](mailto:etanaka@tokushima-u.ac.jp)

## Highlights

- ▶ Sotos syndrome is categorized as overgrowth syndromes presenting prenatally.
- ▶ This is the first case report in which the long-term follow-up of a patient with Sotos syndrome was performed.
- ▶ A case of skeletal Class III involved in Sotos syndrome was treated with nonsurgical orthodontic technique.
- ▶ Much attention should be paid to the early orthopedic treatment with the facemask and/or chin cap for Sotos syndrome.

1  
2  
3  
4  
5  
6  
7  
8  
9  
10  
11  
12  
13  
14  
15  
16  
17  
18  
19  
20  
21  
22  
23  
24  
25  
26  
27  
28  
29  
30  
31  
32  
33  
34  
35  
36  
37  
38  
39  
40  
41  
42  
43  
44  
45  
46  
47  
48  
49  
50  
51  
52  
53  
54  
55  
56  
57  
58  
59  
60  
61  
62  
63  
64  
65

## **A case report of Sotos syndrome treated with nonsurgical orthodontic technique**

1  
2  
3 **Abstract**  
4

5 Sotos syndrome is a genetic disorder characterized by overgrowth in childhood, specific  
6 facial manifestations, advanced bone age, and mental retardation. Although only one case  
7 report of Sotos syndrome treated with surgical orthodontics has thus far been published,  
8 there have also been a few detailed reports of long-term observation of Sotos syndrome  
9 through total orthodontic treatment. This article aimed to present the case of a growing  
10 patient with skeletal mandibular protrusion and unilateral posterior crossbite as present in  
11 Sotos syndrome treated with a non-surgical orthodontic technique. A 10-year-old boy was  
12 diagnosed with skeletal mandibular protrusion and posterior crossbite associated with Sotos  
13 syndrome. After maxillary lateral expansion, the skeletal Class III relationship with an anterior  
14 crossbite improved owing to mandibular clockwise rotation, while the facemask had a  
15 marginal effect. At the completion of growth at 16 years, he had a skeletal Class I relationship,  
16 and thus, conventional orthodontic treatment with preadjusted edgewise appliances was  
17 initiated. After 41 months of multibracket treatment, acceptable occlusion with a functional  
18 Class I relationship was obtained. At 12 months postretention, no or few changes in occlusion  
19 and facial features were observed. Our results demonstrate that considering **the maxillofacial**  
20 **vertical growth during peripubertal period associated with Sotos syndrome, much attention**  
21 **should be paid to the early orthopedic treatment with the facemask and/or chin cap.**  
22  
23  
24  
25  
26  
27  
28  
29  
30  
31  
32  
33  
34  
35  
36  
37  
38  
39  
40  
41  
42  
43  
44  
45

46 **Key words:** Sotos syndrome; long-term management; overgrowth; skeletal Class III  
47  
48  
49  
50  
51  
52  
53  
54  
55  
56  
57  
58  
59  
60  
61  
62  
63  
64  
65

1  
2  
3 **INTRODUCTION**  
4

5 Overgrowth is commonly divided into three phenotypes: prenatal, post-natal and segmental  
6 overgrowth.<sup>1</sup> Of the three phenotypes, Sotos syndrome is categorized as a prenatal  
7 overgrowth syndrome, along with Beckwith-Wiedemann syndrome and Weaver syndrome.<sup>2</sup>  
8 Patients with Sotos syndrome exhibit increased height, especially for the first 4 years of life,  
9 macrosomia, dolichocephaly and macrocephaly, while they also show learning and  
10 intellectual disabilities, indicative of mental retardation.<sup>3-7</sup>  
11  
12

13 Regarding the characteristic maxillofacial features, tapered mandible and small maxillary  
14 dental arch have previously been reported.<sup>2,8</sup> Cole and Hughes<sup>4</sup> demonstrated that 54% of  
15 patients with Sotos syndrome exhibited early eruption of deciduous teeth, and Kotilainen et  
16 al<sup>4</sup> reported congenitally missing premolars in 69% of cases. Furthermore, other features  
17 frequently seen in Sotos syndrome are maxillary and mandibular recession, a long mandible  
18 with pointed chin, posterior crossbite and a narrow dental arch with proclined maxillary  
19 incisors,<sup>7</sup> while mandibular prognathism is rare.<sup>6,9</sup> Considering this, a characteristic occlusion  
20 for Sotos syndrome could not identified due to large interindividual variability in skeletal  
21 abnormalities.<sup>4</sup>  
22  
23

24 To the best of our knowledge, one patient with Sotos syndrome was orthodontically treated  
25 with distraction osteogenesis.<sup>8</sup> Although previous studies have reported craniofacial growth  
26 patterns during the prepubertal period in patients with Sotos syndrome,<sup>6,10</sup> there have been  
27 relatively few detailed reports of long-term observation through total orthodontic treatment.  
28 Therefore, little information is available on the efficacy of conventional orthodontic treatment,  
29 including early orthopedic treatment, in patients with Sotos syndrome.  
30  
31

32 The purpose of this report was to present a growing patient with skeletal mandibular  
33 protrusion and posterior crossbite as presented in Sotos syndrome, treated with a  
34  
35  
36  
37  
38  
39  
40  
41  
42  
43  
44  
45  
46  
47  
48  
49  
50  
51  
52  
53  
54  
55  
56  
57  
58  
59  
60  
61  
62  
63  
64  
65

1  
2  
3 nonsurgical orthodontic technique.  
4  
5  
6

## 7 **DIAGNOSIS AND ETIOLOGY**

8  
9  
10 A boy, aged 10 years, was referred to the Department of Pediatrics, \*\*\*\*\* University  
11 Hospital with a chief complaint of anterior crossbite and salivation. At the age of 4 years and  
12 6 months, he was diagnosed with Sotos syndrome. At birth, his body height, weight and head  
13 circumference was within the normal range; however, at the age of 10 months, his height  
14 had reached 78.6 cm, 2 standard deviations (SD) taller than Japanese male standards.<sup>11</sup> At  
15 the age of 5 years and 9 months, his body height and head circumference were 123.7 cm  
16 and 56.0 cm, respectively, both of which were > 2 SD greater than the standards for  
17 Japanese males.<sup>11,12</sup> The patient's mental development was also evaluated using the  
18 Wechsler intelligence scale for children-third edition (WISC-III).<sup>13</sup> His verbal intelligent  
19 quotient (IQ), performance IQ and full scale IQ were 67, 71 and 65, respectively, and he was  
20 thus diagnosed with mental retardation. A radiograph of the hand and wrist taken at age 6  
21 years and 1 month, showed that his right third, fourth, and fifth metacarpal bones were  
22 completely fused. According to the Tanner-Whitehouse 2 (TW2) using radius-ulna-short  
23 bones (RUS) scoring system, his bone age was evaluated as 11 years and 4 months for the  
24 right hand and 10 years and 1 month for the left hand, indicating advanced bone  
25 maturation.<sup>14,15</sup>  
26  
27  
28  
29  
30  
31  
32  
33  
34  
35  
36  
37  
38  
39  
40  
41  
42  
43  
44  
45  
46  
47

48 At the first examination (aged 10 years), facial photographs showed asymmetry, with a  
49 deviated chin on the left side, large lower facial height, and epicanthus (Fig 1). His chin  
50 presented with a mentalis strain during lip closure. The lateral profile was straight. Intraoral  
51 photographs showed that the mandibular dental midline deviated 3 mm to the left in relation  
52 to his facial midline. An anterior crossbite of -1.7 mm was observed, and the molar  
53  
54  
55  
56  
57  
58  
59  
60  
61  
62  
63  
64  
65

1  
2  
3 relationship was Angle Class III on both sides (Fig 2). Furthermore, a posterior crossbite was  
4 present at the left molar site. He had habits of mouth breathing and tongue thrusting when  
5 chewing and swallowing. His bone age was defined as 13 years and 5 months after  
6 evaluation by the TW2-RUS method (Fig 3),<sup>14,15</sup> while according to the cervical vertebral  
7 maturation (CVM) method, he was classified as CVM stage 3, and his bone age was  
8 calculated as 13 years and 8 months.<sup>16,17</sup> His body height was 152.0 cm, which was +2.6 SD  
9 taller than Japanese male standards (Fig 4).<sup>11,12</sup>

10  
11 A panoramic radiograph showed no congenitally missing permanent teeth (Fig 5).  
12 Cephalometric analysis, when compared to the Japanese male standards,<sup>18</sup> exhibited a  
13 skeletal Class III relationship (ANB, 0°). Although the SNB angle was within the normal range,  
14 considering that the anteroposterior length of the anterior cranial base (SN) was +3 SD larger,  
15 and the mandibular ramus height (Ar-Go), body length (Go-Me) and total length (Ar-Me) were  
16 more than +2 SD larger than those of the Japanese male standards, he was classified as  
17 having a skeletal mandibular protrusion (Fig 5; Table I). His anteroinferior facial height was  
18 larger than +2 SD of the Japanese norm (Me/palatal plane, 72.6 mm). The gonial angle was  
19 greater than the norm, while the mandibular plane angle was within the normal range (gonial  
20 angle, 134.3°; FMA, 31.5°). The maxillary central incisors were proclined (U1-SN, 110.2°).  
21 The inclination of the mandibular central incisors was within the normal range (IMPA, 87.3°).  
22  
23 **The Wits appraisal, the perpendicular distance between the points A and B on the occlusal**  
24 **plane, was -3.5 mm.** Posteroanterior cephalometric analysis<sup>19</sup> showed 3.4 mm of dental  
25 midline leftward deviation, 5.2° of maxillomandibular midline leftward deviation, and -1.8 mm  
26 of maxillary occlusal plane tilt (Fig 5; Table II).

## 27 28 29 30 31 32 33 34 35 36 37 38 39 40 41 42 43 44 45 46 47 48 49 50 51 52 53 54 55 56 57 58 **TREATMENT OBJECTIVES** 59 60 61 62 63 64 65



1  
2  
3 The treatment objectives were (1) to improve his anterior crossbite and unilateral posterior  
4  
5 crossbite, (2) to promote maxillary forward growth and restrict mandibular forward growth,  
6  
7 and (3) to obtain an acceptable Class I occlusion with a functional interincisal relationship.  
8  
9 The treatment planning was: (1) maxillary lateral expansion using a hyrax appliance to  
10  
11 improve unilateral posterior crossbite, (2) use of facemask to observe maxillary protraction  
12  
13 and improve anterior crossbite, (3) multibracket treatment for tooth alignment, and (4) surgery  
14  
15 after growth, if necessary. Oral myofunctional therapy (MFT) was also administered to remove  
16  
17 his parafunctional habit.  
18  
19  
20  
21  
22  
23

#### 24 **TREATMENT ALTERNATIVES**

25  
26 As patients with Sotos syndrome often show a deficient maxilla with a narrow maxillary arch  
27  
28 and tapered mandible, orthognathic surgery may be necessary. Takano et al<sup>8</sup> previously  
29  
30 reported a case of Sotos syndrome treated with surgically facilitated maxillary expansion and  
31  
32 mandibular distraction osteogenesis, and demonstrated that surgically assisted orthodontics  
33  
34 after complete growth is one of the treatment remedies to improve occlusion in patients with  
35  
36 Sotos syndrome. Meanwhile, no information is available regarding the prognosis of early  
37  
38 orthopedic treatment aimed at promoting maxillary forward growth and to restraining  
39  
40 mandibular forward growth. Therefore, in the present case, surgical modalities were  
41  
42 proposed as a treatment plan if the horizontal skeletal discrepancies worsened after physical  
43  
44 growth was complete. Since the use of facemask result in not only maxillary forward growth  
45  
46 and mandibular forward growth restriction but also mandibular clockwise rotation, these  
47  
48 treatment therapies might not be suitable for patients with skeletal open bite with increased  
49  
50 lower anterior facial height. However, our patient showed an average mandibular plane angle  
51  
52 with a large mandible, therefore, we decided to use aforementioned equipment to treat the  
53  
54  
55  
56  
57  
58  
59  
60  
61  
62  
63  
64  
65

1  
2  
3 mandibular protrusion by mandibular forward growth restriction and clockwise mandibular  
4  
5 rotation.  
6  
7  
8  
9

## 10 **TREATMENT PROGRESS**

11  
12 When the patient was 10 years and 3 months old, he was fitted with a hyrax appliance, and  
13 the maxilla was expanded at a rate of 0.5 mm/day. The total amount of maxillary expansion  
14 between maxillary first molars was 5.0 mm, resulting in improvement of the unilateral  
15 posterior crossbite. Immediately after maxillary palatal expansion, a maxillary protraction was  
16 observed using a facemask. The patient was instructed to use the appliance for at least 10  
17 hours/day to correct the anterior crossbite; however, due to his mental retardation, he could  
18 not understand the implication of orthodontic treatment. Since his mother was cooperative to  
19 orthodontic treatment for him, he could wear the facemask every day and the compliance  
20 reached at least 10 hours/day use. By using the facemask with a total of 600-g protraction  
21 forces for 9 months, his anterior crossbite improved, and the overjet was increased to 7.0  
22 mm. Cephalometric analysis after initial treatment revealed that the ANB angle increased  
23 with mandibular clockwise rotation, although maxillary forward growth was not significantly  
24 promoted by the facemask (Fig 6; Table I). His bone age was defined as 14 years and 4  
25 months according to the TW2-RUS method and 14 years and 6 months according to the  
26 CVM method (Figs 3 and 6).<sup>14-17</sup> His body height was 158 cm, which was > 2 SD taller than  
27 the Japanese male standards (Fig 4).<sup>11</sup> Thereafter, only chin cap therapy was performed until  
28 his growth completed in order to prevent mandibular overgrowth<sup>20,21</sup> to the greatest extent  
29 possible (Fig 6; Table I). During the 3-year treatment with a chin cap, maxillary forward growth  
30 was observed, and the ANB angle was increased to 4.3°, indicating a skeletal Class I  
31 relationship. **The value of Wits appraisal increased by 7.5 mm and became +4.0 mm.** The  
32  
33  
34  
35  
36  
37  
38  
39  
40  
41  
42  
43  
44  
45  
46  
47  
48  
49  
50  
51  
52  
53  
54  
55  
56  
57  
58  
59  
60  
61  
62  
63  
64  
65

1  
2  
3 mandibular plane angle (FMA) was increased to 35.7°, indicating a high mandibular plane  
4  
5 angle. Throughout the 1st phase of the treatment, the patient continued to follow instructions  
6  
7 as per the MFT to correct his myofunctional problems, which included tongue thrusting and  
8  
9 mouth breathing; however, these problems could not be overcome. At the age of 14 years,  
10  
11 his bone age evaluated by TW2-RUS method was defined as 15 years and 10 months (Fig  
12  
13 3), implying that his bone had already matured.<sup>14,15</sup> According to the CVM method, he was  
14  
15 classified as CVM stage 5, and his bone age was calculated at 16 years and 5 months old.<sup>16</sup>  
16  
17 His body height was 176 cm, which was +1.8 SD taller than the Japanese male standards  
18  
19 (Fig 4).<sup>11</sup>  
20  
21  
22  
23

24 At the age of 16 years, all permanent teeth had erupted, and physical growth was almost  
25  
26 complete. At this time, his body height was 179 cm, which was +1.7 SD taller than the  
27  
28 Japanese male standards (Fig 4). His lateral profile changed to a convex type with upper and  
29  
30 lower lip protrusions (Fig 7). He exhibited moderate crowding of both the upper and lower  
31  
32 anterior dentitions, a 3.9 mm of overjet, and a 0.5 mm overbite (Fig 8). The canine and molar  
33  
34 relationships were Class I on both sides. Arch length discrepancies were -3.5 mm and -5.5  
35  
36 mm for the maxillary and mandibular arches, respectively. A panoramic radiograph revealed  
37  
38 the existence of bilateral upper and lower third molars and no abnormality or deformation of  
39  
40 either condyle (Fig 9). Cephalometric analysis revealed a skeletal Class I (ANB, 3.8°) and a  
41  
42 high mandibular plane angle (FMA, 37.3°) (Fig 10; Table I). The maxillary central incisors  
43  
44 were still proclined (U1-SN, 111.8°), while the mandibular central incisors were slightly  
45  
46 inclined lingually (FMIA, 52.4°; IMPA, 90.3°). From 14 to 16 years of age, mandibular  
47  
48 downward growth was still continuing, while mandibular forward growth had almost stopped  
49  
50 and the value of Wits appraisal maintained +4.0 mm (Fig 10). Posteroanterior cephalogram<sup>19</sup>  
51  
52 showed a 3.4 mm leftward deviation of the mandibular dental midline and a 4.0°  
53  
54  
55  
56  
57  
58  
59  
60  
61  
62  
63  
64  
65

1  
2  
3 maxillomandibular midline leftward deviation (Fig 9; Table II). The occlusal plane tilt was  
4  
5 decreased to -1.1 mm. According to the CVM method,<sup>16,17</sup> he was classified as CVM stage 6  
6  
7 and his bone age was calculated as 18 years old, while his body height was 179 cm, +1.6  
8  
9 SD taller than the Japanese male standards (Fig 4).<sup>11</sup>  
10

11  
12 After extraction of all third molars, the patient, aged 16 years and 1 month, started to receive  
13  
14 multibracket treatment as the 2nd phase. Preadjusted edgewise appliances with a 0.018-in  
15  
16 slot were set on the maxillary and mandibular teeth to correct anterior crowding. After leveling  
17  
18 with nickel-titanium alloy wires, orthodontic miniscrews were inserted bilaterally between the  
19  
20 maxillary and mandibular second premolars and first molars. To distalize all teeth, a 200-g  
21  
22 force was applied with elastic chains anchored between the canine and orthodontic  
23  
24 miniscrew on each side. After 3 years and 5 months of active treatment (aged 19 years and  
25  
26 6 months), an acceptable occlusion with close intercuspation was achieved, and all the  
27  
28 appliances were removed. Wraparound type retainers were placed on both the upper and  
29  
30 lower teeth and used for the whole day except eating and tooth-brushing. A lingually bonded  
31  
32 retainer was also placed on the mandibular anterior teeth.  
33  
34  
35  
36  
37  
38  
39  
40

## 41 **TREATMENT RESULTS**

42  
43 Posttreatment facial photographs showed an improvement in lip protrusion although the  
44  
45 lateral profile was still convex (Fig 11), while the mentalis strain at the lip closure was reduced.  
46  
47 Close intercuspation of the teeth was performed with functional canine guidance during  
48  
49 lateral mandibular movement. Overjet and overbite were improved to 1.3 mm and 1.1 mm,  
50  
51 respectively, and a proper interincisal relationship was achieved (Fig 12). Canine and molar  
52  
53 relationships were maintained in a Class I relationship. A panoramic radiograph revealed root  
54  
55 parallelism (Fig 13). Posttreatment cephalometric analysis indicated a skeletal Class I  
56  
57  
58  
59  
60  
61  
62  
63  
64  
65

1  
2  
3 relationship (ANB, 3.6°) (Fig 14; Table I). The mandibular plane angle was still higher than  
4  
5 the Japanese male standard (FMA, 36.4°) but no impairment (clockwise rotation of the  
6  
7 mandible) was present during multibracket treatment (Fig 14; Table I). The inclination of the  
8  
9 maxillary central incisors was improved (U1-SN, 102.8°) and the mandibular central incisors  
10  
11 showed less changes in its inclination (FMIA, 53.7°; IMPA, 89.9°). The value of Wits appraisal  
12  
13 was decreased to +3.5 mm. A posteroanterior cephalogram<sup>19</sup> revealed matching of the  
14  
15 maxillary and mandibular dental midlines, whereas the maxillomandibular midline was still  
16  
17 deviated by 3.5° to the left (Fig 14; Table II). The occlusal plane tilt was decreased to -0.4  
18  
19 mm. According to the CVM method,<sup>16,17</sup> his bone age was calculated as 19 years as the CVM  
20  
21 stage 6.  
22  
23  
24  
25

26  
27 At 12 months postretention (aged 20 years and 6 months), the lateral profile showed no or  
28  
29 few changes. The occlusion was well maintained without any relapse of anterior crowding  
30  
31 (Figs 15 and 16). A proper interincisal relationship was maintained under functional guidance.  
32  
33 A panoramic radiograph showed little or minimal changes in the alveolar bone level and root  
34  
35 parallelism (Fig 17). Cephalometric evaluation revealed little or no changes, without any  
36  
37 substantial relapse in the skeletal and dental aspects (Fig 14; Table 1). Posteroanterior  
38  
39 cephalometric analysis showed no changes during the 12 months retention period (Fig 17;  
40  
41 Table II).  
42  
43  
44  
45  
46  
47

## 48 **DISCUSSION**

49

50  
51 Patients with craniosynostosis conditions, such as Apert and Crouzon syndrome also exhibit  
52  
53 skeletal mandibular protrusion due to severe maxillary growth deficiency.<sup>22</sup> Previous literature  
54  
55 has indicated that the solution to such marked skeletal problems involving genetic diseases  
56  
57 were limited by the insufficiency of the recovery of maxillary horizontal growth by early  
58  
59  
60  
61  
62  
63  
64  
65

1  
2  
3 orthopedic treatment.<sup>23</sup> Meanwhile, Sotos syndrome is a rare genetic disease, and little  
4  
5 information is available on the effectiveness of early orthopedic treatment on patients with  
6  
7 Sotos syndrome. The present patient exhibited slight maxillary forward growth during  
8  
9 treatment with a facemask; however, the maxillary growth rate was almost similar to that in  
10  
11 normal males. This implies no or less acceleration of maxillary forward growth induced by  
12  
13 early orthopedic treatment with the facemask.  
14  
15

16  
17 It is known that a long-term treatment with chin cap therapy resulted in a significant  
18  
19 backward rotation of the mandible, indicating an increase of the mandibular plane angle.<sup>21,24</sup>  
20  
21 Abdelnaby and Nassar<sup>25</sup> also demonstrated that the use of a chin cap improved the  
22  
23 maxillomandibular base relationship in growing patients with Class III malocclusion due to a  
24  
25 decrease of the ramus height and an increase of the mandibular plane angle but with only  
26  
27 minor skeletal effects. Takei et al.<sup>6</sup> evaluated the changes in maxillofacial growth in two  
28  
29 patients with Sotos syndrome, and demonstrated that both patients exhibited an increase in  
30  
31 the mandibular plane angle during the peripubertal period without any orthodontic treatment.  
32  
33 Our patient also exhibited mandibular vertical growth during observation period after phase I  
34  
35 treatment (Figure 10). These imply that the maxillofacial vertical growth is considered  
36  
37 important in the treatment of this syndrome. Although the present patient with Sotos  
38  
39 syndrome had an average mandibular plane angle at the initial stage and improved the  
40  
41 anterior crossbite by the unexpected excessive mandibular clockwise rotation, we maybe  
42  
43 should not use a facemask and chin cap taking into account prevention of mandibular vertical  
44  
45 overgrowth, in our case.  
46  
47  
48  
49  
50  
51

52  
53 Sotos syndrome is likely to advanced bone age with early bone maturation.<sup>26,27</sup> According  
54  
55 to the TW2-RUS method,<sup>14,15</sup> our patient also showed early bone maturation, and his bone  
56  
57 age was evaluated as 13.4 years, 14.3 years and 15.8 years at the age of 10, 11 and 14,  
58  
59  
60  
61  
62  
63  
64  
65

1  
2  
3 respectively. His bone maturation level at 14 years was almost that of an adult. Conversely,  
4  
5 according to the CVM method,<sup>16,17</sup> his bone age was assessed as 13.7 years, 14.8 years,  
6  
7 16.4 years and 18.0 years at the age of 10, 11, 14 and 16, respectively. Regarding the CVM  
8  
9 stage, his cervical vertebra at the age of 14 had already matured, and was classified as CVM  
10  
11 stage 5. This indicates that the bone age evaluated by the TW2-RUS method was almost  
12  
13 matched to that evaluated by the CVM method in patients with Sotos syndrome as well as  
14  
15 the general populations.<sup>28</sup> The CVM method for the assessment of skeletal age has proven  
16  
17 to be highly reliable and can be performed on a cephalometric radiograph, resulting in the  
18  
19 elimination of the additional hand-wrist radiograph.<sup>28,29</sup>  
20  
21  
22  
23

24 Before orthodontic treatment, we measured the lip-closing force using a simple  
25  
26 measurement device (Lipplekun, Shofu Co., Kyoto, Japan), and found that the patient had a  
27  
28 lip-closing force of only 8.9 N, which was significantly lower than the Japanese 15-year-old  
29  
30 male standard (13.4 N  $\pm$  2.9 N). It is known that the force of the lip closure in children with  
31  
32 mouth breathing is significantly smaller than that in children with nasal breathing.<sup>30</sup> In addition,  
33  
34 it is suggested that MFT including lip muscle training upregulates the maximum lip closing  
35  
36 force and improves mouth breathing.<sup>31</sup> In particular, several researchers have demonstrated  
37  
38 that the combination of MFT and orthodontic treatment was more successful in correcting lip  
39  
40 incompetence than MFT alone.<sup>32,33</sup> Furthermore, throughout the 1st phase treatment, we  
41  
42 provided the patient with MFT to correct myofunctional problems including tongue thrusting  
43  
44 during chewing and swallowing. Eventually, although the lip closing force was increased to  
45  
46 11.5 N, he could not overcome myofunctional problems and he retained the habits of tongue  
47  
48 thrusting and mouth breathing after treatment. Owing to the mental retardation, we could not  
49  
50 obtain the patient's cooperation in other treatment processes. Regarding mental retardation,  
51  
52 80%-100% of patients with Sotos syndrome have developmental delays, and the degree of  
53  
54  
55  
56  
57  
58  
59  
60  
61  
62  
63  
64  
65

1  
2  
3 intellectual impairment varies greatly among them.<sup>34</sup> In our patient, the mental development  
4  
5 level evaluated using the WISC-III was slightly lower than the normal level, indicating a mild  
6  
7 delay in mental development. It is difficult to end a series of orthodontic treatments and  
8  
9 achieve sufficient treatment outcomes without patient cooperation. This may explain why only  
10  
11 a limited number of case reports of orthodontically treated patients with Sotos syndrome have  
12  
13 been published. Furthermore, since residual parafunctional habits are subject to severe  
14  
15 relapses, such as open bite, our results indicate the necessity for long-term observation of a  
16  
17 patient with Sotos syndrome after active orthodontic treatment.  
18  
19  
20  
21  
22  
23

## 24 **CONCLUSION**

25  
26 Although early orthopedic treatment with the facemask and chin cap was not effective, his  
27  
28 anterior crossbite improved by mandibular clockwise rotation, and an acceptable occlusion  
29  
30 was well retained throughout the 1-year retention period. **Considering the maxillofacial**  
31  
32 **vertical growth during peripubertal period associated with Sotos syndrome, much attention**  
33  
34 **should be paid to the early orthopedic treatment with the facemask and/or chin cap.**  
35  
36  
37  
38  
39  
40  
41  
42  
43  
44  
45  
46  
47  
48  
49  
50  
51  
52  
53  
54  
55  
56  
57  
58  
59  
60  
61  
62  
63  
64  
65



1  
2  
3 **References**  
4

- 5 1. Manor J, Lalani SR. Overgrowth syndromes-Evaluation, diagnosis, and management.  
6 Front Pediatr 2020;8:574857.  
7  
8  
9  
10 2. Allanson JE, Cole TR. Sotos syndrome: evolution of facial phenotype subjective and  
11 objective assessment. Am J Med Genet 1996;65:13-20.  
12  
13 3. Cole TRP, Hughes HE. Sotos syndrome: A study of the diagnostic criteria and natural  
14 history. J Med Genet 1994;31:20-32.  
15  
16  
17 4. Kotilainen J, Pohjola P, Pirinen S, Arte S, Nieminen P. Premolar hypodontia is a common  
18 feature in Sotos syndrome with a mutation in the *NSD1* gene. Am J Med Genet Part A  
19 2009;149A:2409-14.  
20  
21  
22 5. Nishimura K, Mori Y, Yamauchi M, Kamakura N, Homma H, Namura H, Miyamoto E,  
23 Matsumoto M, Shintani S, Ooshima T. Sotos syndrome with oligodontia: Case report.  
24 Pediatr Dent J 2008;18:187-91.  
25  
26  
27 6. Takei K, Sueishi K, Yamaguchi H, Ohtawa Y. Dentofacial growth in patients with Sotos  
28 syndrome. Bull Tokyo Dent Coll 2007;48:73-85.  
29  
30  
31 7. Hirai N, Matsune K, Ohashi H. Craniofacial and oral features of Sotos syndrome:  
32 Differences in patients with submicroscopic deletion and mutation of *NSD1* gene. Am J  
33 Med Genet Part A 2011;155:2933-9.  
34  
35  
36 8. Takano M, Kasahara K, Ogawa C, Katada H, Sueishi K. A case of Sotos syndrome  
37 treated with distraction osteogenesis in maxilla and mandible. Bull Tokyo Dent Coll  
38 2012;53:75-82.  
39  
40  
41 9. Allanson JE, Cole TR. Sotos syndrome: evaluation of facial phenotype subjective and  
42 objective assessment. Am J Med Genet 1996;65:13-20.  
43  
44  
45  
46 10. Nakamura S, Hirai N, Shimizu K. Craniofacial growth in Sotos syndrome. Pediatr Dent J  
47  
48  
49  
50  
51  
52  
53  
54  
55  
56  
57  
58  
59  
60  
61  
62  
63  
64  
65

1  
2  
3 2012;22:178-87.  
4

- 5 11. Suwa S, Tachibana K, Maesaka H, Tanaka T, Yokoya S. Longitudinal standards for height  
6 and height velocity for Japanese children from birth to maturity. *Clin Pediatr Endocrinol*  
7 2007;1:5-13.  
8  
9  
10  
11 12. Anzo M, Takahashi T, Sato S, Matsuo N. The cross-sectional head circumference growth  
12 curves for Japanese from birth to 18 years of age: the 1990 and 1992-1994 national  
13 survey data. *Ann Hum Biol* 2002;29:373-88.  
14  
15  
16  
17 13. Kaufman AS. *Intelligent testing with the WISC-III*. New York, John Wiley & Sons., 1994.  
18  
19  
20 14. Tanner JM, Whitehouse RH, Cameron N, Marshall WA, Healy MJR, Goldstein H.  
21 *Assessment of Skeletal Maturity and Prediction of Adult Height (TW2 Method)*. 2nd ed.,  
22 London, Academic Press, 1983.  
23  
24  
25 15. Ashizawa K, Asami T, Anzo M, Matsuo N, Matsuoka H, Murata M, Ohtsuki F, Satoh M,  
26 Tanaka T, Tatara H, Tsukagoshi K. Standard RUS skeletal maturation of Tokyo children.  
27 *Ann Hum Biol* 1997;236:457-469.  
28  
29  
30 16. McNamara JA Jr, Franchi L. *The cervical vertebral maturation method: A user's guide*.  
31 *Angle Orthod* 2018;88:133-143.  
32  
33  
34 17. Sato K, *Maxillofacial Growth and Development for Dentists*, 1st ed., Tokyo Clinical  
35 Publications Inc. [published in Japanese], Tokyo, 2013, pp. 71-76.  
36  
37  
38 18. Wada K, Matsushita K, Shimazaki S, Miwa Y, Hasuike Y, Susami R. An evaluation of a  
39 new case analysis of a lateral cephalometric roentgenogram. *J Kanazawa Med Univ*  
40 1981;6:60-70.  
41  
42  
43 19. Nezu H, Nagata K, Yoshida Y, Kikuchi M. *Bioprogressive Diagnostics*. 3rd ed., Tokyo,  
44 [published in Japanese], Rocky Mountain Morita, 1989.  
45  
46  
47 20. Mimura H, Deguchi T. Morphologic adaptation of temporomandibular joint after chincup  
48  
49  
50  
51  
52  
53  
54  
55  
56  
57  
58  
59  
60  
61  
62  
63  
64  
65

- 1  
2  
3 therapy. *Am J Orthod Dentofacial Orthop* 1996;110:541-546.  
4  
5 21. Deguchi T, Kuroda T, Minoshima Y, Graber TM. Craniofacial features of patients with  
6  
7 Class III abnormalities: Growth-related changes and effects of short-term and long-term  
8  
9 chin cup therapy. *Am J Orthod Dentofacial Orthop* 2002;121:84-92.  
10  
11  
12 22. Kobayashi Y, Ogura K, Hikita R, Tsuji M, Moriyama K. Craniofacial, oral, and cervical  
13  
14 morphological characteristics in Japanese patients with Apert syndrome or Crouzon  
15  
16 syndrome. *Eur J Orthod* 2020 Mar 7;cjaa015. doi: 10.1093/ejo/cjaa015. Online ahead of  
17  
18 print.  
19  
20  
21  
22 23. Delaire J. Maxillary development revisited: relevance to the orthopaedic treatment of  
23  
24 Class III malocclusions. *Eur J Orthod* 1997;19:289-311.  
25  
26  
27 24. Chatzoudi MI, Ioannidou-Marathiotou I, Papadopoulos MA. Clinical effectiveness of chin  
28  
29 cup treatment for the management of Class III malocclusion in pre-pubertal patients: a  
30  
31 systematic review and meta-analysis. *Prog Orthod* 2014;15:62.  
32  
33  
34 25. Abdelnaby YL, Nassar EA. Chin cup effects using two different force magnitudes in the  
35  
36 management of Class III malocclusions. *Angle Orthod* 2010;80:957-962.  
37  
38  
39 26. Sotos JF, Dodge PR, Muirhead DI, Crawford JD, Talbot NB. Cerebral gigantism in  
40  
41 childhood. A syndrome of excessively rapid growth with acromegalic features and a  
42  
43 nonprogressive neurologic disorder. *N Engl J Med* 1964;271:109-16.  
44  
45  
46 27. Kurotani N, Imaizumi K, Harada N, Masuno M, Kondoh T, Nagai T, Ohashi H, Haritomi K,  
47  
48 Tsukahara M, Makita Y, Sugimoto T, Sonoda T, Hasegawa T, Chinen Y, Tomita HH,  
49  
50 Kinoshita A, Yoshiura KK, Ohta T, Kishino T, Fukushima Y, Niikawa N, Matsumoto N.  
51  
52 Haploinsufficiency of NSD1 causes Sotos syndrome. *Nat Genet* 2002;30:365-6.  
53  
54  
55 28. Szemraj A, Wojtaszek-Slominska A, Racha-Pilszak B. Is the cervical vertebral maturation  
56  
57 (CVM) method effective enough to replace the hand-wrist maturation (HWM) method in  
58  
59  
60  
61  
62  
63  
64  
65

1  
2  
3 determining skeletal maturation?-A systemic review. Eur J Radiol 2018;102:125-8.  
4

5 29. Schoretsaniti L, Mitsea A, Karayianni K, Sifakakis I. Cervical vertebral maturation  
6 method: Reproducibility and efficiency of chronological age estimation. Appl Sci  
7 2021;11:3160.  
8  
9

10  
11 30. Murata N, Ono T, Shibata M, Aoyama T, Sakai S, Otsuka A, Kamiya S, Tsuchiya T. The  
12 Force of a Lip Closure in Children. Jpn J Pediat Dent 2007;45:29-34.  
13  
14

15 31. Suzuki H, Yoshimura M, Iwata Y, Oguchi S, Kawara M, Chow CM. Lip muscle training  
16 improves obstructive sleep apnea and objective sleep: a case report. Sleep Sci  
17 2017;10:128-31.  
18  
19

20 32. Daglio S, Schwitzer R, Wüthrich J. Orthodontic changes in oral dyskinesia and  
21 malocclusion under the influence of myofunctional therapy. Int J Orofacial Myology  
22 1993;19:15-24.  
23  
24

25 33. Homen MA, Vieira-Andrade RG, Falci SG, Ramos-Jorge ML, Marques LS. Effectiveness  
26 of orofacial myofunctional therapy in orthodontic patients: a systematic review. Dental  
27 Press J Orthod 2014;19:94-9.  
28  
29

30 34. Tatton-Brown K, Rahman N. Sotos syndrome. Eur J Hum Genet 2007;15:264-71.  
31  
32  
33  
34  
35  
36  
37  
38  
39  
40  
41  
42  
43  
44  
45  
46  
47  
48  
49  
50  
51  
52  
53  
54  
55  
56  
57  
58  
59  
60  
61  
62  
63  
64  
65

1  
2  
3 **Figure legends**  
4

5 Figure 1. Pretreatment facial and intraoral photographs at the age of 10 years.  
6  
7

8  
9  
10 Figure 2. Pretreatment dental casts.  
11  
12

13  
14 Figure 3. Images of hand-wrist radiographs at different ages: A, 10 years old; B, 11 years old;  
15  
16 C, 14 years old.  
17  
18  
19  
20

21  
22 Figure 4. Patient growth chart plotted on the Japanese male growth chart depicting actual  
23  
24 height and yearly height increments. Red plots indicate actual patient height. Blue  
25  
26 plots indicate yearly height increment of the patient. Bold lines represent the  
27  
28 average growth curve and average yearly height increment of a Japanese male.  
29  
30 Black dotted lines indicate +2.0 SD, +1.0 SD, -1.0 SD, and -2.0 SD.  
31  
32  
33

34  
35  
36 Figure 5. Pretreatment panoramic radiograph, lateral and posteroanterior cephalograms, and  
37  
38 their tracings.  
39  
40  
41

42  
43 Figure 6. Cephalometric tracings before treatment (black; age 10 years), after initial treatment  
44  
45 with maxillary lateral expansion and maxillary protraction (blue; age 11 years), and  
46  
47 after orthopedic treatment with chin cap (red; age 14 years) superimposed **on the**  
48  
49 **inner contour of the anterior wall of sella turcica, the anterior contour of zygomatic**  
50  
51 **process, and the inner contour of cortical plate at the lower border of the symphysis.**  
52  
53  
54  
55

56  
57 Figure 7. Facial and intraoral photographs before 2nd phase treatment at the age of 16 years.  
58  
59  
60  
61  
62  
63  
64  
65

1  
2  
3  
4  
5 Figure 8. Dental casts before 2nd phase treatment.  
6  
7  
8  
9

10 Figure 9. Panoramic radiograph, lateral and posteroanterior cephalograms, and their tracings  
11 before 2nd phase treatment.  
12  
13

14  
15  
16 Figure 10. Cephalometric tracings after 1st phase treatment (black; age 14 years) and before  
17 2nd phase treatment (red; age 16 years) superimposed on the inner contour of the  
18 anterior wall of sella turcica, the anterior contour of zygomatic process, and the  
19 inner contour of cortical plate at the lower border of the symphysis.  
20  
21  
22  
23  
24  
25  
26  
27

28 Figure 11. Posttreatment facial and intraoral photographs at the age of 19 years and 6 months.  
29  
30  
31

32  
33 Figure 12. Posttreatment dental casts.  
34  
35  
36  
37

38 Figure 13. Posttreatment panoramic radiograph, lateral and posteroanterior cephalograms,  
39 and their tracings after 2nd phase treatment.  
40  
41  
42  
43  
44

45 Figure 14. Cephalometric tracings before 2nd phase treatment (black; age 16 years),  
46 posttreatment (red; age 19 years and 6 months), and after 1-year retention (green;  
47 age 20 years and 6 months) superimposed on the inner contour of the anterior wall  
48 of sella turcica, the anterior contour of zygomatic process, and the inner contour of  
49 cortical plate at the lower border of the symphysis.  
50  
51  
52  
53  
54  
55  
56  
57  
58  
59  
60  
61  
62  
63  
64  
65

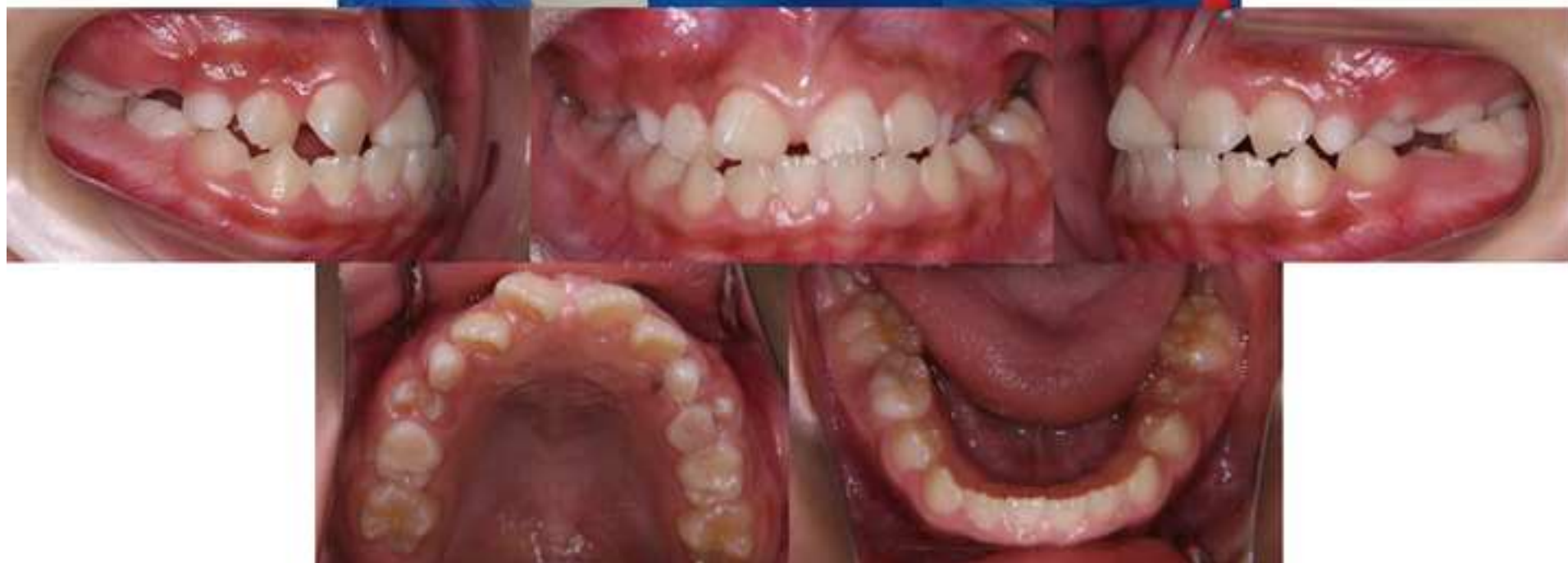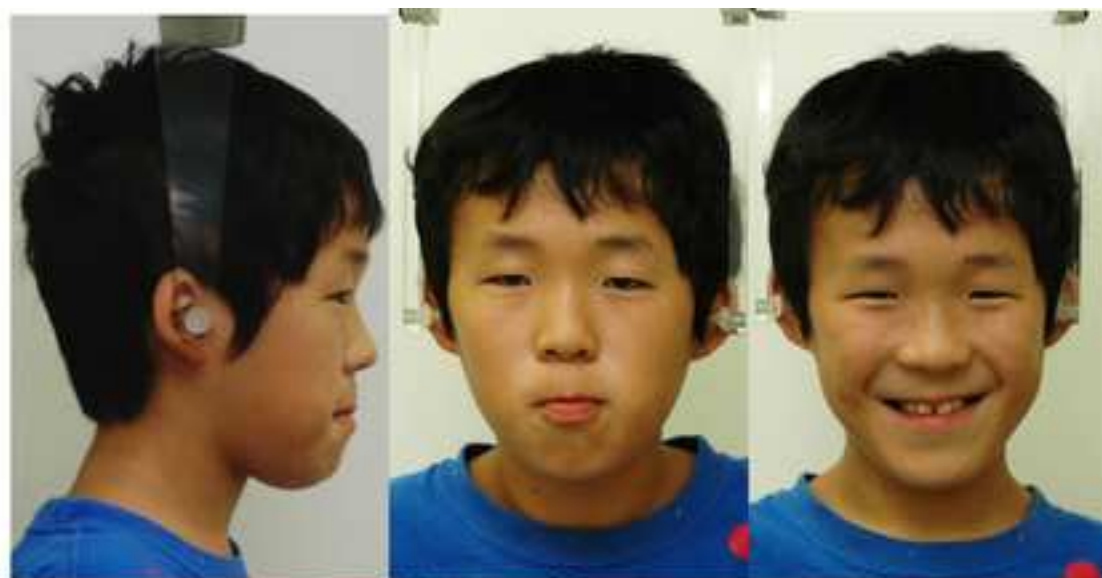1  
2  
3  
4  
5  
6  
7  
8  
9  
10  
11  
12  
13  
14  
15  
16  
17  
18  
19  
20  
21  
22  
23  
24  
25  
26  
27  
28  
29  
30  
31  
32  
33  
34  
35  
36  
37  
38  
39  
40  
41  
42  
43  
44  
45  
46  
47  
48  
49  
50  
51  
52  
53  
54  
55  
56  
57  
58  
59  
60  
61  
62  
63  
64  
65

Figure 15. Facial and intraoral photographs after 1-year retention at the age of 20 years and 6 months.

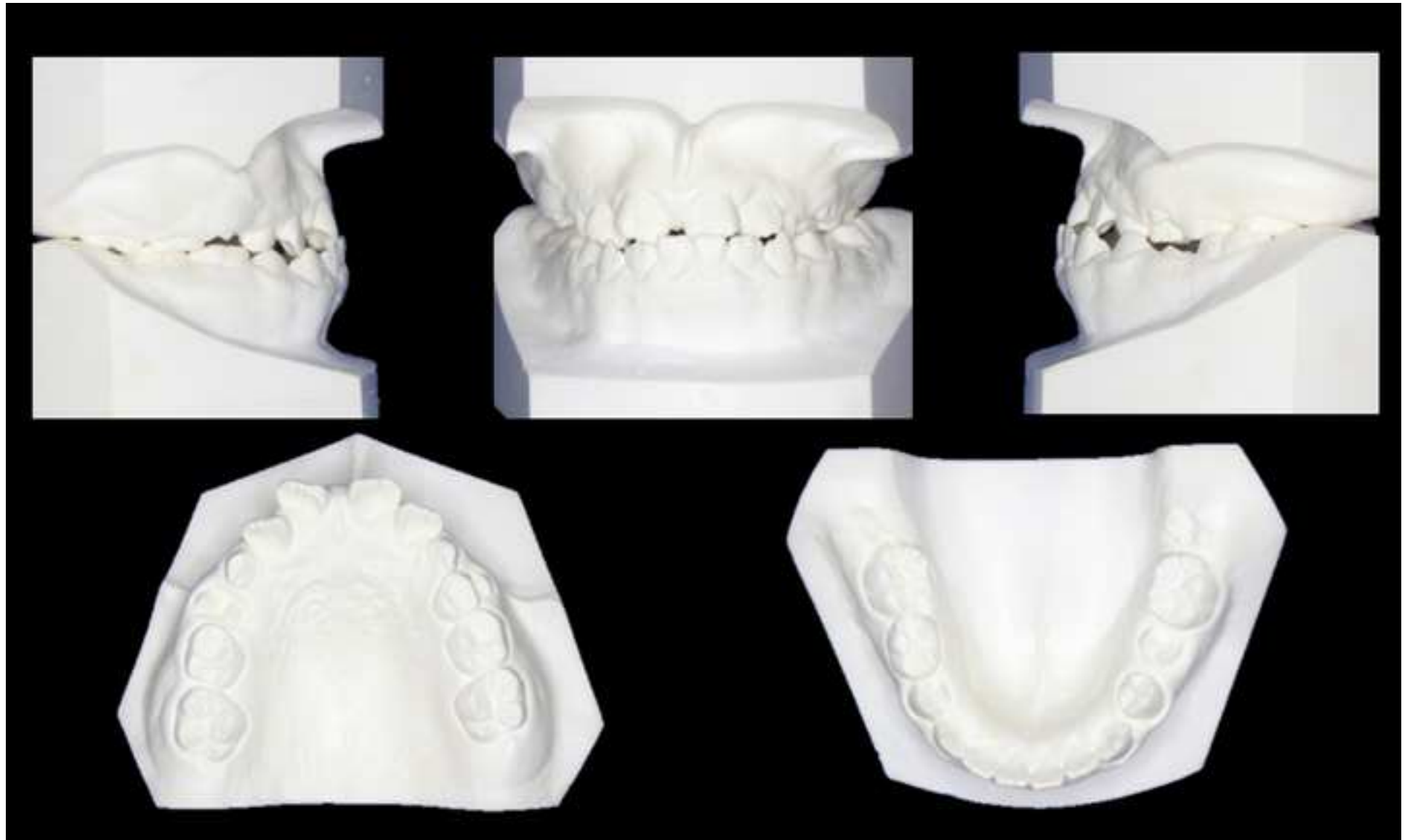
Figure 16. Dental casts after 1-year retention.

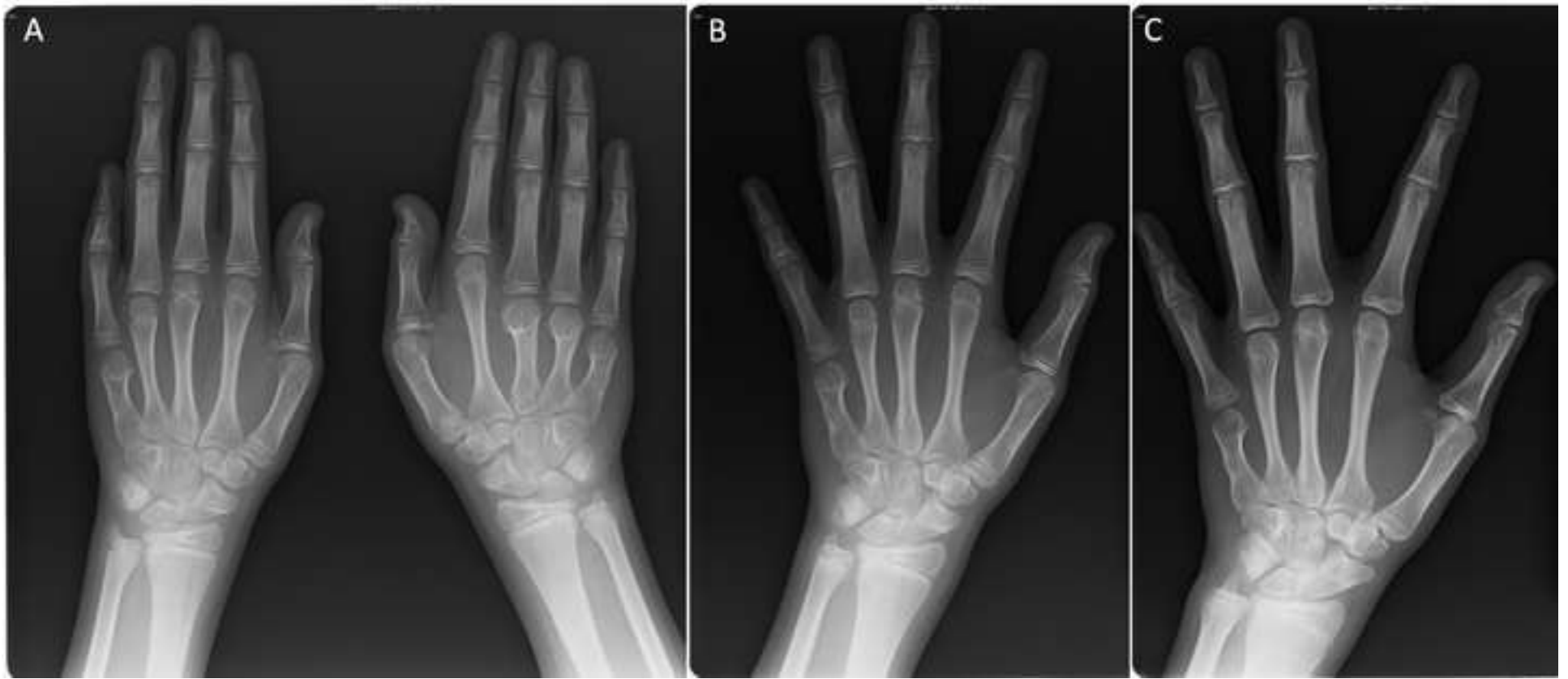
Figure 17. Panoramic radiograph, lateral and posteroanterior cephalograms, and their tracings after 1-year retention.

Figure 1









### Growth chart (0-18 years old)

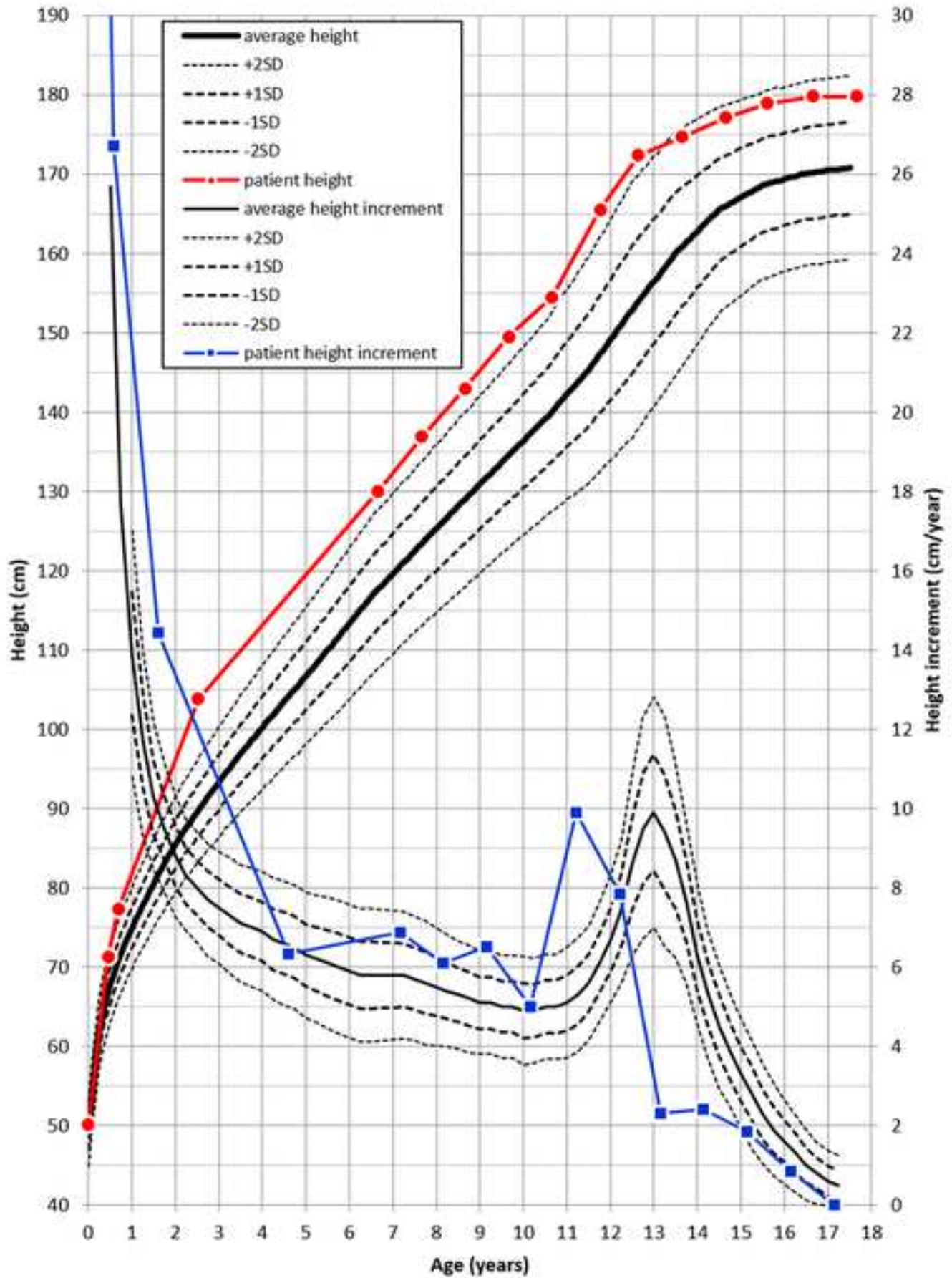
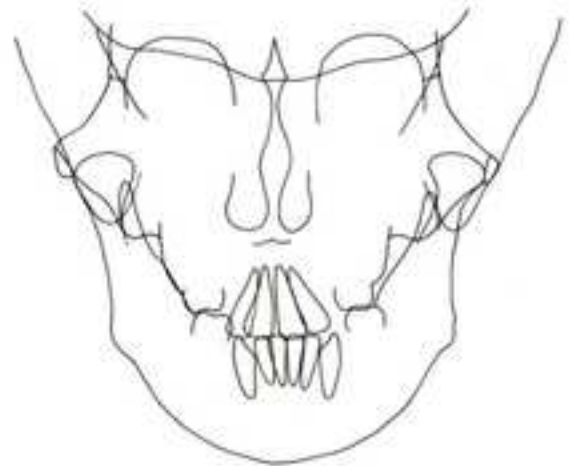
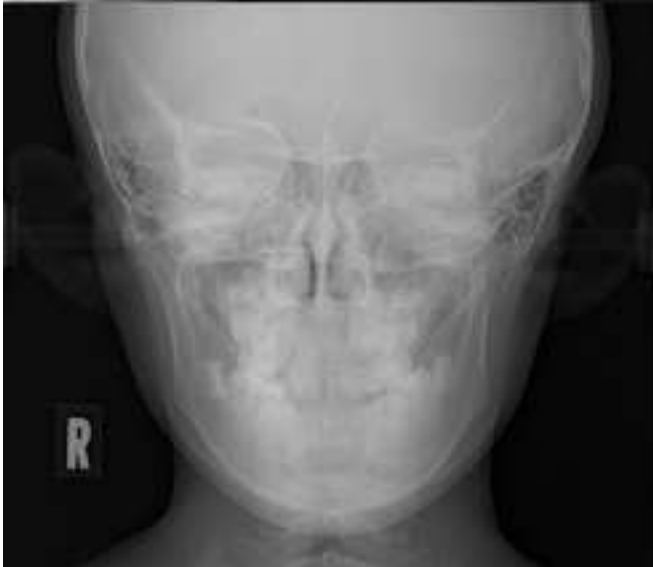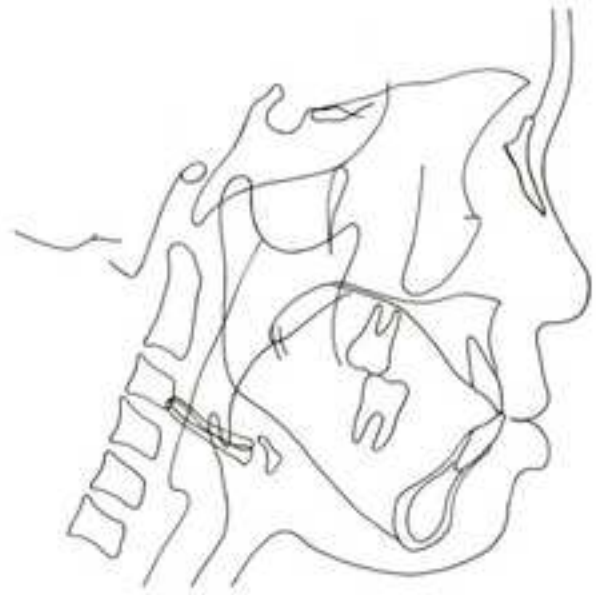
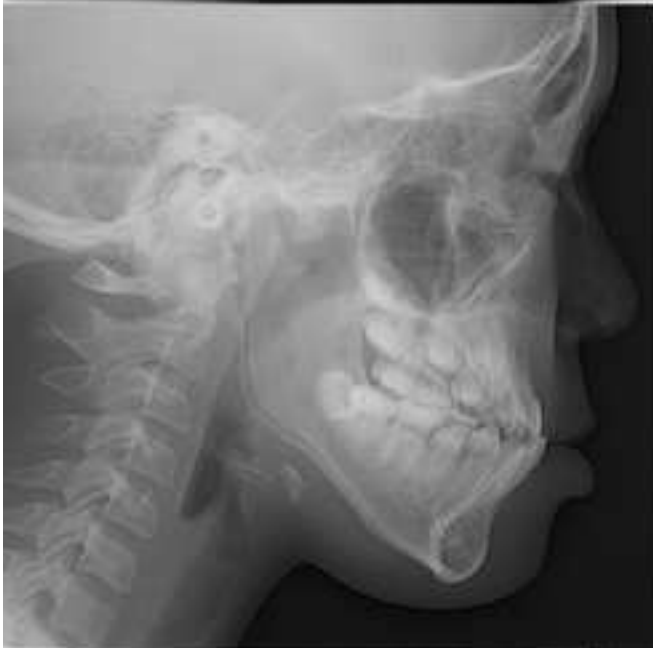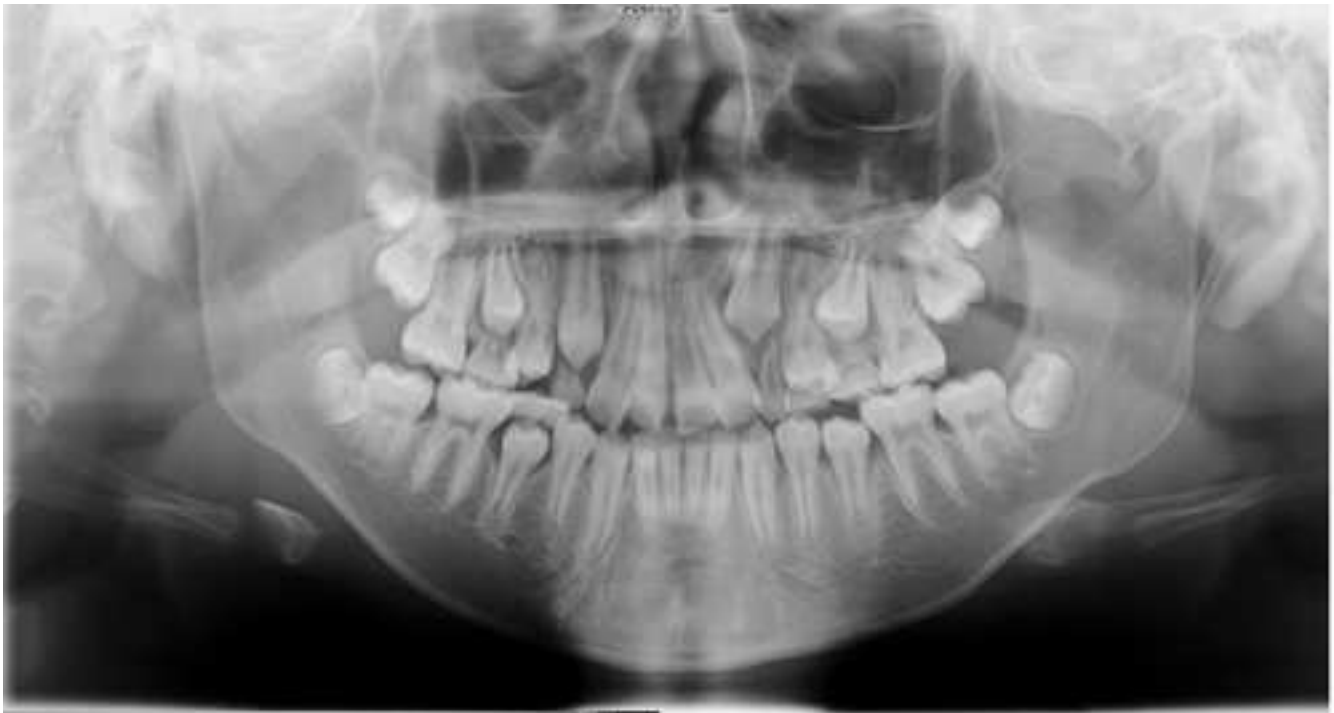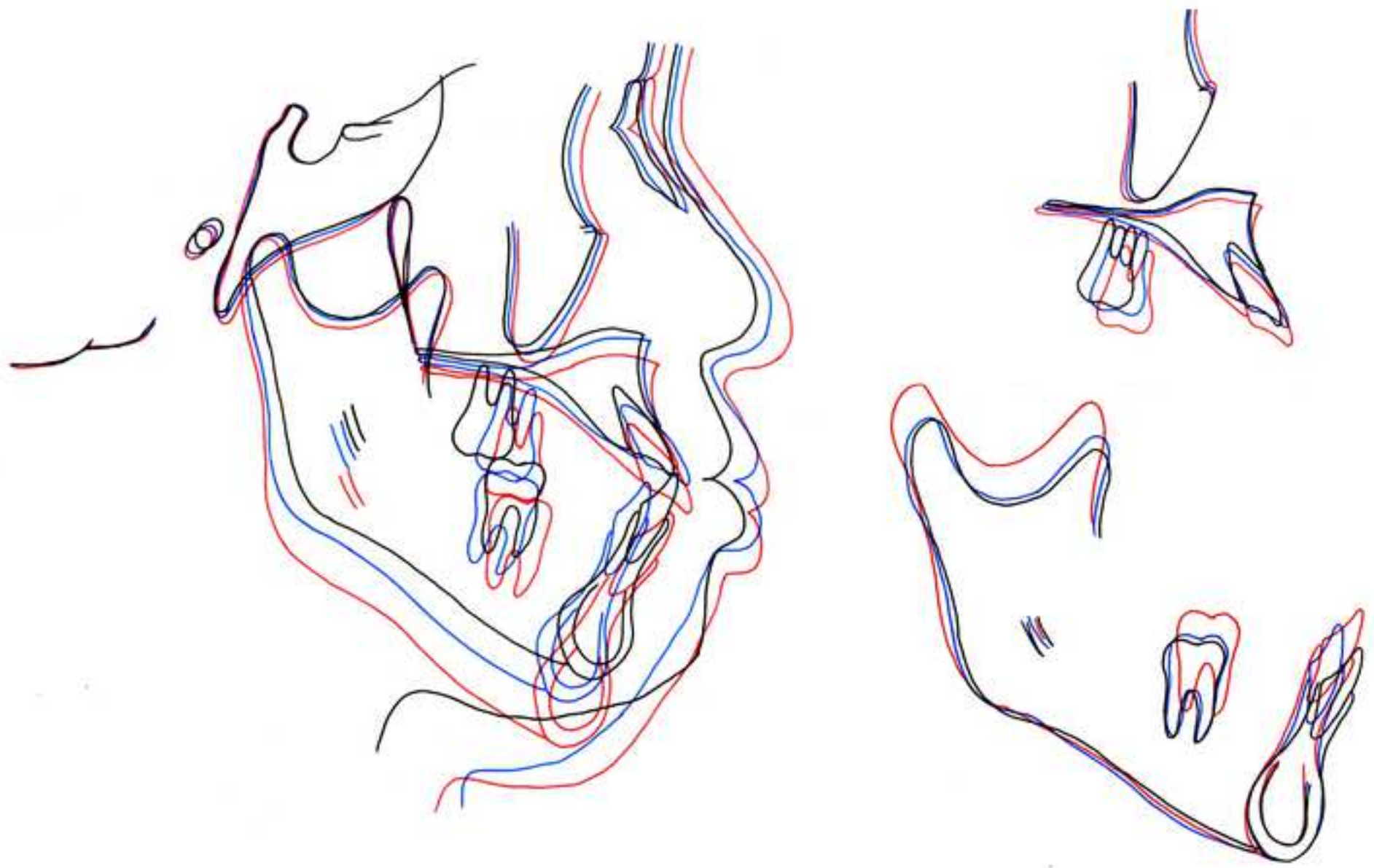
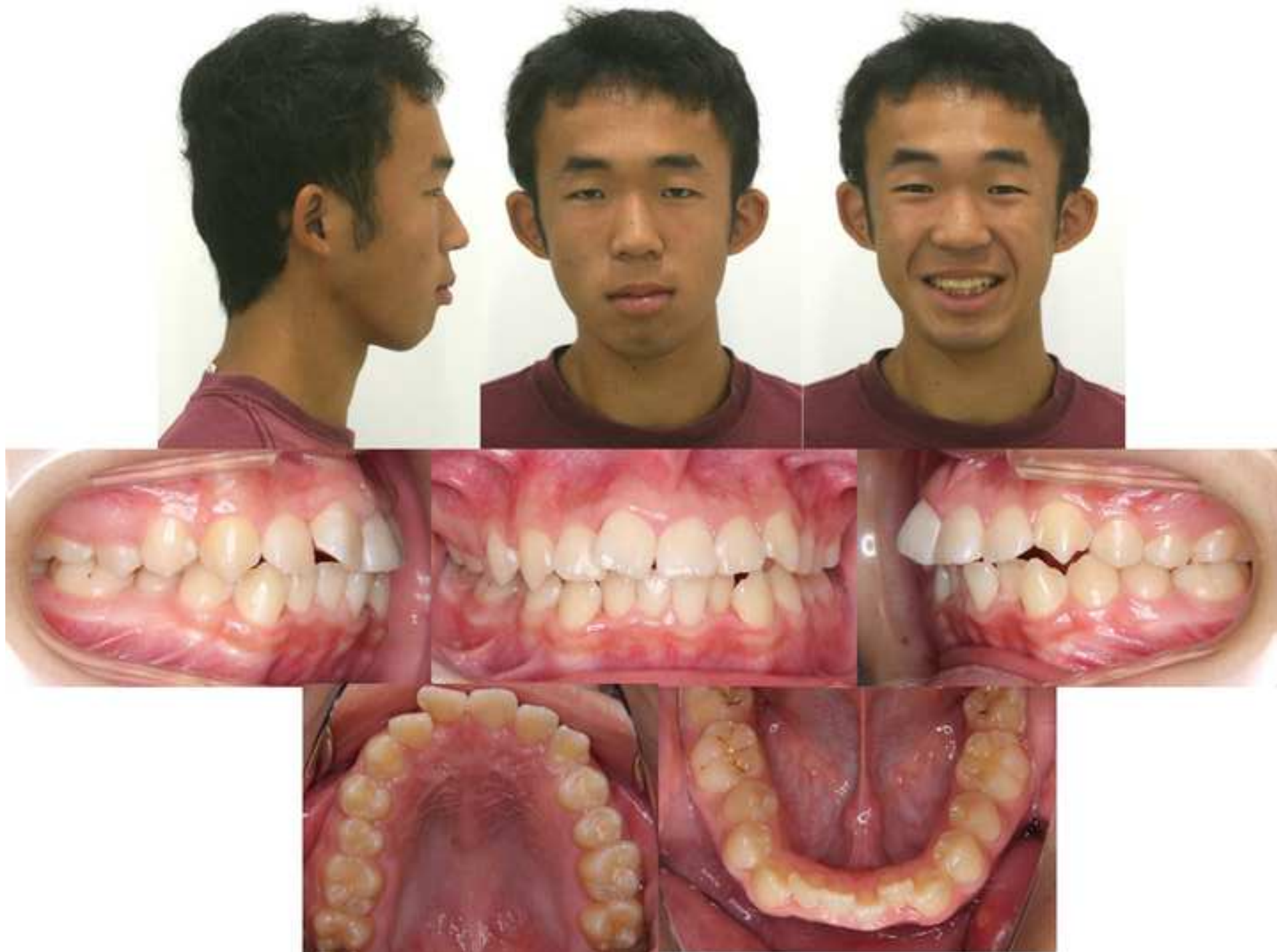


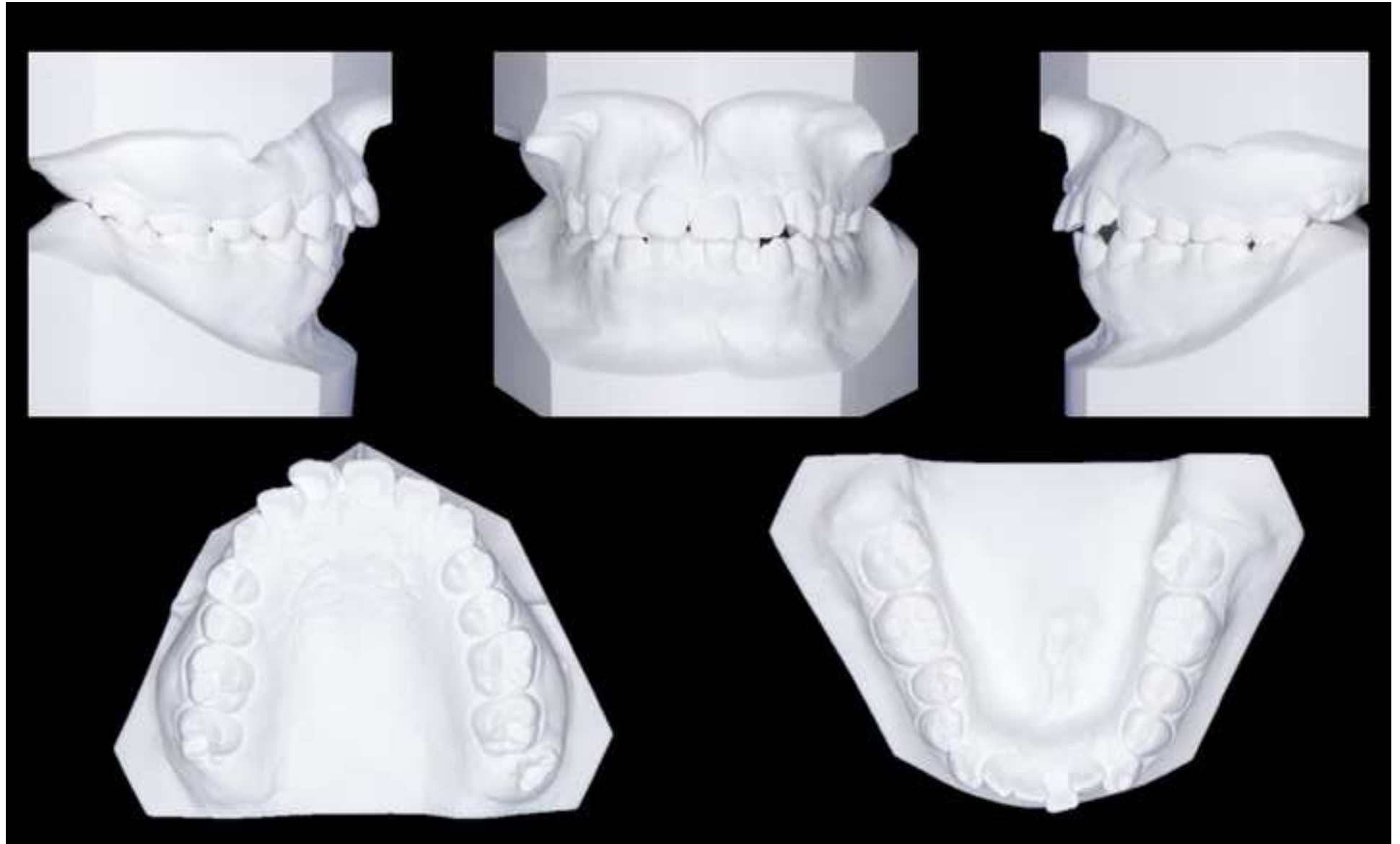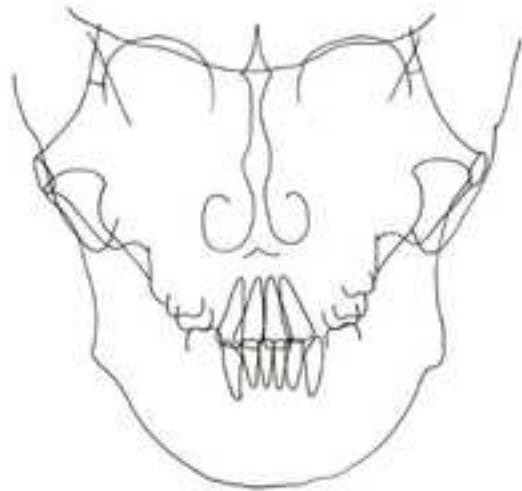
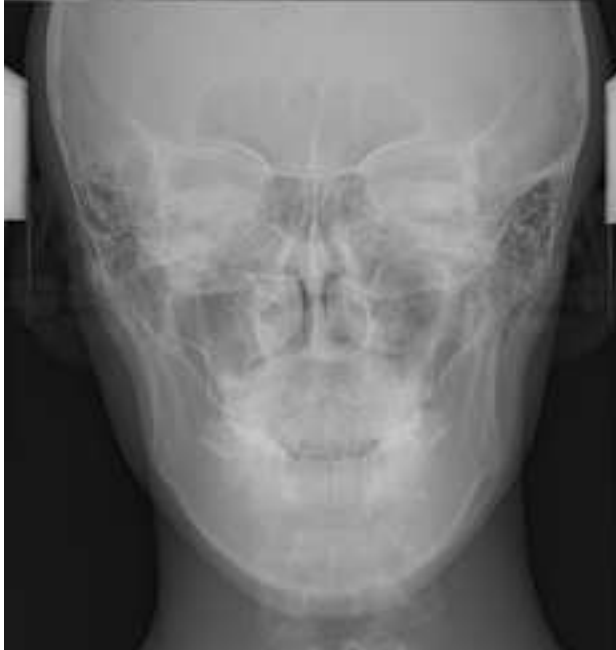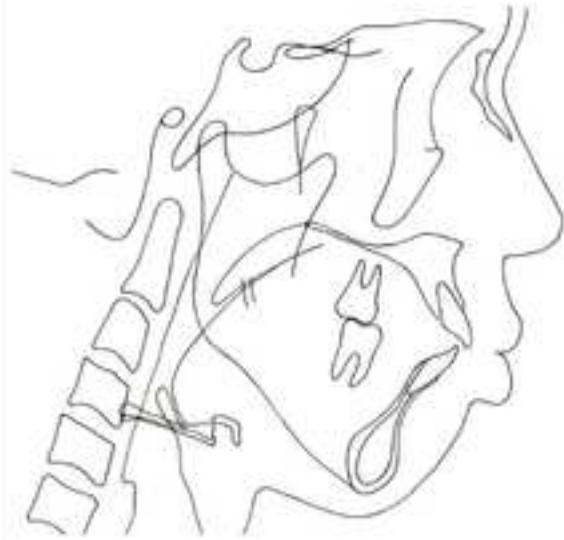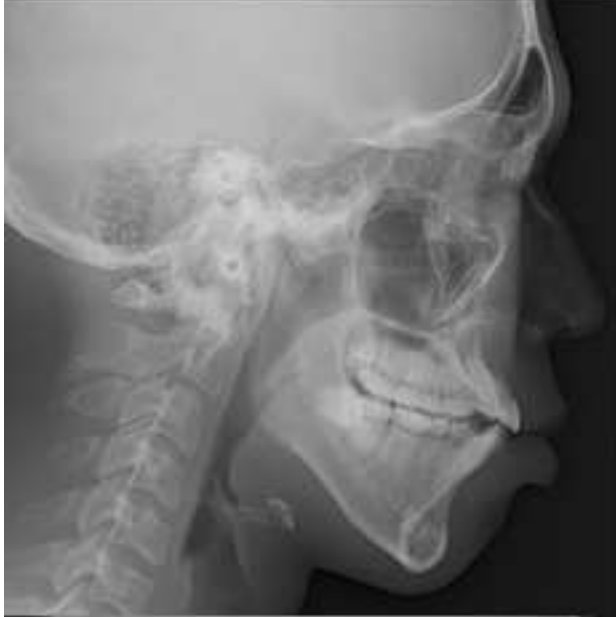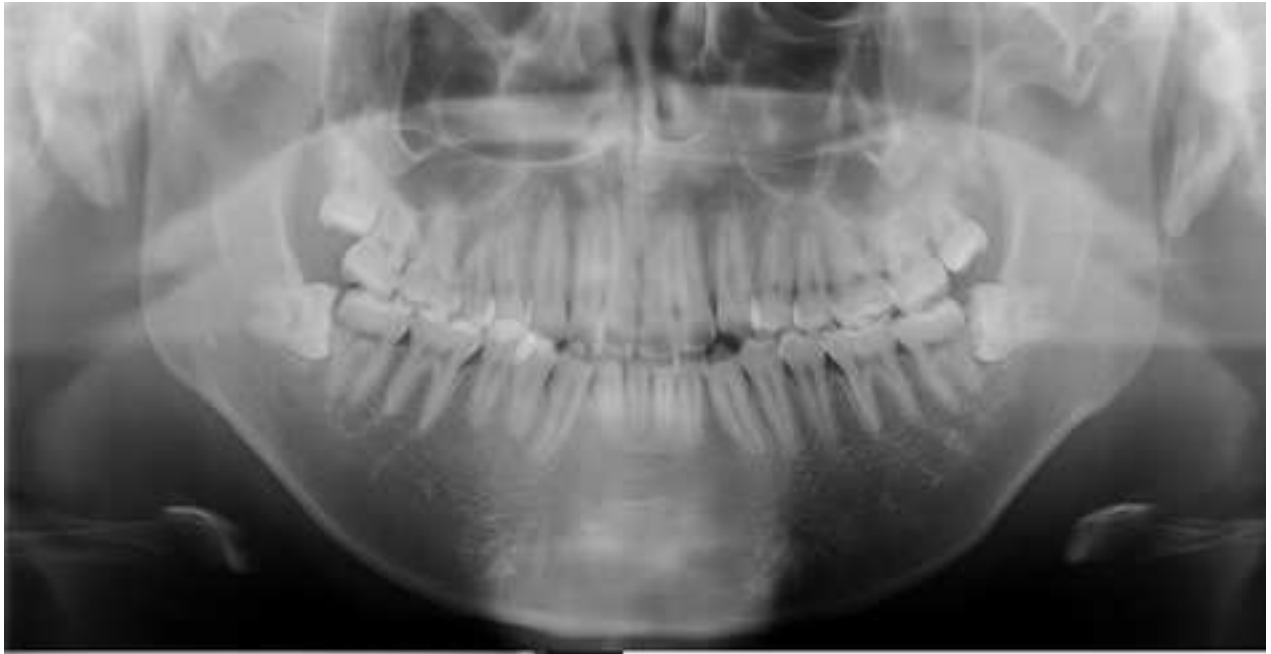
Figure 5



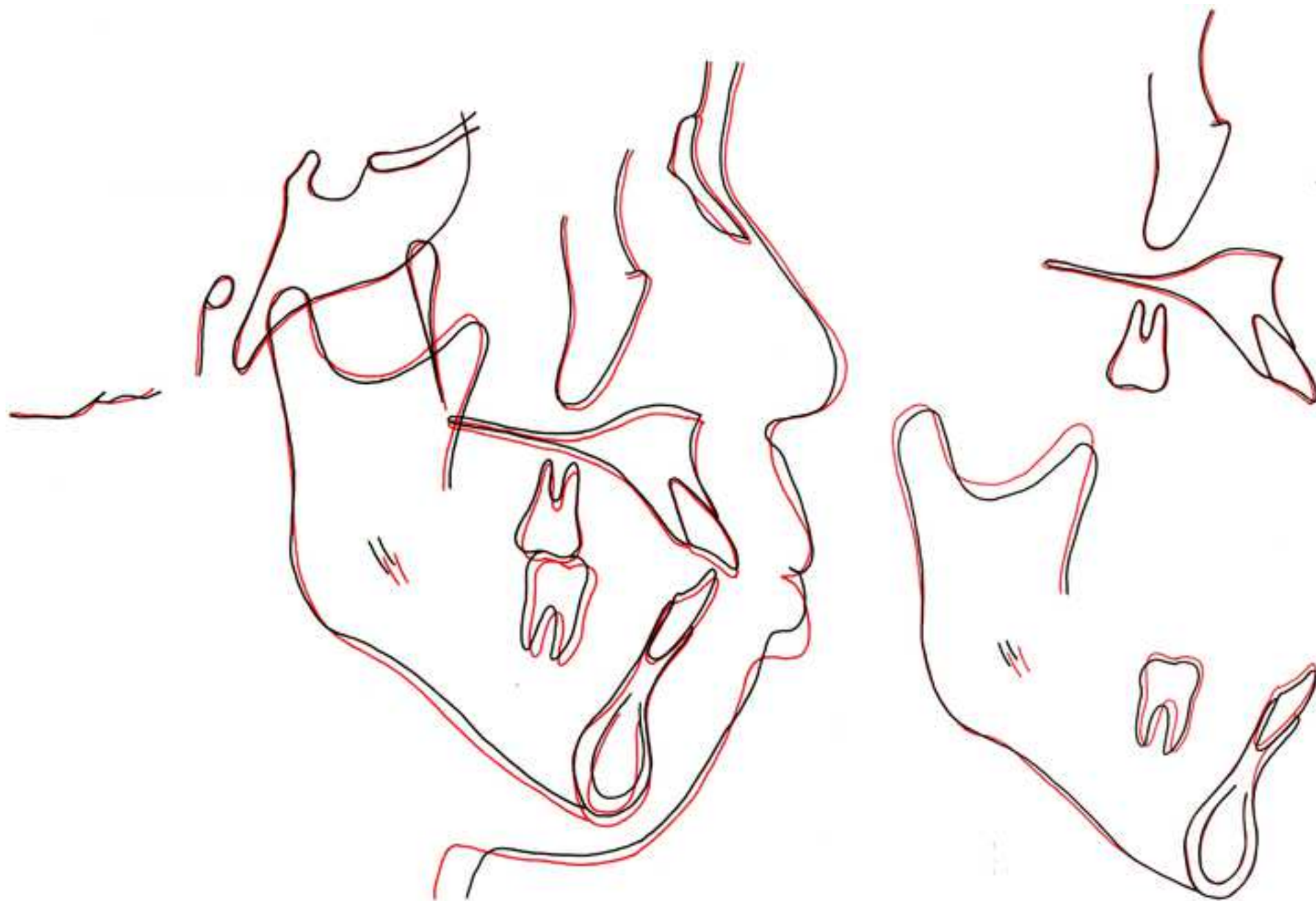


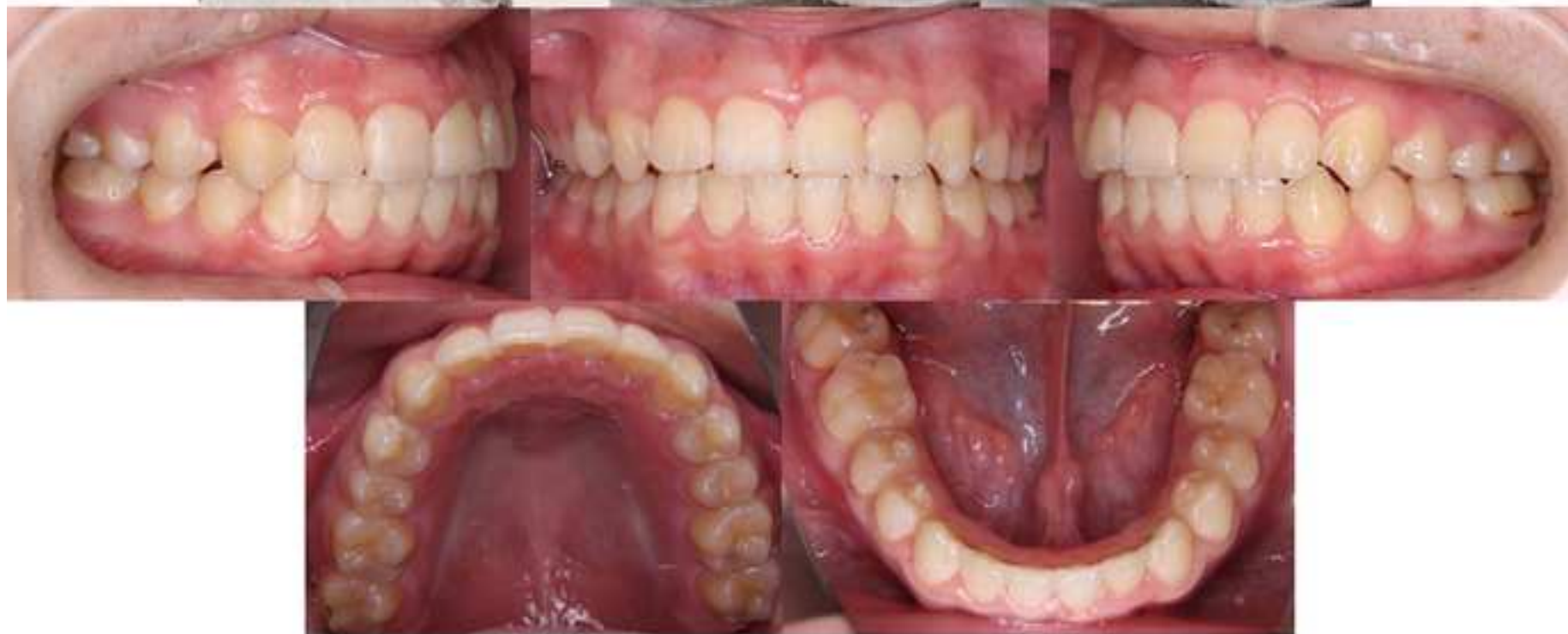
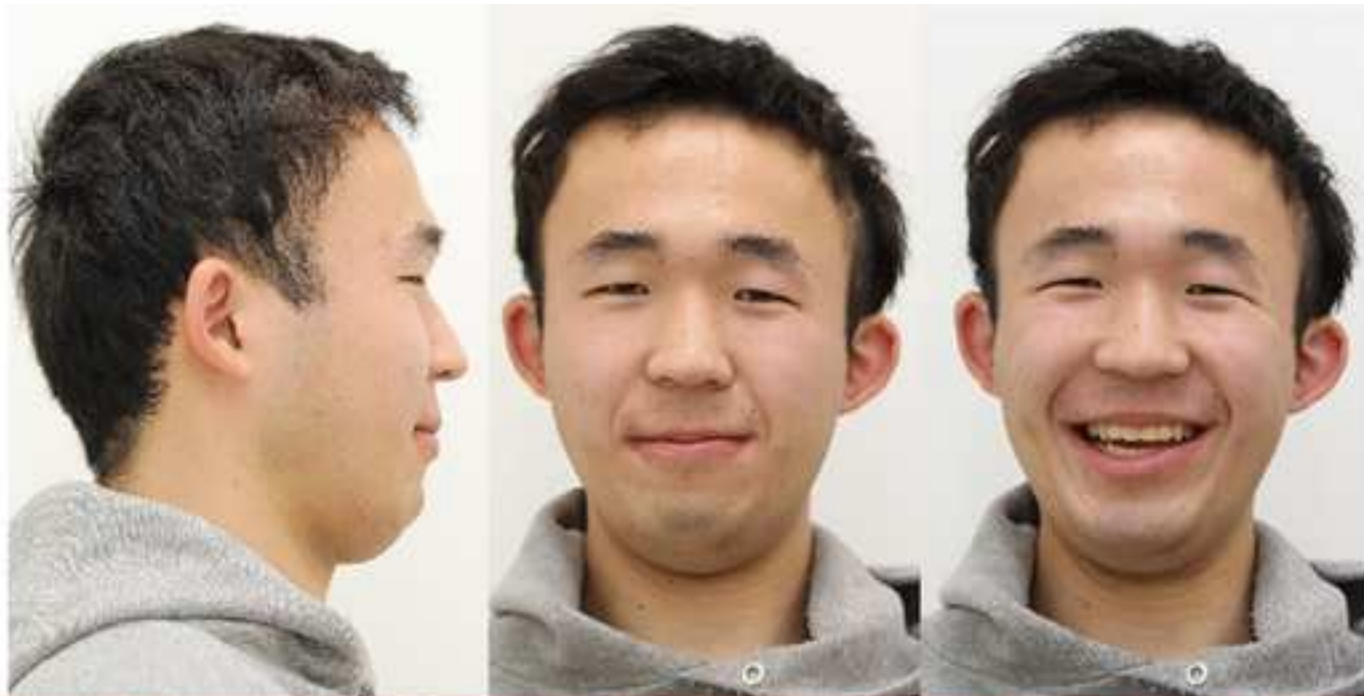
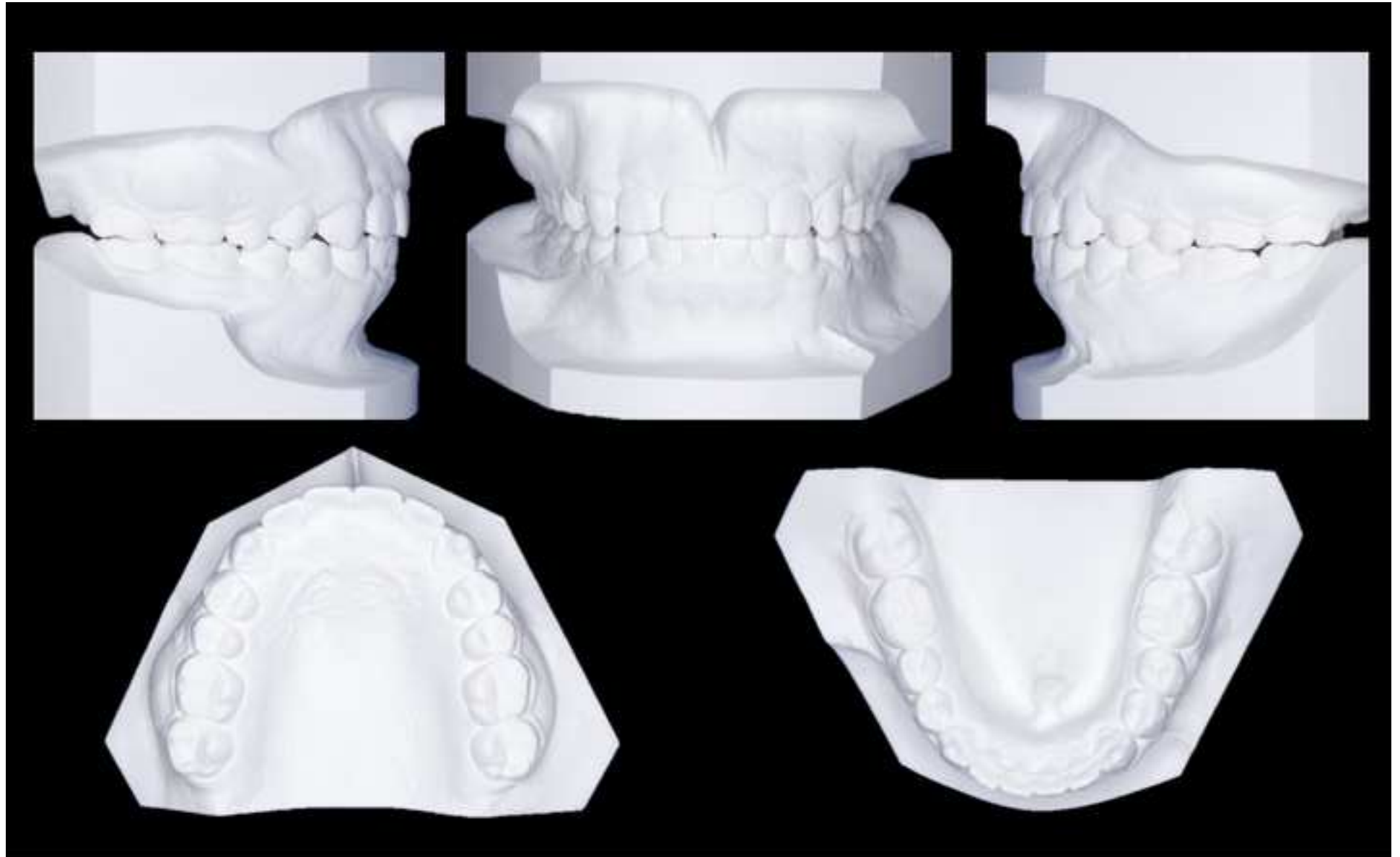


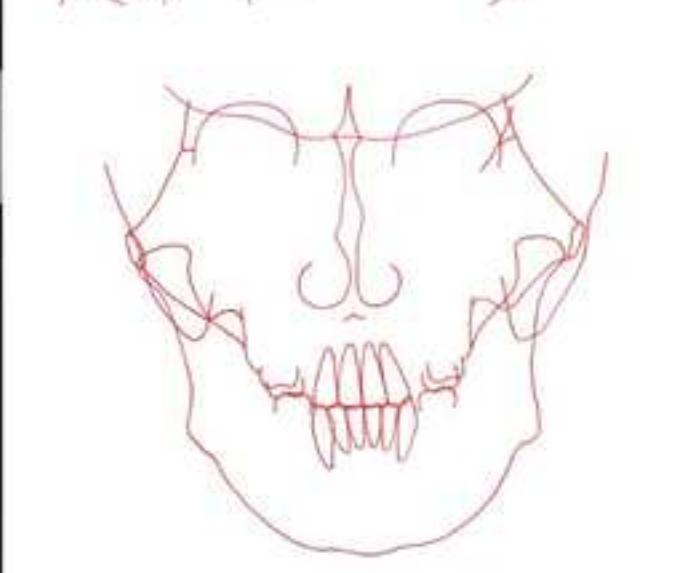


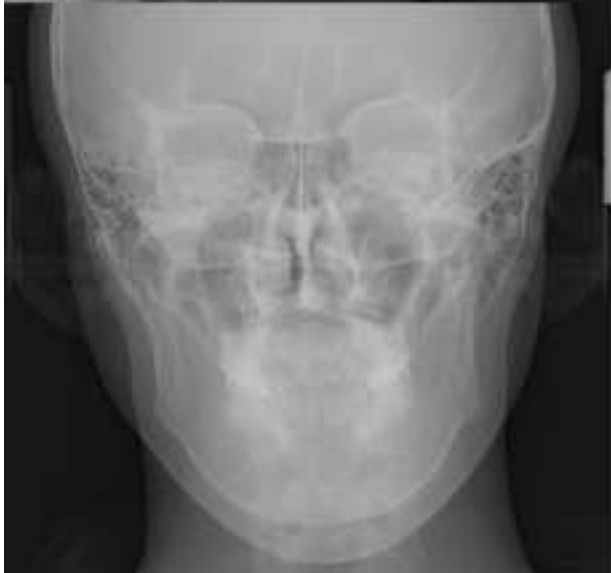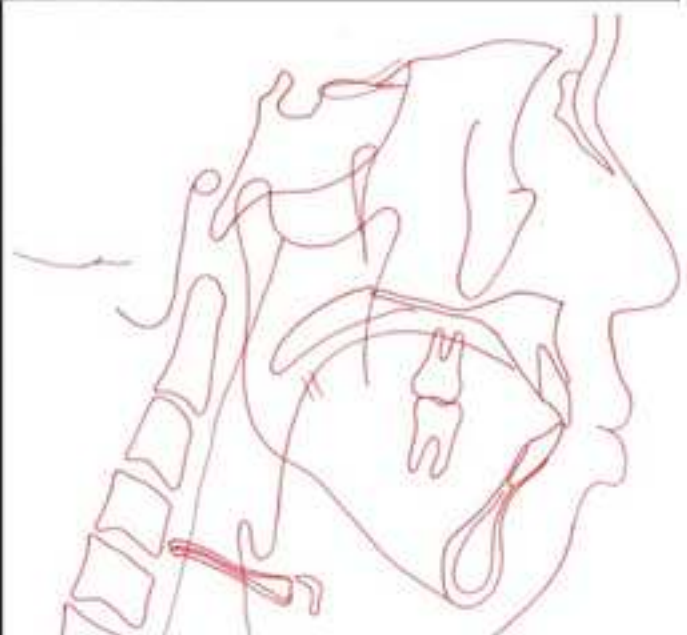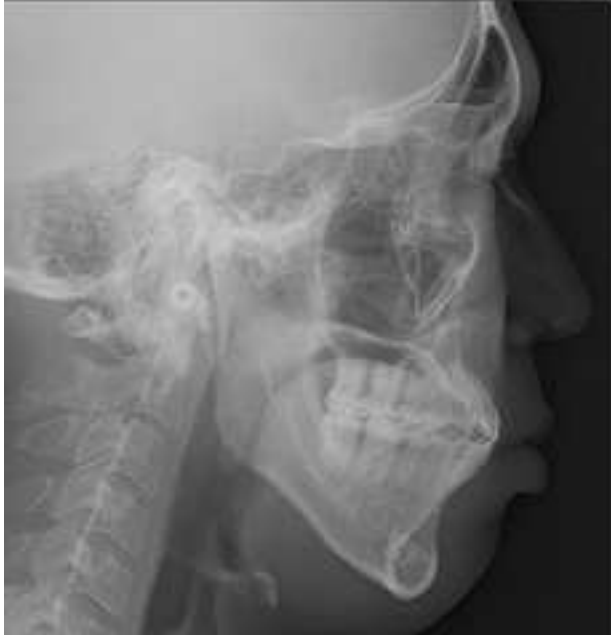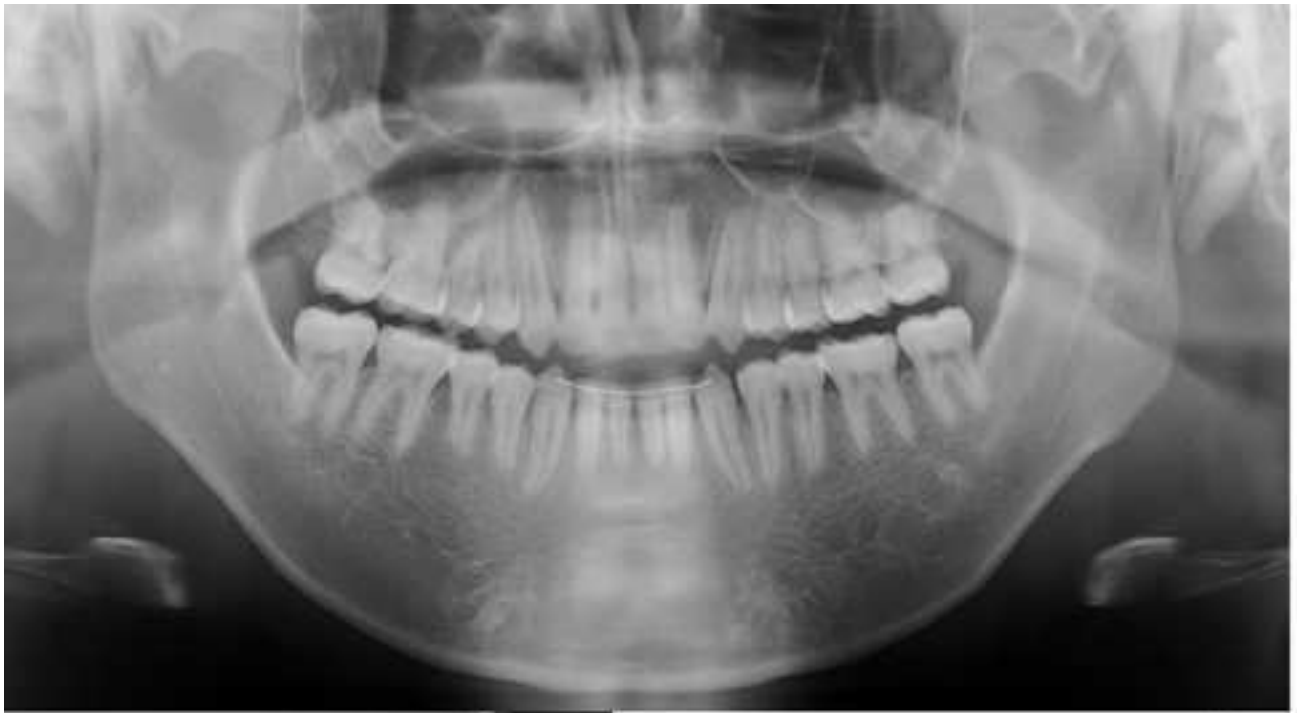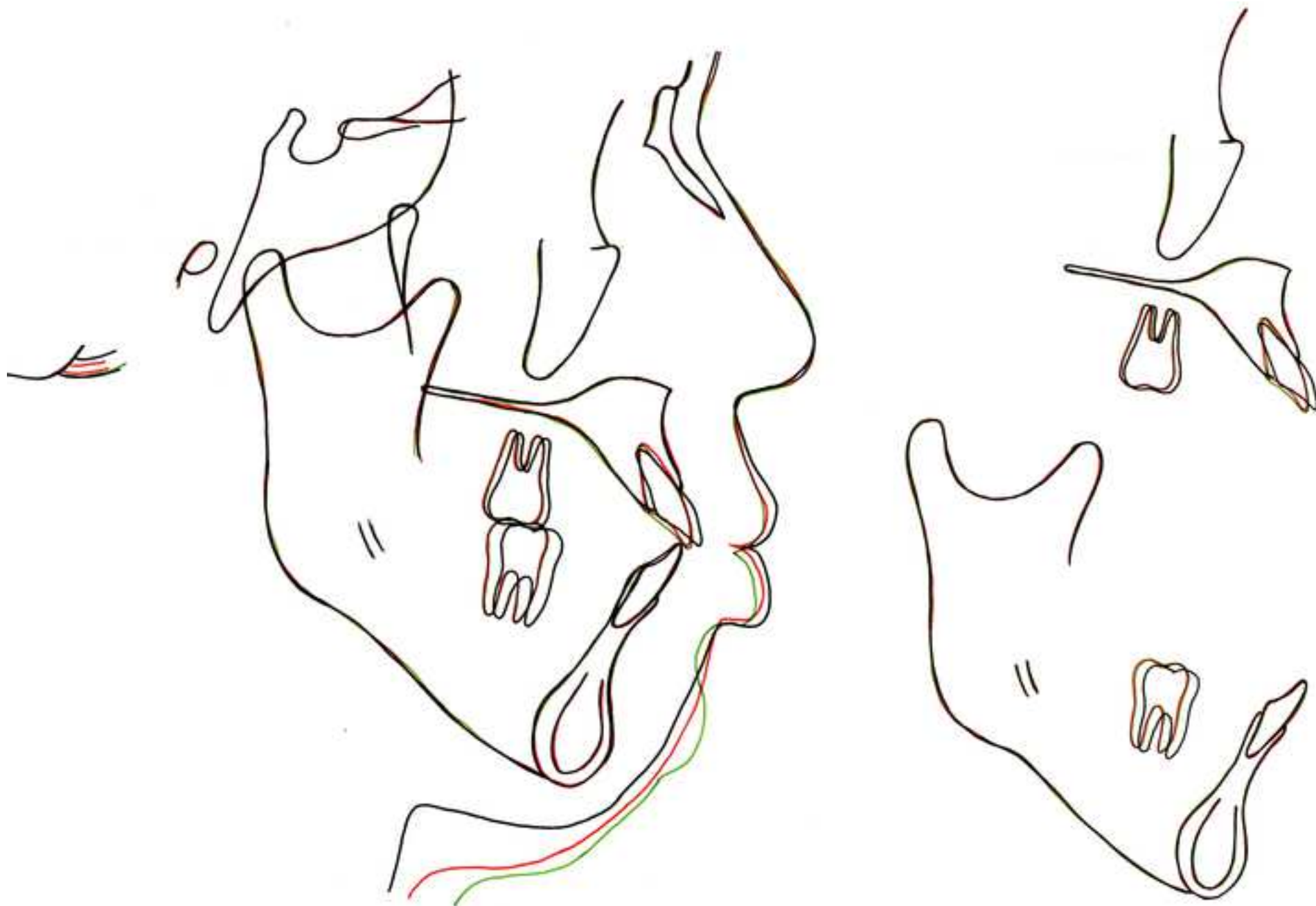








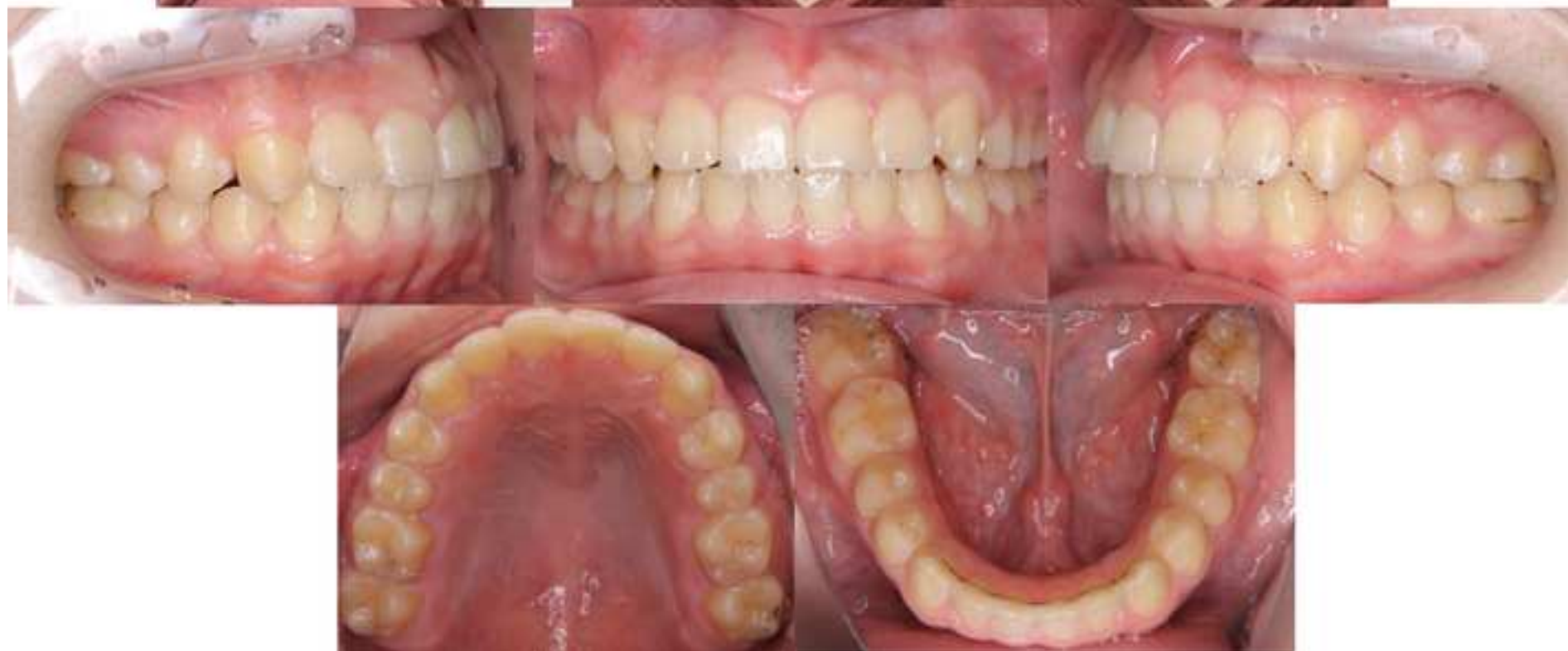
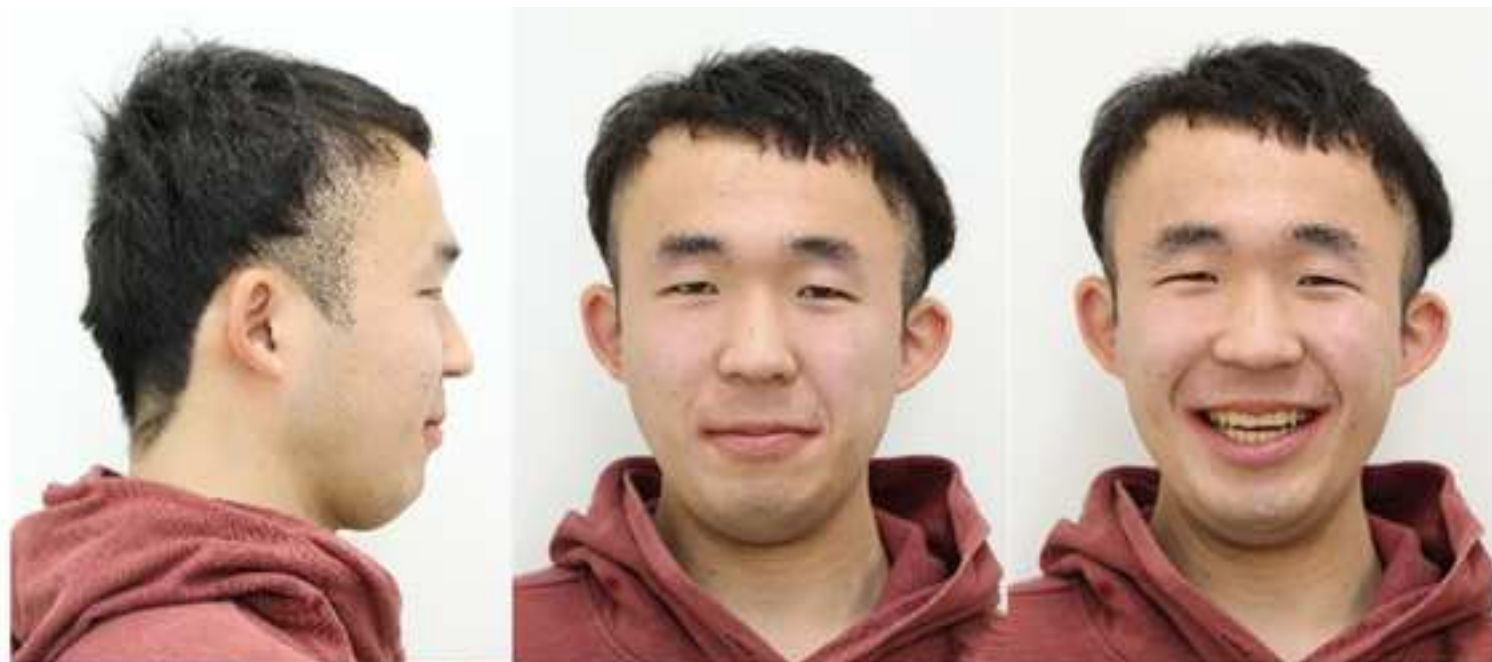


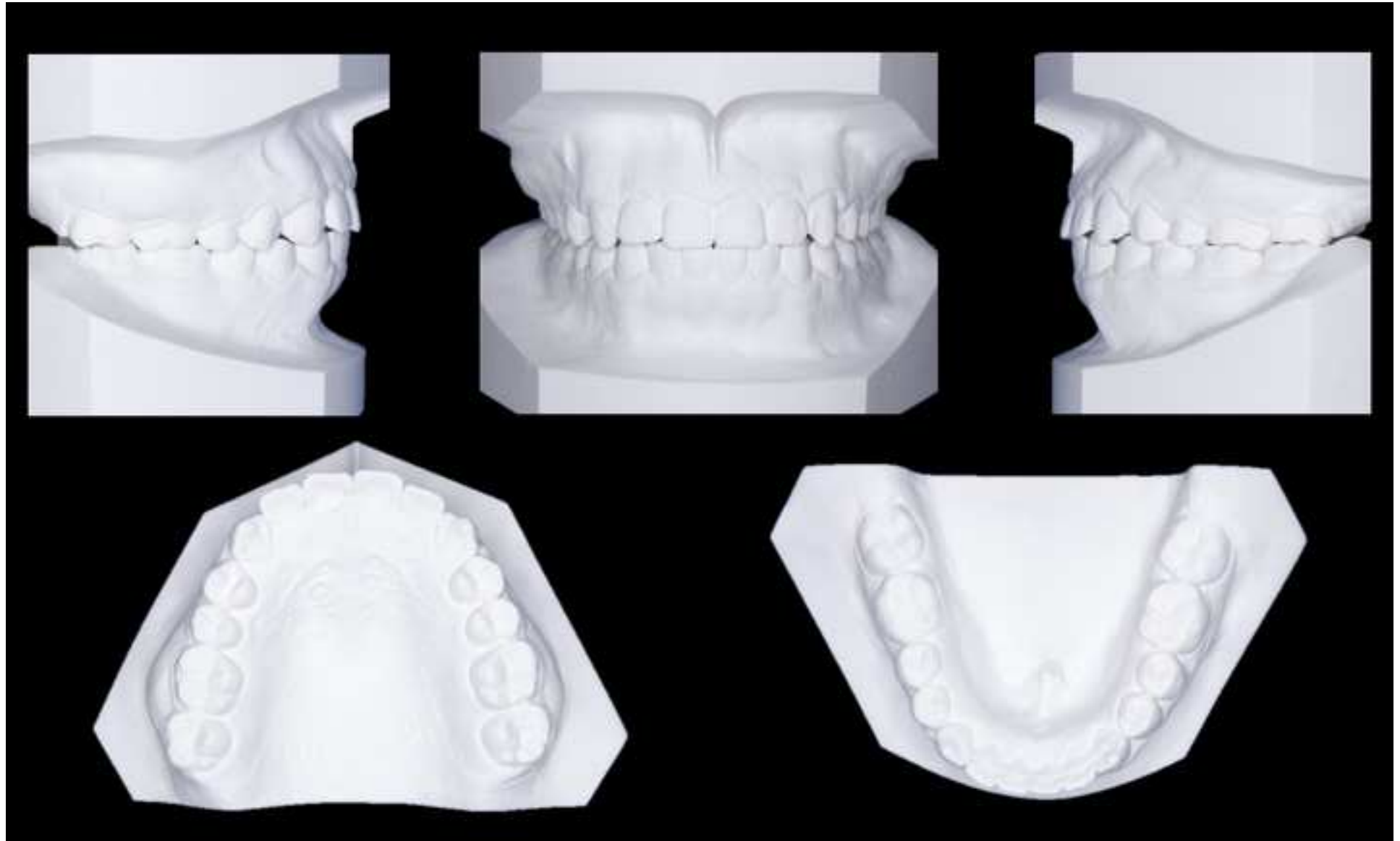



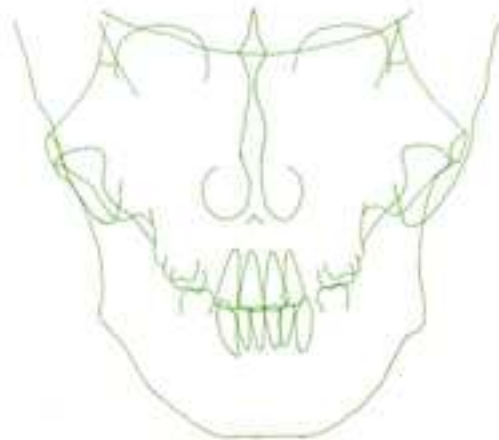




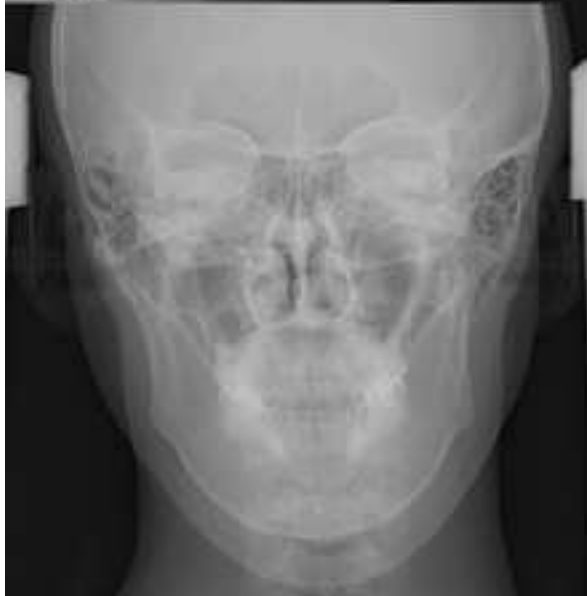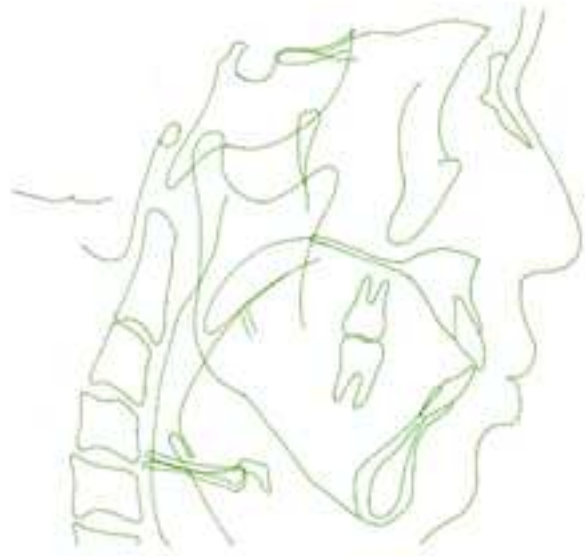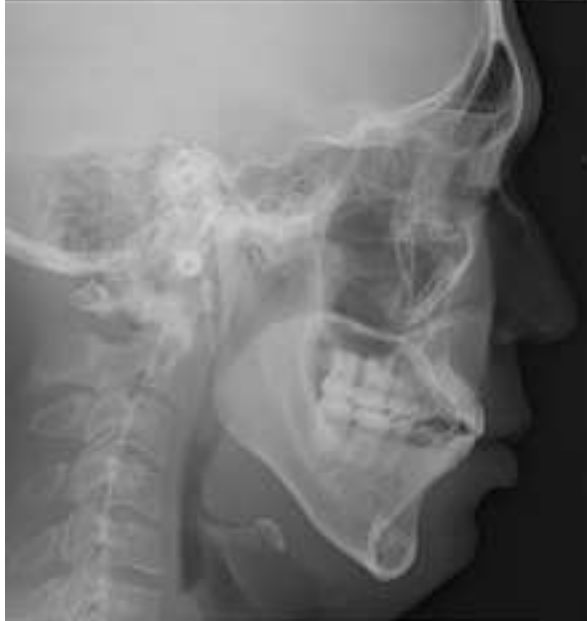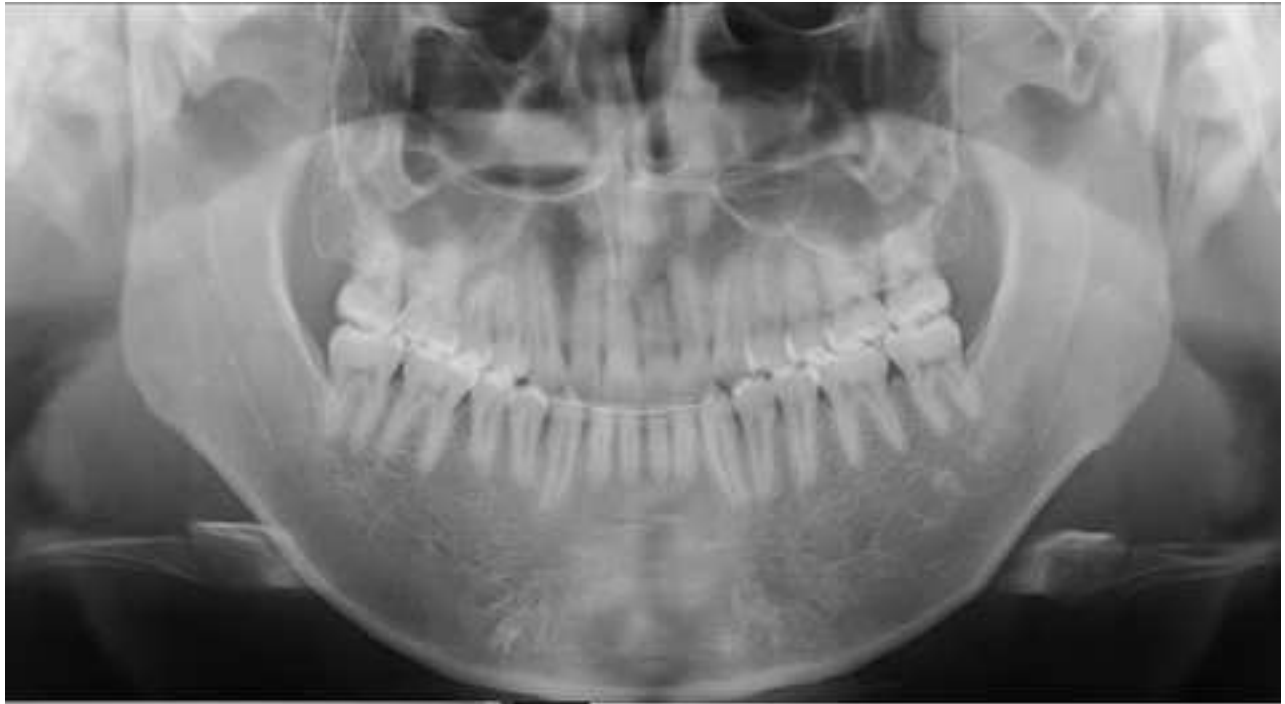Table I. Lateral cephalometric summary

Variables	Mean, Japanese male*								After initial	After phase	Before phase	Posttreatment	After 1 year	
	10 y	SD	12 y	SD	14 y	SD	Adult	SD	Pretreatment	treatment	1 treatment	2 treatment	19 y 6 m	retention
									10 y	11 y	14 y	16 y		20 y 6 m
Angle (°)														
ANB	4.2	1.8	4.3	2.2	3.7	2.3	3.2	2.4	0.0	3.6	4.3	3.8	3.6	3.6
SNA	81.8	3.4	81.6	3.4	81.9	3.6	81.5	3.3	79.0	78.9	78.6	78.7	78.7	78.7
SNB	77.5	3.1	77.2	3.7	78.1	4.1	78.2	4.0	79.0	75.3	74.3	74.8	75.1	75.1
FMA	30.8	4.3	30.6	5.1	29.2	5.8	28.0	6.1	31.5	34.5	35.7	37.3	36.4	36.4
Gonial angle	126.3	5.2	125.0	5.9	123.3	6.6	120.9	6.5	134.3	132.5	131.6	133.9	133.8	133.8
U1-SN	104.1	5.6	105.0	7.1	106.6	8.5	106.0	7.5	110.2	116.1	112.0	111.8	102.8	104.9
L1-MP	93.2	6.8	95.7	5.4	96.7	6.0	95.2	6.2	87.3	77.5	91.0	90.3	89.9	90.0
Interincisal angle	125.3	11.2	122.2	8.8	120.8	8.9	124.2	8.6	119.9	120.3	110.0	110.2	120.6	118.4
Occlusal plane	19.3	3.7	17.9	3.2	16.1	3.3	15.5	4.2	16.6	13.8	16.0	15.9	16.4	17.0
Linear (mm)														
S-N	66.1	2.5	68.5	2.8	70.8	3.2	72.2	3.3	73.7	75.0	78.0	79.3	79.3	79.3
N-Me	116.3	4.1	123.4	4.7	130.5	4.7	135.7	4.0	131.2	136.9	148.3	150.7	150.4	150.4
Ar-Go	42.5	2.6	44.9	3.7	49.3	4.9	53.2	5.7	49.6	50.9	55.1	56.3	56.3	56.3
Go-Me	64.6	2.8	69.1	4.4	73.3	5.1	76.6	4.4	68.9	70.8	74.2	75.0	75.0	75.0
Ar-Me	97.7	3.0	103.4	5.9	110.5	6.8	115.6	6.8	111.4	111.6	120.7	121.7	121.7	121.7
Me/PP	63.1	3.3	66.6	3.3	71.0	3.4	74.6	3.0	72.6	74.2	81.9	83.7	83.4	83.4
Overjet	3.3	1.4	3.4	1.2	3.0	1.3	3.3	1.0	-1.7	7.0	3.6	3.9	1.3	1.4
Overbite	3.5	2.6	3.5	1.5	3.0	1.6	3.3	1.7	0.4	2.5	0.1	0.5	1.1	1.9

\*Wada et al.<sup>15</sup>

ANB, Anteroposterior relation between the maxilla and mandible; SNA, Anteroposterior position of the maxilla relative to the anterior cranial base;

SNB, Anteroposterior position of the mandible relative to the anterior cranial base; FMA, Divergency of the mandibular plane relative to Frankfort horizontal plane;

Gonial angle, angle between the mandibular and ramus planes; U1-SN, Maxillary central incisal axis to sella-nasion plane;

L1-MP, Mandibular central incisal axis to mandibular plane; Interincisal angle, angle between maxillary and mandibular central incisal axes;

Occlusal plane, occlusal plane angle to sella-nasion plane; S-N, Anteroposterior length of the anterior cranial base; N-Me, Anterior facial height;

Ar-Go, Length of the mandibular ramus; Go-Me, Length of the mandibular corpus; Ar-Me, Total length of the mandible; Me/PP, Lower anterior facial height;



Table II. Frontal cephalometric summary

Variables	Mean, Japanese male*								After initial	After phase	Before phase	Posttreatment	After 1 year	
	10 y	CD	12 y	CD	14 y	CD	Adult	CD	Pretreatment	treatment	1 treatment		2 treatment	16 y
Denture midline (mm)	0.0	1.5	0.0	1.5	0.0	1.5	0.0	1.5	-3.4	-2.7	-2.7	-3.4	0.0	0.2
Maxillomandibular midline (°)	0.0	1.5	0.0	1.5	0.0	1.5	0.0	1.5	-5.2	-3.8	-4.0	-4.0	-3.5	-3.5
Occlusal plane tilt (mm)	0.0	1.1	0.0	1.1	0.0	1.1	0.0	1.1	-1.8	-0.6	-0.8	-1.1	-0.4	-0.4
Postural symmetry (°)	0.0	2.0	0.0	2.0	0.0	2.0	0.0	2.0	1.0	2.0	1.8	0.2	0.6	0.6

\*Nezu et al.<sup>19</sup> CD: Clinical deviation

Denture midline, Distance between the maxillary and mandibular dental midlines

Maxillomandibular midline, The angle formed between the ZR-ZL plane and the ANS-ME plane

Occlusal plane tilt, Difference between the measurements from the ZR-ZL line to the occlusal plane at the level of left and right molars

Postural symmetry, Difference between angles ZL-AG-ZA on the left and ZR-AG-ZA on right side



## **Photo Release**

**Must be signed by the patient and/or the parent.**

I consent to the taking of records, including photographs, and x-rays, before, during, and after treatment, and to the use of the records by my doctor in scientific papers, demonstrations, and all forms and media.

Patient's name Yuma Tada Signature Yuma Tada

Parent's name \_\_\_\_\_ Signature \_\_\_\_\_

Doctor's name \_\_\_\_\_ Signature \_\_\_\_\_

Date March 19, 2021

*Return to:*

American Journal of Orthodontics and Dentofacial Orthopedics

Orthodontics, School of Dentistry

D-569. Health Sciences Box 357446

Seattle, WA 98195

206-221-5413, phone