

## ORIGINAL

# Location of ethmoidal arteries in relation to ethmoid cells and the anterior skull base

Seiichiro Kamimura<sup>1</sup>, Keisuke Ishitani<sup>1</sup>, Hitoshi Shono<sup>1</sup>, Ryo Kanamura<sup>1</sup>, Tatsuya Fujii<sup>2</sup>, Eiji Kondo<sup>1</sup>, Takahiro Azuma<sup>1</sup>, Go Sato<sup>1</sup>, and Yoshiaki Kitamura<sup>1</sup>

<sup>1</sup>Department of Otolaryngology-Head and Neck Surgery, Institute of Biomedical Sciences, Tokushima University Graduate School, Tokushima, Japan, <sup>2</sup>Department of Otolaryngology, JA Kochi Hospital, Kochi, Japan

**Abstract : Background :** Ethmoidal arteries are at risk of accidental injury during endoscopic sinus surgery (ESS). **Aims/Objectives :** We aimed to examine the location of ethmoidal arteries in relation to ethmoid cells and the anterior skull base (ASB) in Japanese patients. **Material and Methods :** CT images of 100 sides of 50 patients were retrospectively reviewed. The location of anterior ethmoidal arteries (AEAs), middle ethmoidal arteries (MEAs) and posterior ethmoidal arteries (PEAs) in relation to ethmoidal cells and their distance from the ASB were evaluated. **Results :** AEAs and PEAs were present in all sides. 60% of AEAs and 9% of PEAs ran below the level of ASB. MEAs were present in 21 sides and ran below the ASB in 23.8% (5/21) of these sides. The incidence of AEAs running below the level of ASB was significantly higher in the sides with supraorbital ethmoid cells (SOECs) than in those without SOECs. **Conclusion and significance :** This study revealed the position and the distance from ASB of AEAs, PEAs, and MEAs in relation to ethmoid cells in Japanese patients. In cases with SOECs, surgeons should be careful not to injure the AEAs running below the level of ASB. *J. Med. Invest.* 71:273-278, August, 2024

**Keywords :** ethmoidal arteries, ethmoid cells, anterior skull base

## INTRODUCTION

Endoscopic sinus surgery (ESS) is the primary surgical treatment for chronic rhinosinusitis (CRS). Complete removal of ethmoid cells is necessary to reduce the recurrence of CRS after ESS (1, 2). However, ethmoidal arteries are at risk of accidental injury near the anterior skull base (ASB) during complete removal of ethmoid cells in ESS. Damage to the ethmoidal artery causes severe intraoperative bleeding, and sometimes leads to intraorbital bleeding, which may induce dysopsia (3). In particular, the risk of these injuries is higher when ethmoidal arteries run below the level of ASB (4). Moreover, anterior ethmoidal arteries in the tiny thin bone of lateral lamella of the cribriform plate are at risk of cerebrospinal fluid leak and subsequent meningitis during ESS. Therefore, preoperative identification of the location of ethmoidal arteries and their distance from the ASB is important to reduce the risk of accidental injury to ethmoidal arteries during ESS.

A systematic review of 10 studies reported that 14.3–84.0% of anterior ethmoidal arteries (AEAs) run below the level of ASB (4). Some authors reported a correlation between the presence of supraorbital ethmoid cells (SOECs) and the distance between AEAs and the ASB, that is, well-pneumatized SOECs cause AEAs to be located farther away from the ASB (5, 6). SOECs are rarely present in Asians, but when present, the frequency of AEAs running below the level of ASB is high (7). It has also been reported that 8% of posterior ethmoidal arteries (PEAs) run below the level of ASB (8). The middle ethmoidal artery (MEA) is often absent, and its presence was reportedly 21–31.8% (9–11). Twenty-five percent of MEAs run below the level of ASB

(10); however, only a few authors have reported on the MEA. Furthermore, limited data exist on the location of ethmoidal arteries in relation to ethmoid cells according to the international frontal sinus anatomy classification (IFAC) and the incidence of ethmoidal arteries running below the level of ASB in Japanese subjects.

The present study aimed to examine the location of AEAs, MEAs, and PEAs and their distance from the ASB by performing computed tomography (CT) scan on Japanese patients. We also analyzed the relationship between the presence of supra-bullar cells (SBCs), suprabullar frontal cells (SBFCs), or SOECs and the incidence of AEAs running below the level of ASB. This study is the first attempt to evaluate the distance from the ASB and location of AEAs, MEAs, and PEAs simultaneously in the same Japanese patient.

## MATERIAL AND METHODS

### Subjects

One hundred sides of 50 Japanese patients (28 men and 22 women; mean age, 53.6 years) who underwent sinonasal CT before ESS or septoplasty were retrospectively reviewed. The diagnostic details were as follows: CRS (n = 34), allergic rhinitis (n = 7), septal deviation (n = 6), maxillary cyst (n = 2), and benign tumor without bone destruction (n = 1). Patients with a history of sinus surgery or bone destructive lesions, such as malignancies or fungal lesions, were excluded.

All patients underwent CT with 1 mm thick slice images on a Siemens SOMATOM Sensation 16 (Siemens, Berlin, Germany) at the Department of Otorhinolaryngology, Tokushima University Hospital between April 2018 and March 2019. Multiplanar reconstruction images were used to categorize ethmoid cells in the frontal recess and evaluate the location of the AEA, MEA, and PEA and their distance from the ASB. Ethmoid cells in the frontal recess were classified according to IFAC (12).

The measurement of the ethmoidal artery distance from

Received for publication April 1, 2024; accepted June 17, 2024.

Address correspondence and reprint requests to Yoshiaki Kitamura, MD., PhD, Department of Otolaryngology, Institute of Biomedical Sciences, Tokushima University Graduate School, 3-18-15 Kuramoto, Tokushima 770-8503, Japan and Fax: +81-88-633-7170. E-mail: ykitamura@tokushima-u.ac.jp

the ASB was based on the sagittal view because sagittal view most clearly expresses the relationship between the inclination of the skull base and the ethmoidal arteries. The distance was measured at the point where the ethmoidal arteries were most distant from the ASB with a thin bony mesentery (Fig. 1A, 1B), since the point was considered at the highest risk of intraoperative injury.

We classified the location of the AEA as follows : (1) at the posterior edge of the frontal sinus ; (2) at the roof of SBCs, SBFCs, or SOECs ; (3) at the posterior edge of SBCs, SBFCs, or SOECs ; and (4) between the ethmoidal bulla roof and the third lamella (Fig. 2).

In the same way, we classified the location of the PEA with respect to posterior ethmoidal cells : (A) anterior to posterior ethmoidal cells, (B) in the anterior wall of posterior ethmoidal

cells, (C) at the roof of posterior ethmoidal cells, and (D) in the posterior wall of posterior ethmoidal cells (Fig. 3). We also examined the MEA and measured its distance from the ASB.

Two otorhinolaryngologists performed the measurements and classification. This study was approved by the ethics committee of Tokushima University Hospital (3526).

#### Statistical analysis

The age of AEAs and PEAs and their distance from the ASB are expressed as mean  $\pm$  standard deviation. The location of AEAs and PEAs in ethmoidal cells were assessed, and the relationship between the distance and location of AEAs were analyzed using the chi-squared test with GraphPad Prism software (GraphPad Software Inc., La Jolla, CA, USA). Statistical significance was set at  $p < 0.05$ .

Fig. 1A

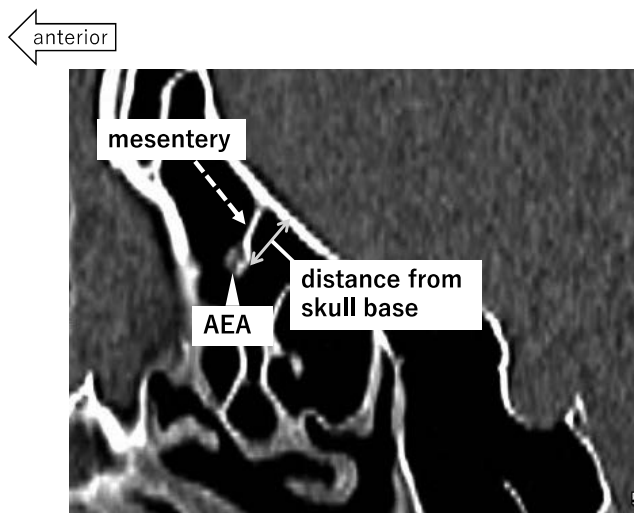


Fig. 1B

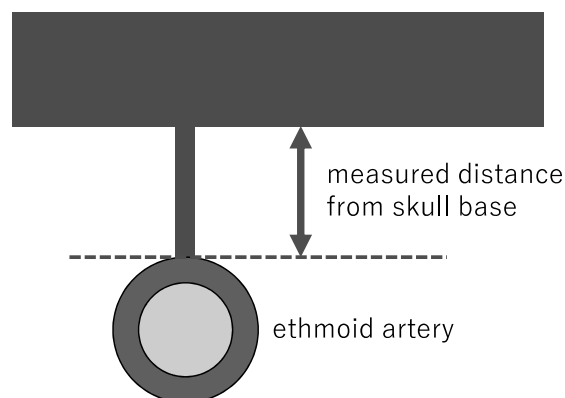


Fig. 1. An example of a measurement of the ethmoidal artery distance from the anterior skull base. The measurement was based on the sagittal view. The distance was measured at the point where ethmoidal arteries were most distant from the anterior skull base with a thin bony mesentery. AEA : anterior ethmoidal artery.

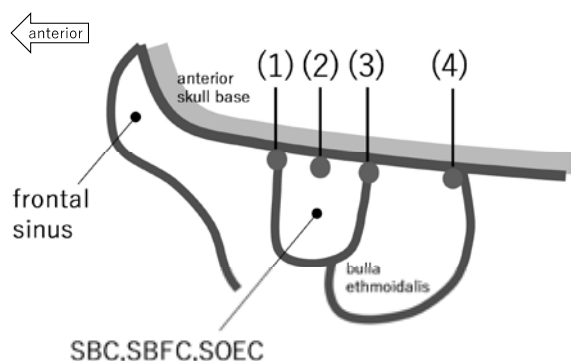


Fig. 2. Classification of the location of anterior ethmoidal arteries (AEAs). We classified the location of AEAs as follows : (1) at the posterior edge of the frontal sinus ; (2) at the roof of suprabullar cells (SBCs), suprabullar frontal cells (SBFCs), or supraorbital ethmoid cells (SOECs) ; (3) at the posterior edge of SBCs, SBFCs, or SOECs ; (4) between the ethmoidal bulla roof and the third lamella. AEA : anterior ethmoidal artery, SBC : suprabullar cell, SBFC : suprabullar frontal cell, SOEC : supraorbital ethmoid cell.

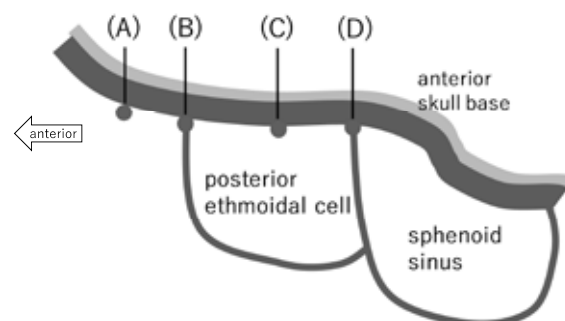


Fig. 3. Classification of the location of posterior ethmoidal arteries (PEAs). We classified the location of PEAs as follows : (A) anterior to posterior ethmoidal cells, (B) in the anterior wall of posterior ethmoidal cells, (C) at the roof of posterior ethmoidal cells, (D) in the posterior wall of posterior ethmoidal cells. PEA : posterior ethmoidal artery.

## RESULTS

CT images of 100 sides of 50 patients were analyzed in this study. AEAs ran below the level of ASB in 60 sides (60.0%) and ran at the level of the ASB in 40 sides (40.0%) (Fig. 4). In the 60 sides, the mean distance of AEAs from the ASB was  $4.3 \pm 1.5$  mm (range 1.2–7.7 mm). Among the 60 sides, 21.7% (13/60) of AEAs ran below the level of skull base at the posterior edge of the frontal sinus at a distance of  $4.2 \pm 1.5$  mm from the ASB, 15.0% (9/60) ran below the level of skull base at the roof of frontal recess cells (SBCs, SBFCs, or SOECs) at a distance of  $3.9 \pm 1.5$  mm from the ASB, 60.0% (36/60) ran below the level of skull base at the posterior wall of frontal recess cells at a distance of  $4.4 \pm 1.5$  mm from the ASB, and 3.3% (2/60) ran below the level of skull base between the ethmoid bulla roof and the third lamella at a distance of  $3.1 \pm 0.3$  mm from the ASB (Table 1).

SOECs were seen in 25 of 100 sides, and the AEA ran below the level of ASB in 22 of 25 sides (88.0%). The mean distance between the AEA and ASB was  $4.9 \pm 1.4$  mm (range 2.1–7.7 mm). Among the remaining 75 sides without SOECs, the AEA ran below the level of ASB in 38 sides (50.7%), and the mean distance between the AEA and ASB was  $3.9 \pm 1.4$  mm (range 1.2–6.3 mm). The rate and distance of AEAs running below the level of ASB with SOECs were significantly higher than those without SOECs ( $p < 0.05$ ; Fig. 5A). SBFCs and SBCs were observed in

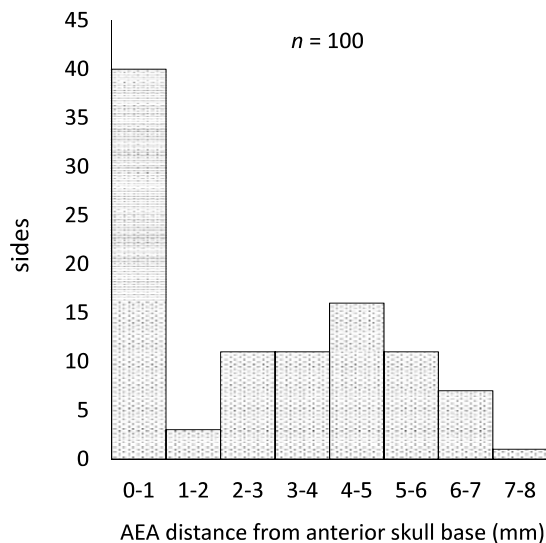


Fig. 4. Number of sides per anterior ethmoidal artery (AEA) distance from the anterior skull base. AEAs were distant from the skull base in 60 of 100 sides (60.0%). AEA : anterior ethmoidal artery, SBC : suprabullar cell, SBFC : suprabullar frontal cell, SOEC : supraorbital ethmoid cell.

17 and 62 of 100 sides, respectively ; however, no difference was observed in the rate of AEAs running below the level of the ASB with or without these cells (Fig. 5B, 5C).

The PEA ran at the level of the ASB in 91 sides (91.9%) and ran below the level of ASB in only nine sides (9.0%). In these nine sides, the mean distance between the PEA and the ASB was  $3.6 \pm 0.7$  mm (range 2.5–4.9 mm) and the PEA was mostly located at the roof or in the anterior wall of posterior ethmoidal cell (Table 2).

The MEA was present in 21 of 100 sides (21.0%) and ran below the level of ASB in five of 21 sides (23.8%). In these five sides, the mean distance between the MEA and the ASB was  $2.3 \pm 0.9$  mm (range 1.4–3.5 mm) (Table 3).

## DISCUSSION

In the present study, 60.0% of AEAs ran below the level of ASB. This rate was relatively high compared to that in previous reports (1, 13, 14). In a systematic review of anatomical variations of AEAs (2), AEAs ran below the level of ASB in 14.3–84.0%, and only two reports among Asians were included. Moon *et al.* in Korea reported that 14.3% of AEAs ran below the level of ASB when evaluated by CT scan and cadaver dissection (14). Yang *et al.* in China reported that 83.3% of AEAs ran below the level of ASB in cadavers (15). A study in Malaysia reported that 37.3% of AEAs ran below the level of ASB as shown by CT scan (13). It was recently reported that 51.9% of Japanese patients have AEAs running below the level of ASB (7). These discrepancies may be attributed to differences in race and analysis methods (15). In our study, the target population was limited to patients who underwent CT before nasal surgery. The average age of patients undergoing sinus and nasal septal surgery may be higher. The distance of ethmoidal artery from ASB was reported to be positively correlated with older age (9). This may be a reason why the rate of AEAs that ran below the level of ASB in this study was relatively high compared to that in previous reports. However, it is noteworthy that AEAs ran below the level of ASB in approximately half of Japanese patients before nasal surgery.

In the present study, the mean distance between the AEA and ASB was  $4.3 \pm 1.5$  mm (range 1.2–7.7 mm). Simmen *et al.* reported that the mean distance between the AEA and ASB was 3.5 mm (range 1–8 mm), which was similar to our results (5). However, Abdullah *et al.* reported that the mean distance between the AEA and ASB was 1.93 mm, which is less than that observed in this study (4). However, Abdulla *et al.* calculated the mean distance, including cases with a distance of 0 mm between the AEA and ASB. In the 60 sides with AEAs running below the level ASB, most AEAs were more than 2 mm away from the ASB with mesentery. If the AEA was more than 2 mm away from the ASB,

Table 1.

Location of AEA	at the skull base	distant from skull base (mean distance from skull base)
(1) at the posterior edge of the frontal sinus	8	13 ( $4.2 \pm 1.5$ mm)
(2) at the roof of the SBC, SBFC or SOEC	4	9 ( $3.9 \pm 1.5$ mm)
(3) at the posterior edge of the SBC, SBFC or SOEC	18	36 ( $4.4 \pm 1.5$ mm)
(4) between the ethmoidal bulla roof and the third lamella	10	2 ( $3.1 \pm 0.3$ mm)
total	40	60 ( $4.3 \pm 1.5$ mm)
		range 1.2 - 7.7 mm

Fig. 5A

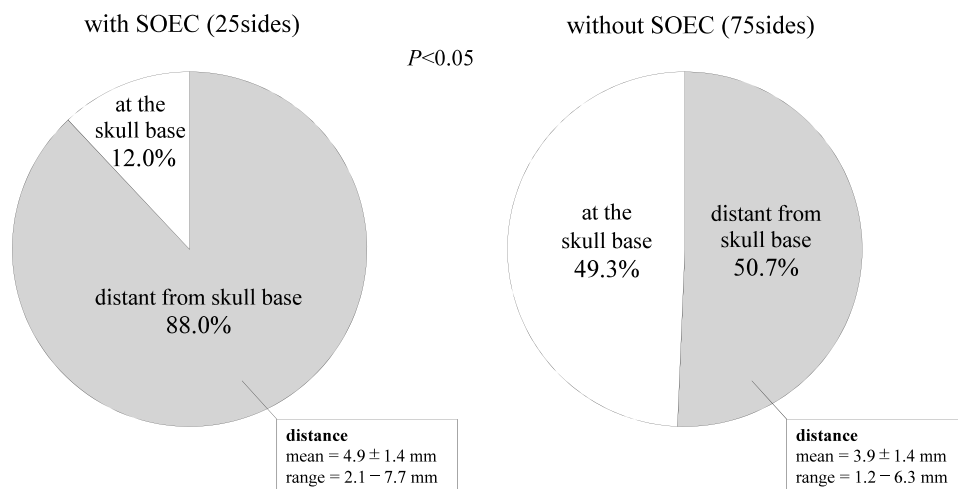


Fig. 5B

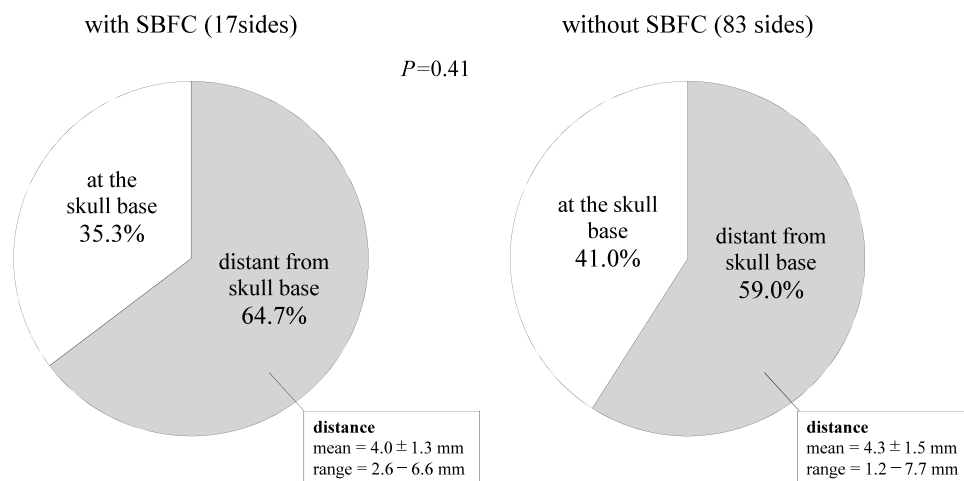


Fig. 5C

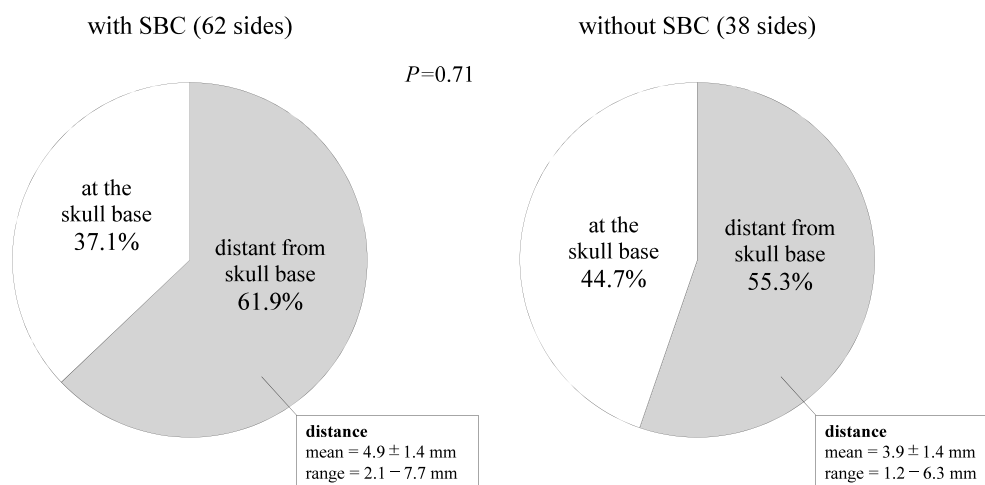


Fig. 5. Analysis of the relationship between the presence of supraorbital ethmoid cells (SOECs), suprabullar cells (SBCs), and the anterior ethmoidal artery (AEA) distance from the anterior skull base. (A) The rate of AEAs distant from the skull base in the sides with SOECs is significantly higher than those without SOECs ( $p < 0.05$ ). (B,C) No significant difference was observed in the rate of AEAs distant from the anterior skull base between the sides with and without SBFCs and SBCs. AEA : anterior ethmoidal artery, SBC : suprabullar cell, SBFC : suprabullar frontal cell, SOEC : supraorbital ethmoid cell.

Table 2.

Location of PEA	at the skull base	distant from skull base
(A) anterior to posterior ethmoidal cell	13	1
(B) in the anterior wall of posterior ethmoidal cell	34	3
(C) at the roof of posterior ethmoidal cell	41	4
(D) in the posterior wall of posterior ethmoidal cell	3	1
total	91	9
mean distance from skull base in the above 9 sides		3.6 ± 0.7 mm
range		2.5 - 4.9 mm

Table 3.

Presence of MEA	21/100 (21%)
Location of MEA	
at the skull base	16
distant from skull base	5
mean distance from skull base in the above 5 sides	2.3 ± 0.9 mm
range	1.4 - 3.5 mm

the risk of injury by cutting forceps, such as Gruenwald nasal forceps, was higher (Fig. 4). These results suggest that more than half of the AEAs are at risk of forceps injury during ESS.

Thirty six of the 60 sides with AEAs running below the level of ASB were located at the posterior edge of the SBCs, SBFCs, or SOECs. Identifying the location of the AEA during ESS and avoiding AEA injury are important to prevent intraoperative bleeding and eye complications (5). During frontal sinus surgery, surgeons usually remove frontal recess cells along a drainage pathway, identifying SBCs, SBFCs, or SOECs according to IFAC. Therefore, a preoperative understanding of the locational relationship between the AEA and ethmoid cells in the frontal recess, such as the SBCs, SBFCs, and SOECs, is useful to prevent accidental injury to the AEA. Although some authors have classified AEA location by the number of septa between the frontal sinus and the AEA (10), this is sometimes difficult to count before identifying the frontal sinus when removing frontal recess cells. Therefore, it is clinically useful to identify the AEA location in relation to SBCs, SBFCs, SOECs, or the bulla using landmarks during ESS. Because 60% of AEAs running below the level of ASB were located at the posterior edge of SBCs, SBFCs, or SOECs, surgeons are advised to identify these cells based on the relationship of the AEA with the uncinate process and agger nasi cells, then carefully remove the posterior wall of SBCs, SBFCs, or SOECs according to preoperative CT findings.

In the present study, SOECs were observed in 25 of 100 sides (25%), and the rate and distance of AEAs running below the level of ASB were significantly higher in patients with SOECs than in patients without SOECs. The presence of SOECs was reported to influence the relationship between the AEA and ASB (5-7), and AEAs in patients with well pneumatized SOECs are more likely to be located distant from the ASB (5, 6). Racial differences were also reported to be associated with the presence of SOECs, and the prevalence of SOECs was significantly higher in the European population (64.6%) than in the Korean population (2.6%) (16). In addition, the Caucasian population had a significantly higher prevalence of SOECs than Asians, including Japanese (6.0%), Taiwanese (7.7%), and Chinese (5.4%) (17).

These findings suggest that the rate of AEAs running below the level of ASB was higher in patients with SOECs, particularly in those with well pneumatized SOECs, and Caucasians had a higher prevalence of SOECs than Asians. Further studies on AEAs running below the level of ASB with SOECs in Asians are necessary for comparison with Caucasians. Therefore, surgeons should identify SOECs intraoperatively according to preoperative CT findings and then carefully remove the wall, including AEAs running below the level of ASB, to protect AEAs from injury when operating on the frontal recess.

In the present study, 9% of PEAs ran below the level of ASB, which was lower than that of AEAs and consistent with previous reports (8, 10). However, all nine sides with PEAs were > 2.5 mm away from the ASB and considered at risk of injury by forceps. In addition, most PEAs running below the level of ASB were located in the anterior wall or at the roof of the most posterior ethmoidal cell. PEAs were reportedly located between the third (middle turbinate) and fifth lamellae (anterior wall of the sphenoid sinus); 35.7% of PEAs were between the third and fourth lamellae (superior turbinate), 28.6% were in the fourth lamella, and 35.7% were between the fourth and fifth lamellae (10). However, the location of PEAs running below the level of ASB, which are at risk of injury, remains to be elucidated. Our study suggests that surgeons should identify the most posterior ethmoidal cell in reference to the sphenoid sinus and ASB intraoperatively, then carefully remove the wall, including PEAs running below the level of ASB according to preoperative CT findings, especially the anterior wall and mesentery from the roof during ESS.

In the present study, the MEA was present in 21.0% of the sides, and ran below the level of ASB in five of 21 sides (23.8%). AEAs and PEAs have been reportedly present in all cases, with the MEA being present in only eight of 28 sides (28.6%) (10), running below the level of ASB in two of eight sides (25%). Our results are consistent with this report. Although the distance from below the ASB is relatively small (2.3 mm) compared to that of AEAs and PEAs, surgeons should take note of the MEA running below the level of ASB before surgery.

This study simultaneously evaluated the distance of the

AEAs, PEAs, and MEAs from the skull base in the same Japanese patients. AEAs often run below the ASB, and is at high risk of injury. In addition, although the risk is lower for the MEAs and PEAs than AEAs, MEAs and PEAs run below the ASB in some cases. These results are useful for rhinologists not to injure ethmoidal arteries when performing ESS on Japanese patients.

A limitation of our study is that the location of ethmoidal arteries was not confirmed during surgery. However, it was reported that CT and intraoperative or autopsy findings of ethmoidal arteries were in agreement, suggesting that CT findings are highly reliable for the analysis of these locations (10, 18). The second limitation is that the target population included only Japanese patients who underwent CT examination before nasal surgery.

## CONCLUSION

In this study on Japanese patients, 60% of AEAs, 5% of MEAs, and 9% of PEAs ran below the level of ASB. Sixty percent of AEAs running below the level of ASB were located at the posterior edge of SBCs, SBFCs, or SOECs, and the rate and distance of AEAs running below the level of ASB were significantly higher in the sides with SOECs than in those without SOECs. Most PEAs running below the level of ASB were located on the roof or anterior wall of the most posterior ethmoidal cell. These findings suggest that surgeons should identify SBCs, SBFCs, or SOECs and the most posterior ethmoidal cell using nearby landmarks intraoperatively, and carefully remove the walls, including ethmoidal arteries running below the level of ASB, according to preoperative CT findings, especially the posterior wall of SOECs and the anterior wall and mesentery from the roof of the most posterior ethmoidal cell to avoid AEA and PEA injuries, respectively.

## DECLARATION OF INTEREST

The authors declare no conflict of interest.

## ACKNOWLEDGEMENTS

We would like to thank Editage ([www.editage.jp](http://www.editage.jp)) for English language editing.

## REFERENCE

- Okushi T, Mori E, Nakayama T, Asaka D, Matsuwaki Y, Ota K, Chiba S, Moriyama H, Otori N : Impact of residual ethmoid cells on postoperative course after endoscopic sinus surgery for chronic rhinosinusitis. *Auris Nasus Larynx* 39 : 484-489, 2012
- Nakayama T, Asaka D, Kuboki A, Okushi T, Kojima H : Impact of residual frontal recess cells on frontal sinusitis after endoscopic sinus surgery. *Eur Arch Otorhinolaryngol* 275 : 1795-1801, 2018
- Ohnishi T, Tachibana T, Kaneko Y, Esaki S : High-risk areas in endoscopic sinus surgery and the prevention of complications. *Laryngoscope* 103 : 1181-1185, 1993
- Abdullah B, Lim EH, Husain S, Snidvongs K, Wang Y : Anatomical variations of anterior ethmoidal artery and their significance in endoscopic sinus surgery : a systematic review. *Surg Radiol Anat* 41 : 491-499, 2019
- Simmen D, Raghavan U, Briner HR, Manestar M, Schuknecht B, Groscurth P, Jones NS : The surgeon's view of the anterior ethmoid artery. *Clin Otolaryngol* 31 : 187-191, 2006
- Özdemir A, Bayar Muluk N, Bekin Sarikaya PZ, Yilmazsoy Y : Supraorbital ethmoid cells (SOECs), anterior ethmoid artery notch and ethmoid roof relation in PNSCT. *J Clin Neurosci* 110 : 7-11, 2023
- Takeda T, Kajiwaru R, Omura K, Otori N, Wada K : Analysis of anatomical variation of the inclination of lamellas attached to the skull base and its correlation with the anterior ethmoidal artery floating in the ethmoid sinus for use in endoscopic sinus surgery. *Surg Radiol Anat* 42 : 995-1002, 2020
- Cankal F, Apaydin N, Acar HI, Elhan A, Tekdemir I, Yurdakul M, Kaya M, Esmer AF : Evaluation of the anterior and posterior ethmoidal canal by computed tomography. *Clin Radiol* 59 : 1034-1040, 2004
- Yamamoto H, Nomura K, Hidaka H, Katori Y, Yoshida N : Anatomy of the posterior and middle ethmoidal arteries via computed tomography. *SAGE Open Med* 6 : 1-7, 2018
- Ferrari M, Pianta L, Borghesi A, Schreiber A, Ravanelli M, Mattavelli D, Rampinelli V, Belotti F, Rodella LF, Maroldi R, Nicolai P : The ethmoidal arteries : a cadaveric study based on cone beam computed tomography and endoscopic dissection. *Surg Radiol Anat* 39 : 991-998, 2017
- Wang L, Youseef A, Al Qahtani AA, Gun R, Prevedello DM, Otto BA, Ditzel L, Carrau RL : Endoscopic anatomy of the middle ethmoidal artery. *Int Forum Allergy Rhinol* 4 : 164-168, 2014
- Wormald PJ, Hoseman W, Callejas C, Weber RK, Kennedy DW, Citardi MJ, Senior BA, Smith TL, Hwang PH, Orlandi RR, Kaschke O, Siow JK, Szczygielski K, Goessler U, Khan M, Sprekelsen MB, Kuehnel T, Psaltis A : The international frontal sinus anatomy classification (IFAC) and classification of the extent of endoscopic frontal sinus surgery. *Int Forum Allergy Rhinol* 6 : 677-696, 2016
- Abdullah B, Lim EH, Mohamad H, Husain S, Aziz ME, Snidvongs K, Wang DY, Musa KI : Anatomical variations of anterior ethmoidal artery at the ethmoidal roof and anterior skull base in Asians. *Surg Radiol Anat* 41 : 543-550, 2019
- Moon HJ, Kim HU, Lee JG, Chung IH, Yoon JH : Surgical anatomy of the anterior ethmoidal canal in ethmoid roof. *Laryngoscope* 111 : 900-904, 2001
- Yang YX, Lu QK, Liao JC, Dang RS : Morphological characteristics of the anterior ethmoidal artery in ethmoid roof and endoscopic localization. *Skull Base* 19 : 311-317, 2009
- Cho JH, Citardi MJ, Lee WT, Sautter NB, Lee HM, Yoon JH : Comparison of frontal pneumatization patterns between Koreans and Caucasians 135 : 780-786, 2006
- Kubota K, Takeno S, Hirakawa K : Frontal recess anatomy Japanese subjects and its effect on the development of frontal sinusitis : computed tomography analysis. *J Otolaryngol Head Neck Surg* 44 : 21, 2015
- Lannoy-Penissou L, Schultz P, Rehm S, Atallah I, Veillon F, Debry C : The anterior ethmoidal artery : radio-anatomical comparison and its application in endonasal surgery. *Acta Otolaryngol* 127 : 618-622, 2007